



## Original Article

# Evaluation of polypropylene and polyglactin sutures in primary sphincteroplasty for the treatment of anal fistula in rats



Andrea Lima Conde<sup>a</sup>, Carlos Henrique Marques dos Santos<sup>id a,b,\*</sup>,  
Doroty Mesquita Dourado<sup>b</sup>, Otávio Augusto Vendas Tanus<sup>a</sup>, Isadora Ferreira de Souza<sup>b</sup>,  
Rochelle Leite Costa<sup>b</sup>, Fernanda Giuncanse<sup>b</sup>, Izabela Oliveira Costa<sup>b</sup>

<sup>a</sup> Universidade Federal de Mato Grosso do Sul, Hospital Universitário Maria Aparecida Pedrossian, Campo Grande, MS, Brazil

<sup>b</sup> Universidade Anhanguera-Uniderp, Campo Grande, MS, Brazil

### ARTICLE INFO

#### Article history:

Received 5 March 2019

Accepted 8 May 2019

Available online 31 May 2019

#### Keywords:

Rats

Rectal fistula

Polyglactin 910

Sphincteroplasty

Fistulotomy

### ABSTRACT

**Rationale:** Fistulotomy followed by primary sphincteroplasty is one of the therapeutic options in transsphincteric fistulae; however, it was not known which suture would present a better result.

**Objective:** To compare polypropylene and polyglactin sutures in primary sphincteroplasty in rats subjected to fistulotomy.

**Method:** Thirty Wistar rats were subjected to peritoneal anesthesia with ketamine and xylazine, followed by transfixation of the anal sphincter with steel thread, which remained for 30 days to develop the anal fistula. After this period, the steel thread was removed and four groups were formed: A – Control ( $n=5$ ), without treatment; B – Fistulotomy ( $n=5$ ), performed fistulotomy only; C – Polypropylene ( $n=10$ ), in which fistulotomy was performed followed by primary sphincteroplasty with polypropylene suture; D – Polyglactin ( $n=10$ ), in which fistulotomy was performed followed by primary sphincteroplasty with polyglactin suture; after 30 days the animals were anesthetized again and submitted to euthanasia by deepening the anesthetic plane to remove the specimens, analyzing fistula closure, muscle fiber distance, and inflammatory process.

**Results:** The fistula persisted in all animals of the control group and in none of the other groups; the distances between the muscle fibers were 1620  $\mu\text{m}$ , 4665  $\mu\text{m}$ , and 2520  $\mu\text{m}$ , respectively in Groups B, C, and D ( $p=0.067$ ); in relation to fibrosis, the means were 2.4, 2.8, and 3.6, respectively in Groups B, C, and D, showing greater fibrosis in the latter group ( $p=0.041$ ).

\* Corresponding author.

E-mail: [chenriquems@yahoo.com.br](mailto:chenriquems@yahoo.com.br) (C.H. Santos).

<https://doi.org/10.1016/j.jcol.2019.05.005>

2237-9363/© 2019 Sociedade Brasileira de Coloproctologia. Published by Elsevier Editora Ltda. This is an open access article under the CC BY-NC-ND license (<http://creativecommons.org/licenses/by-nc-nd/4.0/>).

**Conclusion:** There was no persistence of the fistula in any of the treated animals; there was no difference in the distance between the muscle fibers between the groups subjected to primary sphincteroplasty with polypropylene or polyglactin, or between these groups and the one treated only by fistulotomy. There was greater fibrosis in animals treated with primary sphincteroplasty with polyglactin.

© 2019 Sociedade Brasileira de Coloproctologia. Published by Elsevier Editora Ltda. This is an open access article under the CC BY-NC-ND license (<http://creativecommons.org/licenses/by-nc-nd/4.0/>).

## Avaliação dos fios de polipropileno e poliglactina na esfínteroplastia primária no tratamento da fistula anal em ratos

### R E S U M O

#### Palavras-chave:

Ratos

Fístula retal

Poliglactina 910

Esfínteroplastia

Fistulotomia

**Racional:** A fistulotomia seguida de esfínteroplastia primária é uma das opções terapêuticas nas fistulas transesfínterianas, porém, não se sabe ao certo qual fio poderia apresentar melhor resultado.

**Objetivo:** Comparar os fios de polipropileno e poliglactina na esfínteroplastia primária em ratos submetidos a fistulotomia.

**Método:** Utilizou-se 30 ratos Wistar, confeccionada fístula por transfixação do esfínter anal com fio de aço, que permaneceu por 30 dias. Após, o fio de aço foi removido e foram formados quatro grupos: A – Controle (n = 5), sem tratamento; B – Fistulotomia (n = 5), realizada fistulotomia apenas; C – Polipropileno (n = 10), em que foi realizada fistulotomia seguida por esfínteroplastia primária com fio de polipropileno; D – Poliglactina (n = 10), mesmo procedimento com fio de poliglactina; após 30 dias analisou-se o fechamento da fístula, afastamento dos cabos musculares e processo inflamatório.

**Resultados:** A fístula persistiu em todos animais do grupo controle e em nenhum dos demais grupos; dos grupos tratados a área de afastamento dos cabos musculares foi 1620  $\mu\text{m}$ , 4665  $\mu\text{m}$  e 2520  $\mu\text{m}$ , respectivamente nos Grupos B, C e D ( $p = 0,067$ ); em relação à fibrose as médias foram 2,4; 2,8 e 3,6; respectivamente nos Grupos B, C e D, demonstrando maior fibrose neste último grupo ( $p = 0,041$ ).

**Conclusão:** Não houve persistência da fístula em nenhum dos animais tratados, não houve diferença no afastamento dos cabos musculares entre os grupos submetidos a esfínteroplastia primária com polipropileno ou poliglactina, e nem destes com o grupo tratado apenas por fistulotomia. Houve maior fibrose nos animais tratados por esfínteroplastia primária com poliglactina.

© 2019 Sociedade Brasileira de Coloproctologia. Publicado por Elsevier Editora Ltda. Este é um artigo Open Access sob uma licença CC BY-NC-ND (<http://creativecommons.org/licenses/by-nc-nd/4.0/>).

## Introduction

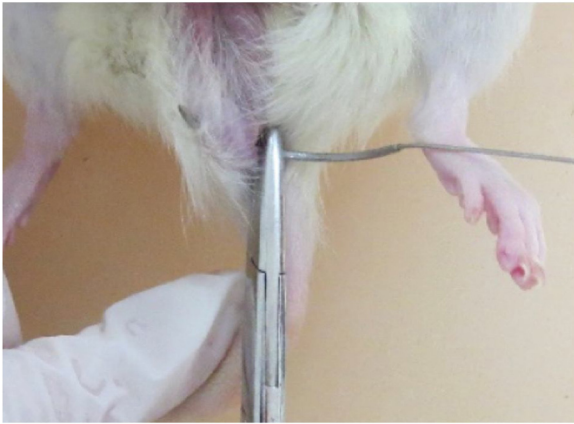The treatment of complex fistulas is challenging, especially since there is no consensus on the surgical technique to be applied in these cases, despite the great progress made in recent years and the emergence of new technologies such as VAAR, but which still lack the test of time to become a standardized procedure. Thus, old techniques are still adopted in medical practice and require more in-depth studies; one example is fistulotomy followed by primary sphincteroplasty.

Ratto et al.<sup>1</sup> recently published a systematic review comparing fistulotomy, fistulectomy, and primary sphincteroplasty in the treatment of anal fistulas. The authors observed that, despite the good results reported with all the techniques, there is a great variability in the methods used by the several authors; furthermore, the low quality of the publications is noteworthy, as most included a very low number of patients.

While the literature indicates that intersphincteric fistulas (for which fistulotomy is still considered an effective and safe option) are the most frequent,<sup>2</sup> transsphincteric fistulas are increasingly frequent in specialized outpatient clinics, and some epidemiological studies already indicate this as the most commonly observed fistula.<sup>3</sup>

Many techniques have been described for this situation. Some present low complication rates, but poor resolution, such as the use of a plug and fibrin glue,<sup>4</sup> while others are consensual, such as mucosal advancement flap, but may present with fecal incontinence and relapse in up to 20% of cases.<sup>5</sup> The most recently described technique, ligation of intersphincteric fistula tract (LIFT), has been widely used, as it cures approximately 70% of the cases with an incontinence rate close to zero.<sup>6</sup>

In the absence of an ideal technique, some authors have used fistulotomy followed by primary sphincteroplasty as the first line of treatment in transsphincteric fistulas,<sup>7</sup> with



**Fig. 1 – Transection of the anal sphincter with steel suture.**

results not inferior to other techniques for fecal incontinence and lower recurrence rates. However, information about the influence of the suture used to perform the sphincter reconstruction is lacking; therefore, the present study aimed to provide new information on this issue.

## Objective

To compare the use of polypropylene and polyglactin 910 sutures in primary post-fistulotomy sphincteroplasty for the treatment of anal fistula in rats.

## Methods

The project was approved by the Ethics Committee for Animal Experimentation of the Universidade Federal de Mato Grosso do Sul (870/2017).

Thirty male, adult, albino Wistar rats, weighing approximately 300 g each, were sourced from the Vivarium of the Universidade para o Desenvolvimento do Estado e da Região do Pantanal, where the experiment was carried out, observing all the ethical norms established by the Brazilian College of Animal Experimentation (Colégio Brasileiro de Experimentação Animal [COBEA]).

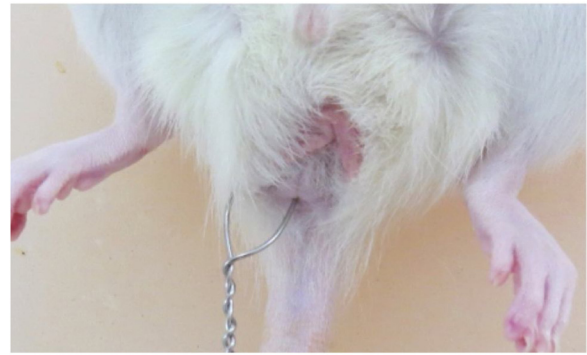The rats were anesthetized for the creation of anal fistulas. Anesthesia was performed through intraperitoneal administration of ketamine and xylazine, in the same syringe. The solution consisted of 2 mL of 10% ketamine and 1 mL of 2% xylazine. For each 100 g of body weight, 0.1 mL of the anesthetic solution was infused.

After anesthesia, the anal sphincter was transected with No. 5 steel suture (Aciflex<sup>®</sup>), introduced into the pectinate line and externalized 1 cm laterally to the right anal margin (Fig. 1). The suture was cut, twisted, and maintained for 30 days (Fig. 2).

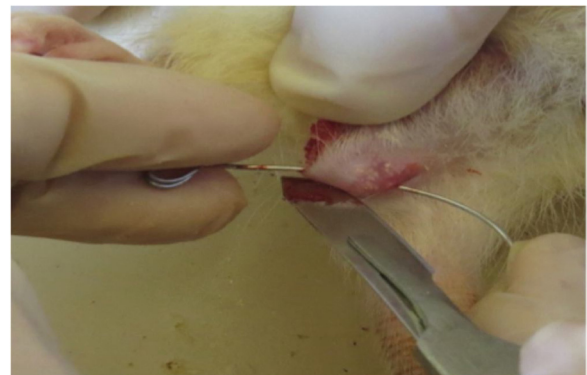After 30 days, the rats were subdivided into four groups:

Group A – Control: consisting of five rats, in which the steel suture was removed without therapeutic actions;

Group B – Fistulotomy: consisting of five rats, in which the steel suture was removed followed by fistulotomy and healing by second intention;



**Fig. 2 – Steel suture positioned to create a fistula.**



**Fig. 3 – Scalpel fistulotomy.**

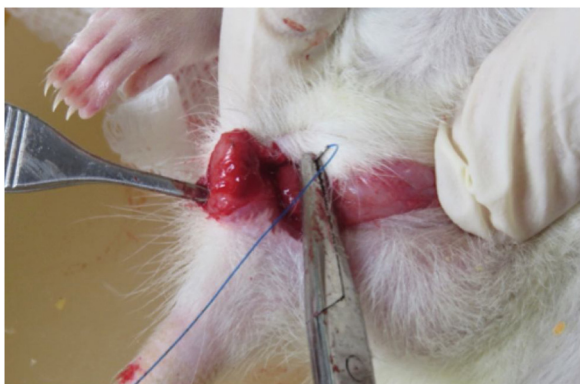
Group C – Polypropylene sphincteroplasty: consisting of ten rats, in which the steel suture was removed, and a fistulotomy and primary sphincteroplasty were performed with 4-0 polypropylene suture;

Group D – Polyglactin 910 sphincteroplasty: consisting of ten rats, in which the steel suture was removed, and a fistulotomy and primary sphincteroplasty were performed with 4-0 polyglactin 910 suture.

In the second surgical procedure, performed on the animals of Groups B, C, and D, after the previously described anesthesia, a metallic probe was introduced through the external orifice until its exteriorization through the internal orifice, followed by sectioning with a No. 22 scalpel, incising the skin and the anal sphincter over the entire length of the fistulous tract, followed by compression hemostasis with sterile gauze for 3 min (Fig. 3). Thereafter, curettage of the fistulous tract was performed, followed by fresh compression with gauze for three minutes.

In the animals of Groups C and D, after the fistulotomy, a sphincteroplasty was performed through a U-shaped suture, with the knot facing the internal region, and the skin was left open for healing by second intention (Fig. 4). In animals of Group C, a polypropylene suture was used, while in those in Group D, a polyglactin 910 suture was used; both were 4-0.

The second part of the study also lasted 30 days. After this period, a new intraperitoneal anesthesia was performed, followed by euthanasia and resection of a tissue cube of approximately 2 × 2 cm, involving the anal canal and the entire fistulous path to the skin containing the external orifice, in



**Fig. 4 – U-suture sphincteroplasty.**

order to contain the fistulous path its entire extension. Specimens were identified and fixed in 10% buffered formalin. Subsequently, the material was processed in increasing concentrations of alcohol, diaphonized in xylol, and placed in histological paraffin; 5- $\mu\text{m}$  cross sections were made with the aid of a rotary microtome (Microm HM320). The sections obtained were stained by the hematoxylin–eosin (HE) technique for qualitative histopathological analysis and Gomori trichrome (GT) to evaluate assess fibrosis sites, as this technique confers a green coloration to the collagen. The digital images of the HE- and GT-stained slides were captured in a Carl Zeiss photomicroscope coupled to a Samsung micro-camera connected to a computer with an image capture board (Figs. 5 and 6). The findings were read and interpreted by a

professional who was unaware the group to which each animal belonged.

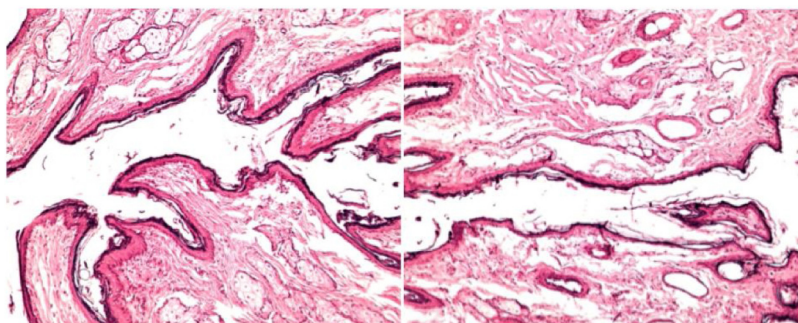
Histological analysis was performed considering the following aspects: persistence of the fistulous path, distance between muscle fibers, and local fibrosis.

To determine persistence or closure of the fistulous path, the persistence of the fistula was visualized by microscopy. It was considered as closed only when the entire route was closed; the persistence of even a short extension of the route was considered as persistence.

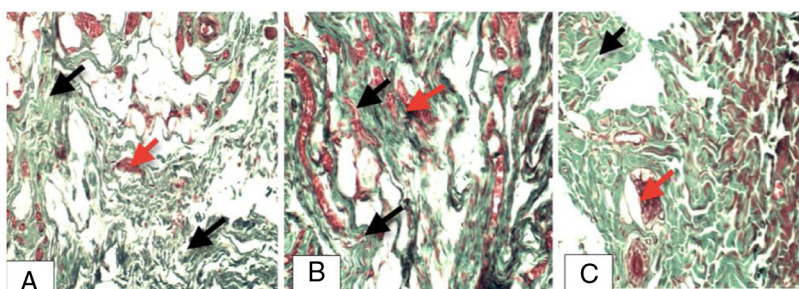
To determine the distance between muscle fibers, the muscle fibers in the region of the procedure were assessed by optical microscopy in a cross section of the anal canal; the perimeter was measured in micrometers ( $\mu\text{m}$ ), and the area between the ends of the sectioned sphincter in the fistulotomy group, as well as the area between the extremities of the sectioned and sutured sphincter in the polyglactin and polypropylene groups, were measured in square micrometers ( $\mu\text{m}^2$ ).

To determine the degree of fibrosis, a scoring system that took into account the local inflammatory process and its intensity was used, and the fibrosis was classified as follows: (1) first stage of granulation; (2) mild fibrosis, with cellularity of up to 25% in the analyzed area; (3) moderate fibrosis, with 25%–50% cellularity in the analyzed area; (4) intense fibrosis, with cellularity above 50% in the analyzed area.

The data analysis and the comparison between the experimental groups were performed through the one-way ANOVA test, followed by the Tukey post-test. For this purpose, the statistical program SigmaPlot v. 12.5 was used, considering a significance level of 5%.



**Fig. 5 – Photomicrograph of animal from the control group demonstrating the persistence of the fistulous path (HE 100 $\times$ ).**



**Fig. 6 – Photomicrography demonstrating the presence of fibrosis. (A) Animal from the fistulotomy group; (B) animal from the polypropylene group; (C) animal from the polyglactin group; black arrows, collagen fibers and red arrows, neoformation of blood vessels (Gomori trichrome – GT, 20 $\times$ ).**

**Table 1 – Assessment of the persistence of the fistulous path in the animals studied.**

Animal	Experimental group			
	Control	Fistulotomy	Polypropylene	Polyglactin
1	Yes	No	No	No
2	Yes	No	No	No
3	Yes	No	No	No
4	Yes	No	No	No
5	Yes	No	No	No
6	–	–	No	No
7	–	–	No	No
8	–	–	No	No
9	–	–	No	No
10	–	–	No	No
%	100.0	0.0	0.0	0.0
Number	5	0	0	0

The results are presented as individual values or relative frequency (%) and absolute frequency (number).

**Table 2 – Evaluation of the anal fistula area ( $\mu\text{m}^2$ ), perimeter of the anal fistula ( $\mu\text{m}$ ), and degree of fibrosis in the animals of the control group.**

Animal	Control group		
	Area of anal fistula	Perimeter of anal fistula	Degree of fibrosis
1	8836	567	1
2	11,405	595	2
3	37,730	1111	2
4	16,931	1195	2
5	29,067	1407	1
6	–	–	–
7	–	–	–
8	–	–	–
9	–	–	–
10	–	–	–
Mean	20,793.80	975.00	1.60
SEM	5483.34	167.99	0.24

The results are presented as individual values or mean  $\pm$  standard error of the mean (SEM).

## Results

Fistula persistence was observed in all the animals in the control group, while no fistulous path was observed in any of the animals in the treated groups (Table 1).

Table 2 presents the information observed in the control group to serve as a parameter of comparison with the results of the other groups.

Regarding distance between muscle fibers, in the fistulotomy group, the mean was 1620  $\mu\text{m}$  vs. 4665.5  $\mu\text{m}$  in the polypropylene group and 2520  $\mu\text{m}$  in the polyglactin group ( $p=0.067$ , Table 3).

Regarding the degree of fibrosis caused by the different treatments, a mean of 2.4 was observed in the control group, vs. 2.8 in the polypropylene group and 3.6 in the polyglactin group; therefore, fibrosis was higher in the latter ( $p=0.041$ ; Table 4).

**Table 3 – Measurements (in  $\mu\text{m}$ ) of distance between the muscle fibers in the animals studied.**

Animal	Experimental group			p-value
	Fistulotomy	Polypropylene	Polyglactin	
1	966	7638	1626	
2	1007	2259	2085	
3	2020	1136	1856	
4	2134	794	2264	
5	1973	385	1262	
6	–	2388	4931	
7	–	8269	2233	
8	–	8501	565	
9	–	6783	2462	
10	–	8502	5917	
Mean	1620.00a	4665.50a	2520.10a	0.067
SEM	260.03	1117.94	520.02	

The results are presented as individual values or mean  $\pm$  standard error of the mean (SEM). p-value in the one-way ANOVA test. Equal letters in the rows indicate that there was no significant difference between the experimental groups (Tukey's post-test,  $p > 0.05$ ).

**Table 4 – Degree of fibrosis caused by the different treatments in the animals of each experimental group.**

Animal	Experimental group			p-value
	Fistulotomy	Polypropylene	Polyglactin	
1	2	3	3	
2	2	2	4	
3	4	2	4	
4	1	1	4	
5	3	4	3	
6	–	3	4	
7	–	3	4	
8	–	4	3	
9	–	4	3	
10	–	2	4	
Mean	2.40a	2.80a	3.60b	0.041
SEM	0.51	0.33	0.16	

The results are presented as individual values or mean  $\pm$  standard error of the mean (SEM). p-value in the one-way ANOVA test. Different letters in the row indicate a significant difference between the experimental groups (Tukey's post-test,  $p < 0.05$ ).

## Discussion

The present results demonstrate what was initially expected based on data from the medical literature, i.e., that untreated fistulas tend to remain active over time, and that fistulotomy associated with curettage of the fistulous path is effective in treating the disease,<sup>8</sup> as well as the association with sphincteroplasty.<sup>1</sup> It was not possible to assess fecal continence or relapse, since this experimental model does not lend itself to these purposes and these were not objectives of the study.

In transsphincteric fistulas, curettage fistulotomy appears to have the same healing capacity as in intersphincteric fistulas, but the rate of fecal incontinence is substantially greater, since the larger section of muscle fibers, especially of

the external sphincter, results in progressive local hypotonia.<sup>9</sup> Thus, the idea of adding primary sphincteroplasty to ensure efficacy in healing the fistulous path and assuring fecal continence by preserving the sphincter structure is logical.

The literature presents widely variable results of primary sphincteroplasty regarding incontinence. The first consistent data in the literature on the technique are from 1985, with the study by Parkash et al.<sup>10</sup> reporting 120 cases followed-up for 11 years, indicating primary cure of 83% of patients and only three cases of relapse. Subsequent publications have shown a similar cure rate, above 80%, which may be considered satisfactory for transsphincteric fistulas.<sup>1,2,5,9</sup> This variation in the results of the technique may be due to many factors, such as characteristics of the fistula, clinical conditions of the patients, and material used. This last factor was the focus of the present study, which analyzed whether the suture material could influence the results.

Since most publications on the subject are in humans, fistula healing, recurrence, and incontinence are evaluated; however, in cases where the latter is observed, it is not possible to verify with certainty whether the total or partial dehiscence could be responsible for this failure. A shorter distance between muscle fibers was expected in the sphincteroplasty groups when compared with the group where only the fistulotomy was performed; however, this was not verified in the analysis of the results, i.e., with or without the approximation of the muscle fibers, the distance between them was not modified, allowing the inference that, if it were possible to evaluate fecal continence, the indexes would also be similar. There are no experimental studies in the literature with a similar method to direct comparisons; sphincteroplasty has not been studied experimentally. Therefore, it is only possible to compare the present results with studies that have evaluated different materials in other types of sutures. Jordan et al.<sup>11</sup> observed that there were no significant differences between polyglactin and polypropylene in tenorrhaphy in rats, although polypropylene presented greater plasticity. In the present research, no differences were observed between these materials in the suture quality, since the difference in the distance between the muscle fibers was not statistically significant.

MacFarlane et al.<sup>12</sup> also compared polypropylene and polyglactin in the treatment of carpal tunnel syndrome and did not observe differences between the two materials regarding resistance and complications, recommending that surgeons make the choice based on personal preference.

In anal sphincter reconstruction in cases of obstetric trauma, while the authors did not compare the suture material, Simsec et al.<sup>13</sup> observed improvement in fecal continence scores, which leads the present authors to understand that there was no dehiscence in the sutures or, at least that if they occurred, there was no clinical repercussion. This represents a large gap to be filled by experimental studies. Clinical studies of sphincter reconstruction evaluate continence through clinical scores or anorectal manometry, but do not evaluate suture quality, which was the goal of the present research. If the distance between the muscle fibers after fistulotomy is not altered by sphincteroplasty, there would be no reason for the latter procedure to be performed. However,

Ratto et al.<sup>2</sup> evaluated post-fistulotomy primary sphincteroplasty using three-dimensional ultrasonography and observed that patients who evolved with fecal incontinence presented greater distance between muscle fibers.

Another aspect that should be analyzed in the treatment of anal fistulas is fibrosis, because although sphincteroplasty may promote anatomical reconstruction of the sphincter, if it is accompanied by a large fibrosis, functional results may be impaired, hindering local sensitivity, relaxation, and contraction. Regarding this subject, experimental studies specifically of the sphincter apparatus are scarce in the literature. Studying scleroderma, a disease known to lead to fibrosis even in the anal sphincter, Pinto et al.<sup>14</sup> observed that the higher the degree of fibrosis in the sphincter, the greater the degree of fecal incontinence, demonstrating a direct correlation between the two factors. In the present research, it was observed that the animals treated by fistulotomy followed by sphincteroplasty with polyglactin suture had a higher degree of local fibrosis, which in theory would lead to worse sphincter function. Polyglactin, because it is absorbable and multifilamentous, induces a greater inflammatory reaction than polypropylene, as it is a monofilament material.<sup>15,16</sup> However, a greater degree of fibrosis was expected that in the group submitted only to fistulotomy and curettage, since the wound left for healing by second intention would have a greater inflammatory response and consequently greater fibrosis,<sup>17</sup> which did not occur; in that group, the fibrosis observed was equivalent to that in polypropylene-treated animals and significantly lower than in the polyglactin group.

The present study cannot be considered as conclusive and does not allow the establishment of any new conduct regarding complex anal fistulas. However, it provided intriguing results that should lead to further research in order to establish the real role of sphincter reconstruction and the material used. If there is no anatomical difference in the sectioned sphincter after a few days of treatment with or without reconstruction, there may be no advantage in performing it. Regarding the material, it was demonstrated that the multifilament suture causes greater local fibrosis than the monofilament option, which is often undesirable when the goal is to preserve sphincter function. Thus, considering the higher incidence of fibrosis in animals treated with primary sphincteroplasty with polyglactin than with simple fistulotomy without reconstruction, and considering the lack of difference in the distance between the muscle fibers, there appears to be no reason for reconstruction with this material.

The present research brings many more doubts than conclusions, which is very productive from the scientific standpoint, as it questions behaviors accepted as definitive and indicates the need for new research in order to clarify the questions presented.

---

## Conclusion

No fistula persistence was observed in any of the animals that underwent fistulotomy; no difference in the distance between the muscle fibers was observed between the animals treated only by fistulotomy and those in which sphincteroplasty was added, either with polypropylene or polyglactin suture. In the

animals in which polyglactin was used, a greater incidence of local fibrosis was observed.

### Conflicts of interest

The authors declare no conflicts of interest.

### REFERENCES

- Ratto C, Litta F, Donisi L, Parello A. Fistulotomy or fistulectomy and primary sphincteroplasty for anal fistula (FIPS): a systematic review. *Tech Coloproctol*. 2015;19:391.
- Ratto C, Litta F, Parello A, Zaccone G, Donisi L, De Simone V. Fistulotomy with end-to-end primary sphincteroplasty for anal fistula: results from a prospective study. *Dis Colon Rectum*. 2013;56:226–33.
- Soliman F, Sturgeon G, Hargest R. Revisiting an ancient treatment for transsphincteric fistula-in-ano ‘There is nothing new under the sun’ *Ecclesiastes 1v9*. *J R Soc Med*. 2015;108:482–9.
- Limura E, Giordano P. Modern management of anal fistula. *World J Gastroenterol*. 2015;21:12–20.
- Balciscueta Z, Uribe N, Balciscueta I, Andreu-Ballester JC, García-Granero E. Rectal advancement flap for the treatment of complex cryptoglandular anal fistulas: a systematic review and meta-analysis. *Int J Colorectal Dis*. 2017;32:599–609.
- Wen K, Gu YF, Sun XL, Wang XP, Yan S, He ZQ, et al. Long-term outcomes of ligation of intersphincteric fistula tract for complex fistula-in-ano: modified operative procedure experience. *Arq Bras Cir Dig*. 2018;31:e1404.
- Seyfried S, Bussen D, Joos A, Galata C, Weiss C, Herold A. Fistulectomy with primary sphincter reconstruction. *Int J Colorectal Dis*. 2018;911–918.
- Wang Q, He Y, Shen J. The best surgical strategy for anal fistula based on a network meta-analysis. *Oncotarget*. 2017;8:99075–84.
- Mascagni D, Pironi D, Pontone S, Tonda M, Eberspacher C, Panarese A, et al. Total fistulectomy sphincteroplasty and closure of the residual cavity for trans-sphincteric perianal fistula in the elderly patient. *Aging Clin Exp Res*. 2017;29 Suppl. 1:101–8.
- Parkash S, Lakshmiratan V, Gajendran V. Fistula-in-ano: treatment by fistulectomy primary closure and reconstitution. *Aust N Z J Surg*. 1985;55:23–7.
- Jordan MC, Boelch S, Jansen H, Meffert RH, Hoelscher-Doht S. Does plastic suture deformation induce gapping after tendon repair? A biomechanical comparison of different suture materials. *J Biomech*. 2016;49:2607–12.
- MacFarlane RJ, Donnelly TD, Khan Y, Morapudi S, Waseem M, Fischer J. Clinical outcome and wound healing following carpal tunnel decompression: a comparison of two common suture materials. *Biomed Res Int*. 2014;2014:270137.
- Şimsek A, Ateş M, Dirican A, Özgör D. A surgical technique for secondary repair of obstetric anal sphincter injuries; sphinctero-vagino-perineoplasty. *Turk J Obstet Gynecol*. 2018;15:249–53.
- Pinto RA, Corrêa Neto IJF, Nahas SC, Bustamante Lopes LA, Sobrado Júnior CW, Cecconello I. Functional and anatomical analysis of the anorectum of female scleroderma patients at a center for pelvic floor disorders. *Arq Gastroenterol*. 2018;55 Suppl. 1:47–51.
- Selvi F, Cakarar S, Can T, Kirli Topcu Sİ, Palancioglu A, Keskin B, et al. Effects of different suture materials on tissue healing. *J Istanbul Univ Fac Dent*. 2016;50:35–42.
- Galvão MO, Santos CHM, Falcão GR. Evaluation of the inflammatory response induced by different materials in the treatment of perianal fistulas: experimental study in rats. *J Coloproctol*. 2016;36:16–20.
- Murad-Regadas SM, Regadas Filho FSP, Holanda EC, Veras LB, Vilarinho ADS, Lopes MS. Can three-dimensional anorectal ultrasonography be included as a diagnostic tool for the assessment of anal fistula before and after surgical treatment? *Arq Gastroenterol*. 2018;55 Suppl. 1:18–24.