




## Case Report

# Other causes of intestinal obstruction actino-mycetoma – a case report and literature review



Jessica Correa Marín <sup>a,\*</sup>, Juan David Urrea Llano<sup>b</sup>, Alden Pool Gomez<sup>c</sup>

<sup>a</sup> General Surgery, Universidad Del Valle, Cali, Colombia

<sup>b</sup> Orthopedic Surgery, Universidad Del Valle, Cali, Colombia

<sup>c</sup> Gastrointestinal Surgery, Universidad Del Valle, Cali, Colombia

## ARTICLE INFO

## Article history:

Received 6 February 2019

Accepted 8 May 2019

Available online 6 June 2019

## Keywords:

Intestinal actinomycosis  
Intestinal obstruction  
colon and laparotomy

## ABSTRACT

**Introduction:** Actinomycosis is a rare infectious disease that affects abdominal organs and simulates oncological disease, hardly ever presents itself as a cause of intestinal obstruction. **Symptoms:** A 43 years old, male patient with two months of left abdominal pain associated to a growth and an 8 kg weight loss, no fever or bowel habit disruption.

**Interventions:** A colonoscopy and an abdominal scanography.

**Results:** A solid heterogeneous 7 × 3.8 cm mass localized in the splenic flexure of the colon with infiltration of its walls and its surrounding fat. Colon cancer was considered as the first diagnostic possibility. During hospitalization, the patient was taken to an emergency exploratory laparotomy, due to an acute abdominal pain with bowel obstruction symptoms. **Histopathological diagnosis:** Actinomycetoma. Conjoint continuous monitoring with the infectious disease attending, abdominal US and observation did not show new growths. Weight gain and progressive return to daily life was obtained within 8 weeks.

**Conclusion:** In low income countries, intestinal actinomycosis should be considered in the differential diagnosis of abdominal masses and chronic inflammatory processes, patient prognosis with proper management is excellent.

© 2019 Sociedade Brasileira de Coloproctologia. Published by Elsevier Editora Ltda. This is an open access article under the CC BY-NC-ND license (<http://creativecommons.org/licenses/by-nc-nd/4.0/>).

## Outras causas de obstrução intestinal por actinomicetoma - relato de caso e revisão da literatura

## RESUMO

**Introdução:** A actinomicose é uma doença infecciosa rara que acomete órgãos abdominais, simula doença oncológica e dificilmente causa de obstrução intestinal.

**Sintomas:** Paciente do sexo masculino, 43 anos, com quadro de dor abdominal esquerda por dois meses, associado ao surgimento de massa e perda de peso de 8 kg, sem febre ou alterações dos hábitos intestinais.

## Palavras-chave:

Actinomicose intestinal  
Obstrução intestinal

\* Corresponding author.

<https://doi.org/10.1016/j.jcol.2019.05.004>

2237-9363/© 2019 Sociedade Brasileira de Coloproctologia. Published by Elsevier Editora Ltda. This is an open access article under the CC BY-NC-ND license (<http://creativecommons.org/licenses/by-nc-nd/4.0/>).

*Intervenções:* Colonoscopia e uma tomografia computadorizada abdominal.

*Resultados:* Observou-se massa sólida heterogênea de 7 × 3,8 cm localizada na flexão esplênica do cólon, com infiltração de suas paredes e gordura adjacente. Câncer de cólon foi a primeira possibilidade diagnóstica considerada. Durante a internação, o paciente foi submetido a uma laparotomia exploradora de emergência, devido a uma dor abdominal aguda com sintomas de obstrução intestinal.

*Diagnóstico histopatológico:* Actinomicetoma. Monitoramento contínuo em conjunto com o tratamento da infecção, ultrassom abdominal e observação; não foram observados novos crescimentos. Ganho de peso e retorno progressivo à vida diária foram observados por oito semanas.

*Conclusão:* Em países de baixa renda, a actinomicose intestinal deve ser considerada no diagnóstico diferencial de massas abdominais e processos inflamatórios crônicos; com manejo adequado, o prognóstico é excelente.

© 2019 Sociedade Brasileira de Coloproctologia. Publicado por Elsevier Editora Ltda. Este é um artigo Open Access sob uma licença CC BY-NC-ND (<http://creativecommons.org/licenses/by-nc-nd/4.0/>).

## Introduction

Actinomycosis is a rare infectious disease caused by an anaerobic gram positive germ, rarely affects the colon and to a lesser extent the left colon.<sup>1</sup>

This germ is not very virulent and primarily affects cervicofacial mucosa (50%), abdominal (20%) and thoracic (15%) being the most affected immunosuppressed population, low socioeconomic levels or patients in developing countries. It has been linked to some risk factors like diabetes, transplant patients or history of trauma or instrumentation on the affected site. Its ability to produce disease is related to mucosa lesions.<sup>2</sup>

The most affected sites are cecum and transverse colon small bowel involvement, has not been reported.

The initial diagnosis of this disease is not easy and can be confused repeatedly with chronic inflammatory processes, diverticular disease, amebomas, Crohn's disease, inflammatory bowel disease or neoplastic diseases among others.<sup>2</sup>

Actinomyces isolation is the gold standard for diagnosis but has some limitations for the culture: it requires fresh samples, such as swabs or soft tissue, which ideally, must be transported in special containers or an anaerobic culture medium, and it has to be processed immediately, it has a high false negative value, as high as 76% of cases. Visualization of "sulfur granules" observed in the histopathological study is considered as a pathognomonic finding but its only visible in 50% of cases.<sup>3,4</sup>

The diagnosis before surgery is performed in less than 10% of patients due to the low index of suspicion, unusual presentations and difficulty in growing Actinomyces.

## Case description

A 43 years old male builder from the municipality of Cali was admitted with a left abdominal pain associated to a growth and an 8 kg weight loss without bowel symptoms or bleeding. He mentioned an alcohol consumption of 90 g weekly for the last 23 years.

The patient had a positive physical examination with a left flank abdominal mass extending to left costal margin, a digital rectal examination was performed with no abnormal findings, a colonoscopy was performed, and the radiologist reported a normal cavity up until the splenic flexure angle that leaves no progress, no endoluminal lesions are displayed in evaluated image.

Abdominal CT scan: A 7 × 3.8 cm heterogeneous mass was localized in the splenic flexure of the colon, which infiltrates its walls and its surrounding fat with no signs of obstruction.

Chest radiograph: Without abnormal changes.

At the time the working diagnosis was a tumor of the left colon, direct visualization and biopsy of the mass was unobtainable through repeated colonoscopies, CEA was requested but unavailable in the hospital at the time.

Meanwhile the patient continued with abdominal pain, during hospitalization the patient developed signs and symptoms of bowel obstruction; an emergency exploratory laparotomy with a transverse extension to the left flank was performed. A left hemicolectomy, partial resection of left diaphragm with oncologic margins was performed and a closed left thoracostomy was placed.

Surgical findings: ascites, a 20 × 22 cm infiltrating mass in the splenic flexure and sigmoid colon, which compromised left diaphragm and abdominal wall associated to enlarged lymph size of the meso.

A good postoperative evolution was observed, and the chest tube was removed 3 days postoperatively and the patient was discharged 5 days after surgery.

The patient underwent a monthly ambulatory follow up with clinical surveillance up until a final pathology report was obtained, it indicated negative for malignancy, with positive findings of actinomycetoma. Conjoint continuous monitoring with the infectious disease attending with abdominal US and observation did not show new masses, the prescription of oral antibiotics was not required.

Weight gain and progressive return to daily life was obtained within 8 weeks of discharge.

## Schedule

Table 1.

**Table 1 – Schedule.**

Date	Intervention
December 6, 2014	Admitted to emergency room
Decembre 9, 2014	Colonoscopy
Decembre 10, 2014	CT abdominal scan
Decembre 14, 2014	Surgery
Decembre 19, 2014	Discharge of hospital

## Discussion

The anaerobic germ *Actinomyces* it is known to be part of the normal flora that inhabits the gastrointestinal, respiratory and female genital tract. It manages to generate disease when the integrity of the mucosa is compromised either by trauma or surgery that triggers mucosa infiltration. The pathophysiology of this process is poorly understood, but there are factors that predispose the infiltration such as immunosuppression, foreign body and intestinal perforation among others. However, there are several reports in which a determined predisposing factor has not been identified, in our case, a clear predisposing factor was not identified either.<sup>1,2</sup>

The clinical presentation of actinomycosis is characterized by chronic and insidious inflammatory conditions, this disease include nonspecific abdominal symptoms such as pain and cramping. There is always the complaint of a slow growing mass with constitutional symptoms with alteration of bowel habits it could even present itself as a bowel obstruction, directly associated to the size of the abdominal mass.

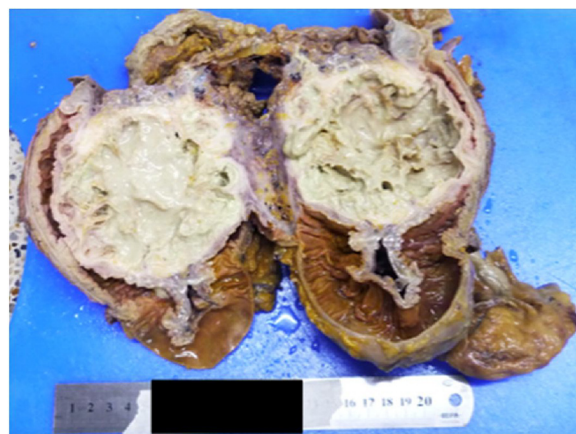
The abdominal mass detected clinically or radiologically is a common finding that mimics other abdominal conditions. Radiological assessments are often nonspecific. Abdominal actinomycosis is rarely presented as an abdominal abscess with or without abdominal or perianal discharging sinuses, such abdominal collections may develop an acute surgical abdomen which may warrant a laparotomy.<sup>3</sup>

The most common laboratory findings are anemia, leukocytosis and elevated inflammatory response markers. The right side and ileocecal valve are the more commonly affected portions of the bowel. It is not frequent the affection of the left side of the colon, but it has been reported.

Computed tomography (CT) is an applicable method for detecting a mass and to explore the surrounding area but is not diagnostic for actinomycosis. Sampling or biopsies of such injury could be obtained, to complete the diagnostic procedure although it does not have good performance for this entity.<sup>4</sup>

The effectiveness of colonoscopy for diagnosing the extraluminal actinomycosis affection is low but is generally used to exclude inflammatory or neoplastic entities. However, in the presence of a mass in the intestinal lumen, the histopathological evaluation of a specimen and cultures of the lesion are mandatory to obtain an accurate diagnosis.

The gold standard for the diagnosis of this entity is isolation in a microbiological culture, which is, however, rarely positive in the clinical setting. Acquired colonies resemble the molar tooth and it takes up to a week or so to obtain growth incubating the samples in anaerobic environment. *Actinomyces* granules regularly show positive reaction with periodic acid-Schiff test and dye Grocott, but Kossa reaction is negative.

**Fig. 1 – Surgical specimen.**

However, there are some limitations for carrying out the *Actinomyces* cultures, such as, the sample storage, which must be transported in special containers for anaerobic pathogens and it must be processed immediately, even then it could have a negative result in 76% of the cases. There is a pathognomonic finding which are, the sulfur granules like visualization, which unfortunately can only be identify in 50% of cases.<sup>5</sup>

Regarding our case, it was not possible to obtain a pre-operative diagnosis as usually happens due to the clinical presentation of the patient; an oncological disease was the initial working diagnosis. The colonoscopy showed an extraluminal mass located on the left splenic flexure process of the colon.

With the initial diagnosis in mind a karnofsky index of 90%, a potentially resectable oncological disease and a bowel obstruction with an acute surgical abdomen an exploratory laparotomy was performed. An intraoperative decision to perform an oncological resection with curative intent was adopted. Actinomycosis is a great simulator, mimicking abdominal tumor pathology; it leads the surgeon to perform major surgeries with probably large unnecessary resections. The medical management has been described with penicillin's, macrolides and tetracyclines for a period of 4 weeks, in this case due to the size and the mechanical complications a surgical resection was necessary, as prescribed by the infectious disease attendant, who continue to perform clinical follow-up 3 months and an abdominal ultrasound every 6 months, no signs of relapse has been recorded and the patient gained 8 kg of body mass with normal bowel habits.

As always unclear abdominal masses have to be tackled with a sequential approach including blood work, imaging and clinical presentation to obtain a diagnosis before surgery if possible, the pathological study of the lesion could guide and rule out other much more common diseases. In low income countries intestinal actinomycosis is an entity to be considered in the differential diagnosis of abdominal masses and chronic inflammatory processes, with proper management this entity has an excellent prognosis (Fig. 1).

## Conflicts of interest

The authors declare no conflicts of interest.

## REFERENCES

1. Farhad Z, Masoudreza S. Clinical, endoscopic, and histopathological aspects of sigmoid actinomycosis; a case report and literature review. *Middle East J Dig Dis.* 2015;7:41-4.
2. Branka F, Nikola M, Nikoli G. Primary actinomycosis of the anterior abdominal wall: case report and review of the literature clinical and hospital center, 'Bezanijska Kosa' Belgrade, serbia and montenegro. *J Gastroenterol Hepatol.* 2005;20:517-20.
3. Citron JR, Del Pino A, Duarte B, Wood D. Abdominal actinomycosis. *Dis Colon Rectum.* 1996;39:10-8.
4. Harris LA, DeCosse JJ, Dannenberg A. Abdominal actinomycosis: evaluation by computed tomography. *Am J Gastroenterol.* 1989;84:198-200.
5. Riegel P. Bacteriological and clinical aspects of corynebacterium. *Ann Biol Clin.* 1998;56:285-96.