



## Original Article

# Effects of *Cupressus sempervirens* extract on the healing of acetic acid-induced ulcerative colitis in rat



Masood Sepehrimanesh<sup>a</sup>, Nastaran Samimi<sup>b,c</sup>, Omid Koohi-Hosseinabadi<sup>d</sup>, Maral Mokhtari<sup>e</sup>, Saeed Amiri-Zadeh<sup>f</sup>, Mojtaba Farjam<sup>b,\*</sup>

<sup>a</sup> Gastrointestinal and Liver Diseases Research Center, Guilan University of Medical Sciences, Rasht, Iran

<sup>b</sup> Noncommunicable Diseases Research Center, Fasa University of Medical Sciences, Fasa, Iran

<sup>c</sup> Student Research Committee, Fasa University of Medical Sciences, Fasa, Iran

<sup>d</sup> Center of Comparative and Experimental Medicine, Shiraz University of Medical Science, Shiraz, Iran

<sup>e</sup> Department of Pathology, School of Medicine, Shiraz University of Medical Sciences, Shiraz, Iran

<sup>f</sup> Gastroenterohepatology Research Center, Shiraz University of Medical Sciences, Shiraz, Iran

### ARTICLE INFO

#### Article history:

Received 10 April 2018

Accepted 8 July 2018

Available online 7 August 2018

#### Keywords:

*Cupressus sempervirens*

Ulcerative colitis

Histopathology

Antioxidant

Healing

### ABSTRACT

Ulcerative colitis is a chronic inflammatory condition of the colon with an unknown etiology. In this study, we aimed to evaluate the therapeutic effects of *Cupressus sempervirens* extract on the healing of acetic acid-induced ulcerative colitis in rat. Fifty-five male rats divided into five equal treatment groups were used for this study and received the following treatments: Group 1, 250 mg/kg asacol; Group 2, 1 ml gel base (carboxymethyl cellulose); Group 3, 0.5% gel form of *C. sempervirens* extract; Group 4, 1% gel form of *C. sempervirens* extract, and; Group 5, considered as negative control and received 1 ml of normal saline. Body weight changes, histopathological and antioxidant changes in the colon tissue were evaluated. Significant weight gain was observed in rats that received 1% gel extract of *C. sempervirens*. Significant superoxide dismutase activity was also detected in 0.5 and 1% gel extract groups compared to *C. sempervirens* extract, Asacol and in 1% gel extract groups compared to the gel base group. Furthermore, both gel extract groups had significant lower total antioxidant capacity compared to Asacol group. Several histopathological lesions including inflammation, ulceration, crypt disarray, and goblet cell depletion were detected in the different groups, however, the mean rank of pathological changes showed no significant difference among the five groups. In summary, our results showed that hydroalcoholic extracts of *C. sempervirens* leaves produces healing effects in acetic acid induced ulcerative colitis.

© 2018 Sociedade Brasileira de Coloproctologia. Published by Elsevier Editora Ltda. This is an open access article under the CC BY-NC-ND license (<http://creativecommons.org/licenses/by-nc-nd/4.0/>).

\* Corresponding author.

E-mails: [Farjam.md@gmail.com](mailto:Farjam.md@gmail.com), [Mfarjam@fums.ac.ir](mailto:Mfarjam@fums.ac.ir) (M. Farjam).

<https://doi.org/10.1016/j.jcol.2018.07.002>

2237-9363/© 2018 Sociedade Brasileira de Coloproctologia. Published by Elsevier Editora Ltda. This is an open access article under the CC BY-NC-ND license (<http://creativecommons.org/licenses/by-nc-nd/4.0/>).

## Efeitos do extrato de *Cupressus sempervirens* na cicatrização de colite ulcerativa induzida por ácido acético em ratos

### R E S U M O

**Palavras-chave:**  
*Cupressus sempervirens*  
Colite ulcerativa  
Histopatologia  
Antioxidante  
Cicatrização

A colite ulcerativa é uma doença inflamatória crônica do cólon com uma etiologia desconhecida. O objetivo deste estudo foi avaliar os efeitos terapêuticos do extrato de *Cupressus sempervirens* na cicatrização de colite ulcerativa induzida por ácido acético em ratos. Cinquenta e cinco ratos machos divididos em cinco grupos de tratamento iguais foram utilizados para este estudo e receberam os seguintes tratamentos: Grupo 1: 250 mg/kg de asacol; Grupo 2: 1 mL de gel base (carboximetilcelulose); Grupo 3: extrato de *C. sempervirens* a 0,5% em gel; Grupo 4: extrato de *C. sempervirens* a 1% em gel e; Grupo 5: considerado controle negativo que recebeu 1 mL de solução salina normal. Alterações no peso corporal, alterações histopatológicas e antioxidantes no tecido do cólon foram avaliadas. Ganho de peso significativo foi observado em ratos que receberam extrato em gel de *C. sempervirens* a 1%. Atividade significativa de superóxido dismutase também foi detectada em grupos de extrato em gel de 0,5 e 1% em comparação com o extrato de *C. sempervirens*, Asacol e em grupos de extrato em gel a 1% em comparação com o grupo base de gel. Além disso, ambos os grupos de extrato em gel apresentaram capacidade antioxidante total significativamente menor em comparação ao grupo Asacol. Várias lesões histopatológicas, incluindo inflamação, ulceração, desarranjo da cripta e depleção de células caliciformes foram detectadas nos diferentes grupos; no entanto, a classificação média de alterações patológicas não apresentou diferença significativa entre os cinco grupos. Em resumo, nossos resultados mostraram que extratos hidroalcoólicos de folhas de *C. sempervirens* produzem efeitos cicatrizantes em colite ulcerativa induzida por ácido acético.

© 2018 Sociedade Brasileira de Coloproctologia. Publicado por Elsevier Editora Ltda. Este é um artigo Open Access sob uma licença CC BY-NC-ND (<http://creativecommons.org/licenses/by-nc-nd/4.0/>).

## Introduction

Ulcerative colitis (UC) is a type of inflammatory bowel disease (IBD) characterized by continuous mucosal inflammation and ulceration.<sup>1</sup> The etiology of UC is not completely known but there are several possible causes such as immune dysfunction, genetic susceptibility, invasion of the intestinal microbiota and alteration of the autophagy pathway.<sup>2-4</sup> Despite the underlying causes, UC treatment and healing of its related ulcers are significant medical issues. These include using 5-amino salicylic acid drugs, immunosuppressive agents, iron supplements, bacterial recolonization, surgical approaches, and alternative treatments.<sup>5</sup> Nowadays, the use of medicinal plants and their derivatives as alternative treatment agents for many diseases such as UC have been studied by physicians and scientists. However, this requires previous confirmed results in animal models.

*Cupressus sempervirens*, also called Mediterranean cypress, is a herb belonging to the Cupressaceae family. It is found in the northern half of the planet, in places such as the northwest and central regions of the United States, northwest Africa, the eastern Mediterranean, Iran, Turkey, southern China, and north of Wintam.<sup>6</sup> The leaves and fruits of this plant are rich in flavonoids and tannins but lacking in alkaloids and low levels of saponin. In traditional medicine, the plant is used as a diuretic, gastrointestinal stimulants, and disinfectants for the treatment of common cold and wound healing.<sup>7</sup> In 2013, Asgary and his colleagues reported high antioxidant activity

for the essential oil produced from the branches and fruits of *C. sempervirens*.<sup>8</sup>

Due to the non-availability of previous studies on the antioxidant and healing properties of this plant in UC, the study aimed to evaluate the histopathological and antioxidant changes in the colon tissue of rat with experimental-induced UC after *C. sempervirens* extract consumption.

## Materials and methods

### Plant material

The leaves of *C. sempervirens* were collected from Shiraz, Fars province, Iran (GPS coordinates: Latitude: 29.591768 and Longitude: 52.583698) during the spring season (May 2017). To prepare the hydroalcoholic extract, the leaves were dried away from direct sunlight at an ambient temperature of 25–30°C. Then, 1 kg of powdered plant was transferred into ratio 80:20 ethanol:water solution and extracted using percolation method for 72 h. The gel form of the extract (37.7%, w/w) were obtained after filtration and evaporation under reduced pressure in a rotary evaporator.<sup>9</sup>

### Animals

A total of 55 male Sprague-Dawley rats weighing 200–400 g were purchased from the Center of Comparative and Experimental Medicine, Shiraz University of Medical Sciences.

The study was approved by the Ethics Committee of Fasa University of Medical Sciences under registration number: IR.FUMS.REC.1395.88. All animals were fed *ad libitum* with the standard laboratory chow and water and housed in a restricted-access room, maintained at 23 °C and a 55% relative humidity with a 12:12 h light:dark cycle. All of the procedures in this study were carried out in accordance with the ethical standards of the Helsinki Declaration of 2008 and approved by the Ethics committee of Fasa University of Medical Sciences.

### Induction of UC and interventions

The bowels of the animals were cleaned as they were fasted 24 h prior to UC induction. A 2 mm diameter polypropylene cannula was inserted through the rectum into the colon and placed 8 cm proximal to the anus verge for injection of 2 ml of 3% acetic acid under ether anesthesia. For 30s, the rats were maintained in a supine Trendelenburg position to prevent early leakage of the intracolonic instillate and for proper colitis induction.<sup>10</sup> Rats were randomly divided into 5 equal groups as follows and treatments were started immediately:

- Group 1: received 250 mg/kg asacol
- Group 2: received 1 ml gel base carboxymethyl cellulose
- Group 3: received 0.5% gel extract of *C. sempervirens*
- Group 4: received 1% gel extract of *C. sempervirens*
- Group 5: considered as negative control and received 1 ml of normal saline

### Weighing and sampling

Body weight changes were recorded prior to the study on day 0 and on the 3rd, 5th and 7th days, with the use of a digital scale with 0.1 g precision. All animals were euthanized under deep anesthesia after seven days of therapy. Laparotomy was performed and the 8 cm of the distal colon was removed for histopathological examination and biochemical investigation.

### Histopathological evaluations

For histopathological evaluation, 2 cm of the severed colonic tissue was fixed in 10% buffered formalin. They were embedded in paraffin and cut into 5 μm thick sections and stained with hematoxylin and eosin (H&E) for proper study under a light microscope. All the slides were reviewed by a single blinded pathologist and the degree of inflammation severity and extent, crypt damage, percentage of involvement and regeneration were evaluated on a scale of 0–4.

### Oxidative stress evaluation

Colon samples were stored in liquid nitrogen immediately until analysis. About 0.5 g of each tissue sample was homogenized in 5 ml of 0.05 M phosphate buffer saline pH 7.4. Then, the samples were centrifuged at 3500 rpm for 15 min. The supernatants were then collected and stored at –20 °C. These samples were used to evaluate antioxidant indices as follows:

- Total antioxidant capacity (TAC) was evaluated by ELISA (ZB-TAC-96A, ZellBio GmbH, Germany) and considered as the amount of antioxidant in the sample compared with ascorbic acid action as a standard. This method can determine TAC with 0.1 mM sensitivity ( $100 \mu\text{mol L}^{-1}$ ) colorimetrically at 490 nm.
- Superoxide dismutase (SOD) was evaluated by ELISA (ZB-SOD-96A, ZellBio GmbH, Germany). In this assay, SOD activity unit was considered as the amount of the sample that will catalyze the decomposition of 1 μmol of  $\text{O}_2^-$  and  $\text{H}_2\text{O}_2$  and  $\text{O}_2$  in 1 min colorimetrically at 420 nm. The SOD activity was expressed as unit per g of tissue (U/g).
- Glutathione peroxidase (GPx) activities were measured by ELISA (BXC0551, Biorexfars, Iran). GPx exist in the cytoplasm and mitochondria of cells and catalyzes the oxidation of glutathione (GSH) by cumene hydroperoxide. One unit of GPx activity was defined as the amount of enzyme that converts 1 μmol of NADPH to NADP<sup>+</sup> per minute. The GPx activity was expressed as unit per g of tissue (U/g).

### Statistical analysis

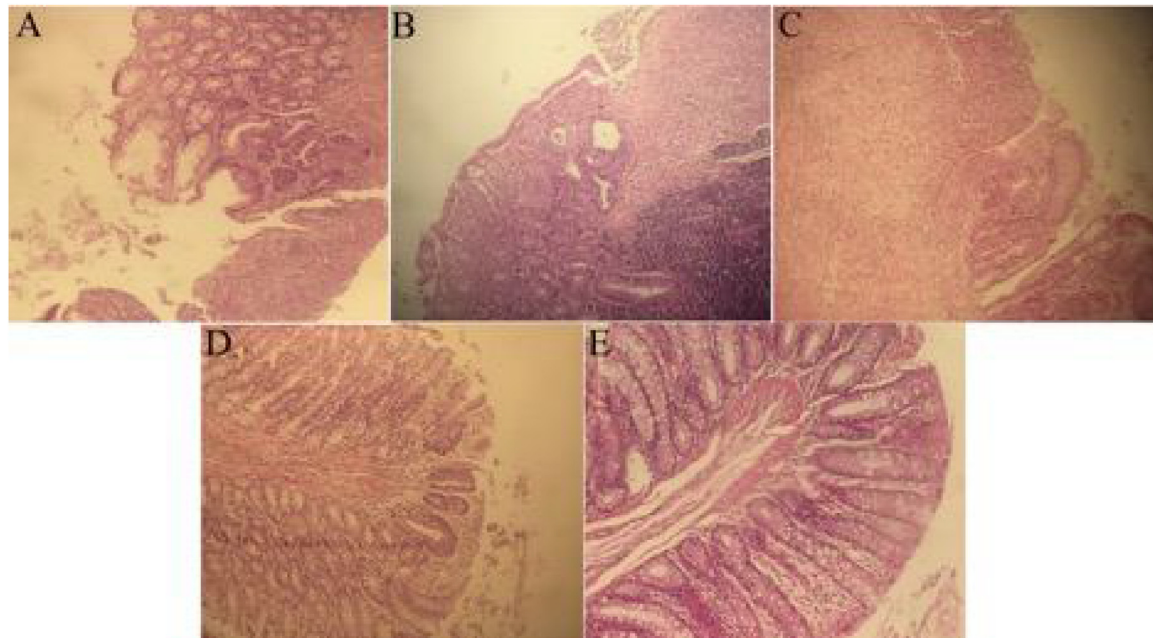
Data were expressed as mean and standard deviation (SD) or mean rank. SPSS version 21 for statistical analysis and GraphPad Prism 7.0 for drawing the figure were used. Between group differences in weight and antioxidant statuses were analyzed by One-way ANOVA and Tukey test as Posthoc test. Differences in histopathological scores were analyzed using non-parametric Kruskal–Wallis *H* test. *P* value lesser than 0.05 was considered as significant difference.

## Results

The mean weight of rats (in each group at days 0 and 7), TAC, SOD, and GPx activities are presented in Table 1. As shown, rats treated with 1%gel extract of *C. sempervirens* extract showed significant weight gain. As regards the antioxidant assessment, no significant difference was observed in the colon GPx

**Table 1 – Mean weight, TAC, SOD, and GPx activities in different experimental groups.**

	Weight (g)				TAC (μmol/g)	SOD (U/g)	GPx (U/g)
	Day 0	Day 3	Day 5	Day 7			
Asacol	305.00 ± 27.85a	302.50 ± 33.65a	315.75 ± 38.18a	318.42 ± 38.45a	1.36 ± 0.34a	11.03 ± 1.59a	688.58 ± 92.46a
Gel base	220.00 ± 16.57b	219.20 ± 15.37b	217.40 ± 20.06b	222.00 ± 21.86b	1.11 ± 0.24ab	12.26 ± 1.15ab	597.25 ± 127.02a
0.5% gel extract	353.70 ± 16.92c	348.70 ± 18.98c	363.70 ± 21.00ac	366.10 ± 21.27c	1.03 ± 0.12b	13.46 ± 0.95bc	641.18 ± 68.70a
1% gel extract	366.10 ± 23.01c	374.00 ± 25.25c	378.10 ± 26.10c	381.80 ± 26.99c	0.95 ± 0.20b	14.08 ± 1.13c	626.09 ± 50.44a
Negative control	339.70 ± 27.63c	345.90 ± 34.44c	327.20 ± 73.92ac	350.40 ± 37.15ac	–	–	580.43 ± 75.24a



**Fig. 1 – Histopathological lesion in the colon tissue of different groups. A (Asacol), ulceration with crypt disarray and goblet cell depletion; B (gel base) and C (negative control), surface ulceration, goblet depletion, irregularity in crypt architecture and inflammation; D (0.5% extract), regeneration of colonic mucosa with irregularity in crypt architecture, decreased goblet cells and increased inflammation; E (1% extract), restoration of normal colon structure in 1% gel extract (H&E ×400).**

**Table 2 – Comparison of mean rank of different score of pathological changes in different experimental groups.**

Lesions	Asacol	Gel base	Gel extract		Negative control	p-Value
			0.5%	1%		
Inflammation severity	29.45	29.45	19.90	29.70	26.09	0.442
Inflammation extent	28.73	30.18	19.30	29.50	26.82	0.395
Crypt damage	28.59	28.59	20.00	28.75	28.59	0.580
Percent of involvement	27.77	30.68	20.00	28.85	27.23	0.527
Regeneration	28.27	26.50	20.55	30.00	29.36	0.592
Total pathology score	28.50	29.68	19.15	29.50	27.68	0.470

activity among all the groups ( $p > 0.05$ ). However, a significantly higher SOD activity was detected as follows: 0.5 and 1% gel extract groups compared to the Asacol group and in 1% gel extract groups compared to the gel base group. In addition, both the gel extract groups showed significantly lower TAC compared to the Asacol group.

Fig. 1 shows the histopathological features of colon tissues and related lesions. In addition, scoring of the degree of inflammation severity, inflammation extent, crypt damage, percentage of involvement and regeneration are presented in Table 2. Although, several histopathological lesions including inflammation, ulceration, crypt disarray, and goblet cell depletion were identified in the different groups, the mean rank of pathological changes showed no significant difference among the 5 groups.

## Discussion

In the present study, the antioxidant and histopathological features of colon tissue in experimental-induced UC and their

changes in response to rectal use of *C. sempervirens* extract were evaluated and compared. Beneficial effects of *C. sempervirens* extract in healing ulcerated mucosa especially in terms of increased SOD activity was reported. Moreover, our treatment had significant positive effects on weight gain, especially at higher doses.

To the best of our knowledge, there are no previous reports on the evaluation of the effects of *C. sempervirens* on UC. Koriem et al. reported that cupressuflavone, a flavonoid found in *C. sempervirens* showed dose-dependent antiulcerogenic activity on gastric ulcer.<sup>11</sup> Other major components of this plant include amenoflavone, rutin, quercetin and myricitrin flavonoids which also show antioxidant activities.<sup>12</sup> In addition, the leaf extract of *C. sempervirens* is used for the treatment of gastrointestinal disorders<sup>13</sup> and stimulates accelerated action on slow-healing wounds.<sup>14</sup> The major mechanisms of observed therapeutic effects of *C. sempervirens* in this study were not clearly identified. However, the roles of reactive oxygen species (ROS) and oxidative stress in the pathogenesis of experimental-induced UC are well-known.<sup>15-19</sup> On the other hand, previous studies have confirmed that



*C. sempervirens* plant is a good source of antioxidants.<sup>20,21</sup> Moreover, it has been reported that this plant possesses antimicrobial properties.<sup>7</sup> Since it is known that one of the causative agents of UC is microbial invasion, it is possible that *C. sempervirens* and its derivatives modulate microbial activity and combat ROSs in the intestine and thus, help to heal lesions in the UC. Such antioxidant and antimicrobial properties have also been reported in previous *in vivo* and *in vitro* studies<sup>22–24</sup> of which this study is in agreement.

Despite the results obtained, this study has two limitations. First, the lack of molecular evaluation of the ulceration and healing changes in the intestinal mucosa such as apoptosis and autophagy pathways. Second, no assessment of inflammatory indices such as interleukins or tumor necrosis factors in the tissue. However, the results of this study were confirmed by histological and antioxidant evaluations which showed that the hydroalcoholic extracts of *C. sempervirens* leaves have several beneficial effects in acetic acid-induced UC. These therapeutic effects were due to the presence of flavonoid compounds, especially cupressuflavone. Conclusively, the findings of this study will provide new opportunities for the development of novel therapeutic alternative agents for UC.

### Conflicts of interest

The authors declare no conflicts of interest.

### Acknowledgements

The authors acknowledge Fasa University of Medical Sciences for supporting this work (grant number: 95062).

### REFERENCES

- Hosseini SV, Taghavi SA, Jafari P, Rezaianzadeh A, Moini M, Mehrabi M, et al. Incidence of ulcerative colitis relapse: a prospective cohort study in southern Iran. *Ann Colorectal Res.* 2016;4.
- Lankarani KB, Sepehrimanesh M, Seghatoleslam SF, Hoseini SE, Ghavami S. Autophagy-related protein 7 level in patients with ulcerative colitis. *Scand J Gastroenterol.* 2017;52:468.
- Taghavi SA, Majd SK, Sianati M, Sepehrimanesh M. Prevalence of IgG-4-associated cholangiopathy based on serum IgG-4 levels in patients with primary sclerosing cholangitis and its relationship with inflammatory bowel disease. *Turk J Gastroenterol.* 2016;27:547–52.
- Tanideh N, Nematollahi SL, Hosseini SV, Hosseinzadeh M, Mehrabani D, Safarpour A, et al. The healing effect of hydroalcoholic extract of *Hypericum perforatum* on acetic acid-induced ulcerative colitis in male rats. *J Fasa Univ Med Sci.* 2017;6:530–7.
- Sepehrimanesh M, Poorbaghi SL. Ulcerative colitis: a phytomedicine technical note. *Compar Clin Pathol.* 2017;26:1237–9, <http://dx.doi.org/10.1007/s00580-017-2552-x>.
- Tumen I, Süntar I, Keleş H, Küpeli Akkol E. A therapeutic approach for wound healing by using essential oils of *Cupressus* and *Juniperus* species growing in Turkey. *Evid Based Complement Altern Med.* 2012.
- Selim SA, Adam ME, Hassan SM, Albalawi AR. Chemical composition, antimicrobial and antibiofilm activity of the essential oil and methanol extract of the Mediterranean cypress (*Cupressus sempervirens* L.). *BMC Complement Altern Med.* 2014;14:179.
- Asgary S, Naderi GA, Shams Ardekani MR, Sahebkar A, Airin A, Aslani S, et al. Chemical analysis and biological activities of *Cupressus sempervirens* var. *horizontalis* essential oils. *Pharm Biol.* 2013;51:137–44.
- Koohi-Hosseiniabadi O, Moini M, Safarpour A, Derakhshanfar A, Sepehrimanesh M. Effects of dietary *Thymus vulgaris* extract alone or with atorvastatin on the liver, kidney, heart, and brain histopathological features in diabetic and hyperlipidemic male rats. *Comp Clin Pathol.* 2015;24:1311–5.
- Millar A, Rampton DS, Chandler CL, Claxson AW, Blades S, Coumbe A, et al. Evaluating the antioxidant potential of new treatments for inflammatory bowel disease using a rat model of colitis. *Gut.* 1996;39:407–15.
- Korieri KMM, Gad IB, Nasiry ZK. Protective effect of *Cupressus sempervirens* extract against indomethacin-induced gastric ulcer in rats. *Interdiscip Toxicol.* 2015;8:25–34, <http://dx.doi.org/10.1515/intox-2015-0006>.
- Waisel Y, Epstein V. How to reduce air pollution by *Cupressus* pollen? *Allerg Immunol (Paris).* 2000;32:141–2.
- Ibrahim NA, El-Seedi HR, Mohammed MM. Phytochemical investigation and hepatoprotective activity of *Cupressus sempervirens* L. leaves growing in Egypt. *Nat Prod Res.* 2007;21:857–66, <http://dx.doi.org/10.1080/14786410601132477>.
- Chiej R. *Encyclopaedia of medicinal plants.* London: MacDonald; 1984. p. 54–62.
- Safarpour AR, Kaviani F, Sepehrimanesh M, Ahmadi N, Hosseiniabadi OK, Tanideh N, et al. Antioxidant and anti-inflammatory effects of gel and aqueous extract of *Melilotus officinalis* L. in induced ulcerative colitis: a *Rattus norvegicus* model. *Ann Colorectal Res.* 2015;3.
- Saito R, Tamura M, Matsui H, Nagano Y, Suzuki H, Kaneko T, et al. Qing Dai attenuates nonsteroidal anti-inflammatory drug-induced mitochondrial reactive oxygen species in gastrointestinal epithelial cells. *J Clin Biochem Nutr.* 2015;56:8–14, <http://dx.doi.org/10.3164/jcbn.14-59>.
- Tanideh N, Jamshidzadeh A, Sepehrimanesh M, Hosseinzadeh M, Hosseiniabadi OK, Najibi A, et al. Healing acceleration of acetic acid-induced colitis by marigold (*Calendula officinalis*) in male rats. *Saudi J Gastroenterol.* 2016;22:50–6.
- Tanideh N, Nematollahi SL, Hosseini SV, Hosseinzadeh M, Mehrabani D, Safarpour A, et al. The healing effect of *Hypericum perforatum* extract on acetic acid-induced ulcerative colitis in rat. *Ann Colorectal Res.* 2014;2.
- Wang Z, Li S, Cao Y, Tian X, Zeng R, Liao DF, et al. Oxidative stress and carbonyl lesions in ulcerative colitis and associated colorectal cancer. *Oxid Med Cell Longev.* 2016;9875298, <http://dx.doi.org/10.1155/2016/9875298>.
- Asgary S, Naderi GA, Shams Ardekani MR, Sahebkar A, Airin A, Aslani S, et al. Chemical analysis and biological activities of *Cupressus sempervirens* var. *horizontalis* essential oils. *Pharm Biol.* 2013;51:137–44, <http://dx.doi.org/10.3109/13880209.2012.715168>.
- Senol FS, Orhan IE, Ustun O. In vitro cholinesterase inhibitory and antioxidant effect of selected coniferous tree species. *Asian Pac J Trop Med.* 2015;8:269–75, [http://dx.doi.org/10.1016/s1995-7645\(14\)60329-1](http://dx.doi.org/10.1016/s1995-7645(14)60329-1).
- Afsharzadeh M, Naderinasab M, Tayarani Najaran Z, Barzin M, Emami SA. In-vitro antimicrobial activities of some Iranian conifers. *Iran J Pharm Res.* 2013;12:63–74.
- Emami SA, Asili J, Mohagheghi Z, Hassanzadeh MK. Antioxidant activity of leaves and fruits of Iranian conifers. *Evid Based Complement Altern Med.* 2007;4:313–9, <http://dx.doi.org/10.1093/ecam/nem011>.
- Ibrahim NA, El-Seedi HR, Mohammed MM. Phytochemical investigation and hepatoprotective activity of *Cupressus sempervirens* L. leaves growing in Egypt. *Nat Prod Res.* 2007;21:857–66, <http://dx.doi.org/10.1080/14786410601132477>.