



Original Article

# Comparison of conventional and structured report in the evaluation of Crohn's disease through enterography



Alvaro Ariel Gomez<sup>a</sup>, Thiago Franchi Nunes<sup>a</sup>, Carlos Henrique Marques dos Santos<sup>a,b,\*</sup>, Denise Maria Rissato<sup>a</sup>, Tiago Kojun Tibana<sup>a</sup>, Isa Felix Adôrno<sup>a</sup>, Doroty Mesquita Dourado<sup>b</sup>

<sup>a</sup> Hospital Universitário Maria Aparecida Pedrossian, Campo Grande, MS, Brazil

<sup>b</sup> Universidade Anhaguera (Uniderp), Campo Grande, MS, Brazil

ARTICLE INFO

Article history:

Received 30 March 2018

Accepted 30 May 2018

Available online 18 July 2018

Keywords:

Crohn's disease

Tomography

Small intestine

Complications

Diagnosis

ABSTRACT

**Context:** There is an increasing interest in the standardization of the evaluation of imaging exams, especially enterography in Crohn's disease.

**Objective:** To compare the quality of the conventional report with the structured report in computed tomography enterography in Crohn's disease.

**Method:** Nine CT enterographies of patients with Crohn's disease with conventional reports were performed; after the standardization of the structured report by the radiology department of a university hospital that is a reference in the care of patients with inflammatory bowel diseases, the same exams were reevaluated, and new reports were issued, without the radiologists having access to the previous report; the 18 reports underwent evaluation of five specialists in Inflammatory Bowel Diseases, resulting in 90 analyses of the report; the specialists evaluated the following criteria: clarity of the information of the report, ease in characterizing the extension of the disease, ease in defining the presence of complications, usefulness of the exam to define the behavior, and ease in defining the activity of the disease, with the use of a 0-10 score. The statistical analysis was performed with Wilcoxon's non-parametric test, considering a significance level of 5%.

**Results:** The mean scores assigned to the exam reports, using both reports (unstructured and structured) ranged from 7.98 to 9.16; however, the scores of the structured reports were significantly higher ( $p < 0.003$ ).

**Conclusion:** In the specialists' evaluation, the structured report was shown to be of better quality than the unstructured one in the CT enterography of patients with Crohn's Disease.

© 2018 Sociedade Brasileira de Coloproctologia. Published by Elsevier Editora Ltda. This is an open access article under the CC BY-NC-ND license (<http://creativecommons.org/licenses/by-nc-nd/4.0/>).

\* Corresponding author.

E-mail: [chenriquems@yahoo.com.br](mailto:chenriquems@yahoo.com.br) (C.H. Santos).

<https://doi.org/10.1016/j.jcol.2018.05.011>

2237-9363/© 2018 Sociedade Brasileira de Coloproctologia. Published by Elsevier Editora Ltda. This is an open access article under the CC BY-NC-ND license (<http://creativecommons.org/licenses/by-nc-nd/4.0/>).

## Comparação entre laudo convencional e estruturado na avaliação da Doença de Crohn por enterografia

### R E S U M O

*Palavras-chave:*  
Doença de Crohn  
Tomografia  
Intestino delgado  
Complicações  
Diagnóstico

**Contexto:** Há cada vez maior interesse em padronização na avaliação de exames de imagem, em especial a enterografia na Doença de Crohn.

**Objetivo:** Comparar a qualidade do laudo convencional com o estruturado na enterografia por tomografia computadorizada na Doença de Crohn.

**Método:** Foram realizados nove enterografias por TC de pacientes com Doença de Crohn com laudos convencionais; após a padronização do laudo estruturado pelo serviço de radiologia um hospital universitário, referência no atendimento de pacientes com doenças inflamatórias intestinais, os mesmos exames foram reavaliados e novos laudos foram emitidos, sem que os radiologistas tivessem acesso ao laudo anterior; os 18 laudos foram submetidos a avaliação de cinco especialistas em Doenças Inflamatórias Intestinais, resultando em 90 análises de laudo; os especialistas avaliaram os seguintes critérios: clareza das informações do laudo, facilidade em caracterizar a extensão da doença, facilidade em definir a presença de complicações, utilidade do exame para definir a conduta e facilidade em definir a atividade da doença, conferindo uma pontuação de 0 a 10. A análise estatística foi realizada com o teste não paramétrico de Wilcoxon, considerando-se nível de significância de 5%.

**Resultados:** os escores médios atribuídos aos laudos do exame, usando ambos os relatórios (não estruturado e estruturado), variaram de 7,98 a 9,16; todavia, os escores dos laudos estruturados foram significativamente maiores ( $p < 0,003$ ).

**Conclusão:** Na avaliação dos especialistas o laudo estruturado mostrou-se de melhor qualidade que o não estruturado na enterografia por tomografia computadorizada de pacientes com Doença de Crohn.

© 2018 Sociedade Brasileira de Coloproctologia. Publicado por Elsevier Editora Ltda. Este é um artigo Open Access sob uma licença CC BY-NC-ND (<http://creativecommons.org/licenses/by-nc-nd/4.0/>).

## Introduction

The investigation of the small intestine can be performed through endoscopic capsule or double balloon stereoscopy, which are very good methods, especially the enteroscopy that allows the performance of biopsies; however, it is of high cost and poorly available in most medical centers. Therefore, enterography has been performed all over the world to exam the small intestine, either through Computed Tomography (CT) or Magnetic Resonance (MRI). CT enterography would have the advantage of being a more available and better applied method for the diagnosis of abdominal abscesses, whereas MRI enterography would have the great benefit of not exposing patients to ionizing radiation.<sup>1,2</sup>

Although the method is indisputably useful in the diagnosis and follow-up of patients with CD, allowing assessment of disease activity, post-remission sequelae such as stenosis and other complications, the lack of standardization in its analysis is questioned, which could make the interpretation of the attending physician confused.<sup>3</sup>

In the active disease, there are changes commonly observed on CT enterography, such as intestinal wall edema, iodinated contrast hyperuptake, mesentery infiltration, and vascular engorgement, whereas in the disease in remission, fibrosis thickening of the wall can be observed, with no contrast hyperuptake, as well as absence of other signs.

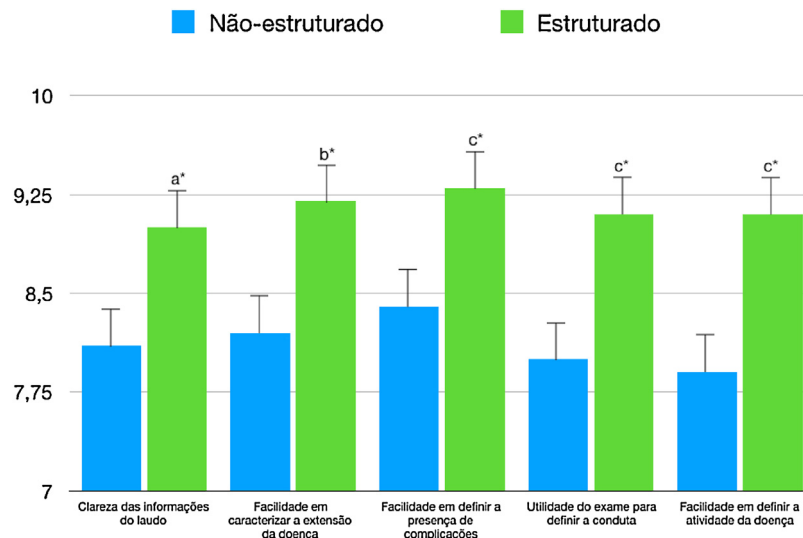
Complications of the disease such as stenosis and upstream dilation are also frequent findings, in addition to abscesses, fistulas and deformities. There are also findings related or not to the disease, for example, alterations in the bile ducts, hydronephrosis, nephrolithiasis, etc.<sup>4,5</sup>

Therefore, faced with so many possible findings of the method, many experts and authors have discussed the importance of making the report better understood, with some proposing standardization, to make interpretation, as well as comparison with previous exams, easier.

For this purpose, Panizza et al.<sup>6</sup> published a proposal of analysis of the examination, and standardization of the report, which now requires its practical validation by the community of specialists treating patients with Inflammatory Bowel Disease (IBD). This is the proposal of the present research, that is, to evaluate the proposed method of standardized report comparing it with previously performed reports of patients known to have CD.

## Objective

To evaluate the quality of the structured report compared to the conventional CT enterography scan of patients with Crohn's disease according to the opinion of specialists in intestinal inflammatory diseases.



**Fig. 1 – Averages of evaluations of structured and unstructured reports of Computed Tomography Enterography of patients with Crohn's Disease. Note: a\*,  $p = 0.003$ ; b\*,  $p = 0.002$ ; c\*,  $p < 0.001$ ; (Wilcoxon test).**

## Materials and methods

The study was approved by the Research Ethics Committee of the Federal University of Mato Grosso do Sul, with all patients signing a free and informed consent form. The research was conducted in a single institution, the University Hospital "Maria Aparecida Pedrossian" of the Federal University of Mato Grosso do Sul, between September 2017 and January 2018.

We selected nine CT enterography scans of patients with CD performed in the radiology department of the University Hospital Maria Aparecida Pedrossian with conventional reports. The same tests were reevaluated by radiologists of the same service after the standardization proposed by Panizza et al.<sup>6</sup> without them having access to the previous report. The two reports of each of the nine exams were then presented to five specialist physicians who routinely treat patients with CD so that they judged the reports for: (1) Clarity of report information; (2) Ease in characterizing the extension of the disease; (3) Ease in defining the presence of complications; (4) Usefulness of the exam to define the behavior and; (5) Ease in defining disease activity. These five criteria of analysis were proposed by the authors, and were considered the most important aspects that a physician dedicated to IBD patients care wishes to obtain in an enterography report. Although inspired by similar research on structured reports,<sup>7-9</sup> this is a proposed method of evaluation that is not validated and does not have direct parameter of comparison with the literature, since there are not similar researches published so far.

Analysts should give a score from 0 to 10 to each of these items so that the researchers could later compare the structured and unstructured reports, in a total of 90 evaluations (45 structured and 45 unstructured). The evaluators were two gastroenterologists and three digestive surgeons who work in the care of IBD patients, predominantly in university centers and all with more than 10 years of graduation.

After the comparison between the structured and unstructured reports regarding the scores assigned to the exam report, in each evaluation criterion, the scores averages were calculated and compared with statistical analysis using the non-parametric Wilcoxon test, with the level of significance of 5% being considered, and the Sigma Plot software, version 12.5 being used.

## Results

The reports analyses results made by the five specialist physicians regarding the structured and unstructured reports are illustrated in Fig. 1.

In all of the evaluation criteria used in this study, the mean scores assigned to the exam reports using both reporting models were high, ranging from 7.98 to 9.16. However, the scores assigned to the exam reports using the structured approach were significantly higher than those obtained using the unstructured approach (Wilcoxon test,  $p$  value ranging from  $<0.001$  to  $0.003$ ), i.e. the structured report received a score higher than the unstructured report in relation to the criteria "Clarity of the report information" ( $p = 0.003$ ); "Ease in characterizing the extension of the disease" ( $p = 0.002$ ); "Ease in defining the presence of complications" ( $p < 0.001$ ); "Usefulness of the test to define the behavior" ( $p < 0.001$ ), and "Ease in defining the disease activity" ( $p < 0.001$ ).

## Discussion

The performance of an imaging test generates great expectation both in the attending physician and in the patients and their relatives, since it can contribute to the diagnosis, define the prognosis, and establish what will be the conduct to be taken thereafter. Based on this, it is not necessary to say that the report of the examination should be as complete and elucidating as possible. Aiming to make the information clearer,

an increasing demand of the assistant physicians, several publications have proposed methods for standardizing imaging exam reports.<sup>10,11</sup>

In a study of structured reports for CT coronary angiography, the physicians' understanding of the degree of stenosis of the major coronary arteries was improved when structured reports were used.<sup>12</sup> Likewise, structured reports have been shown to improve the clinical impact on tumor staging, and on surgical planning for pancreatic and rectal carcinomas.<sup>7</sup> One study showed that less than 50% of the free-text CT reports used for pancreatic cancer staging included standard terminology for vascular involvement, a key component in determining resectability.<sup>8</sup> These deficiencies could be overcome by using structured reporting models. Brook et al.<sup>7</sup> compared the results of structured versus unstructured CT findings report for the staging, and subjective evaluation of pancreatic adenocarcinoma resectability, and confirmed the best quality of the structured one.

Similarly, the present study comparing the structured versus conventional or free-text report was more consistent in terms of clarity of information, ease in defining disease activity, its extension and presence of other complications, as already demonstrated in the study by Panizza et al.<sup>6</sup> on which this structured reporting model was based. These authors propose an organized method of image analysis, starting with mesentery inflammation (Group 1), intestinal wall (Group 2) and complications of the disease (Group 3). Then, the search for extra-intestinal manifestations and differential diagnosis. From this systematized analysis, they propose the use of the structured report, to facilitate the interpretation by the attending physician. In Group 1, mesentery inflammation, lymphadenopathy, changes in fat and vascular engorgement are investigated. In Group 2, intestinal wall, thickening, stratification and permanent structural alterations are investigated. In Group 3, complications of the disease, luminal (stenosis, dilation and cancer) and extraluminal changes (fistula, abscess and perforation) are investigated.

Wildman-Tobriner et al.<sup>13</sup> recently performed a study with a design that is similar to that of the present study, in which radiologists wrote the reports for CT enterographies of patients with Crohn's Disease, in a total of 30 examinations, and later the reports underwent an analysis by general practitioners specialized in inflammatory intestinal diseases, concluding that the structured reports were of better quality than those unstructured in the view of these specialists.

In the evaluation of the magnetic resonance imaging test performed in the pediatric population with Crohn's disease, the same results were found. Three experts evaluated 30 reports, 15 of which were structured and 15 unstructured by MRI, and concluded that the structured one had clearer information, easier diagnosis of the disease and its complications.<sup>9</sup>

Although there may be a slight increase in the amount of time required to produce each report, the advantages of more consistent reporting and fewer confounding factors for the ordering professionals should be considered. In addition, structured reports, if properly stored, could generate a significant resource for future research in the knowledge bases of hospital services data systems. Another fact that should be taken into account is that very often patients with Crohn's disease need to repeat complementary exams, espe-

cially colonoscopy and, more recently, enterography, since the disease is chronic and progressive. Thus, with a structured reporting model it would be easier to compare them with previous exams to define the disease status.<sup>9</sup>

Good quality medicine is becoming increasingly costly, and the addition of new technologies, while making a great contribution to the progress in disease diagnosis and treatment, takes a long time to reach the vast majority of the population. This fact greatly values the findings of the present research, and those by the other authors, who confirmed these results, since without any increase in cost, only changing the way to evaluate or to interpret the exam, better results can be achieved.

However, some studies also report that structured reports may be poorer than free-text reports. Ganeshan et al.<sup>14</sup> in a recent review of the literature on imaging exams, not specifically of enterographies, point out that some radiologists do not see any advantage in this type of report, which could reduce the freedom of the professionals to present the information that they consider more important. The conclusion of the study, however, is that, especially in the opinion of the requesting physicians, the image exams with structured report are better than the unstructured ones.

The limitations of this study include the relatively small number of medical professionals interviewed from a single center, and the small number of evaluated reports. In addition, the evaluation criteria of the conventional and structured reports presented here are a proposal of the authors, prepared by them, without validation and without a method for direct comparison with the literature because no similar studies have been published so far. New multicenter studies and a more expressive cohort are needed to reinforce our hypothesis.

Thus, based on the results obtained here and on the review of the publications regarding reports of structured or unstructured enterography, it is evident that we should move towards standardizing the analysis and description of the findings, in order to facilitate the interpretation by the ordering physician, as well as to make comparisons with previous examinations a very useful and frequent situation in relation to Crohn's Disease.

---

## Conclusion

In the evaluation of the specialists, the structured report was shown to be of better quality than the unstructured one in the CT enterography of patients with Crohn's disease.

---

## Conflicts of interest

The authors declare no conflicts of interest.

---

## REFERENCES

- [1]. Arantes JAV, Santos CHM, Delfino BM, Silva BA, Souza RMM, Souza TMM, et al. Epidemiological profile and clinical characteristics of patients with intestinal inflammatory disease. *J Coloproctol.* 2017;37:273-8.

- [2]. Santos CHM, Menezes JNS, Nunes TF, Martins LA. CT enterography in the evaluation of Crohn's disease. *J Coloproctol*. 2015;35:217-22.
- [3]. D'Ippolito G, Braga FA, Resende MC, Bretas EAS, Nunes TF, Rosas GQ, et al. Enterografia por tomografia computadorizada: uma avaliação de diferentes contrastes orais neutros. *Radiol Bras*. 2012;45:139-43.
- [4]. Costa-Silva L, Martins T, Passos MCF. Enterografia por tomografia computadorizada: experiência inicial na avaliação das doenças do intestino delgado. *Radiol Bras*. 2010;43:303-8.
- [5]. Burlin S, Favaro LR, Bretas EAS, Taniguchi LS, Loch AP, Argollo MC. Avaliação da doença de Crohn por meio da enterografia por tomografia computadorizada: qual o impacto da experiência dos examinadores na reprodutibilidade do método? *Radiol Bras*. 2017;50:13-8.
- [6]. Panizza PS, Viana PC, Horvat N, Júnior Dos Santos VR, de Araújo DA, Yamanari TR, et al. Inflammatory bowel disease: current role of imaging in diagnosis and detection of complications: gastrointestinal imaging. *Radiographics*. 2017;37:701-2.
- [7]. Brook OR, Brook A, Vollmer CM, Kent TS, Sanchez N, Pedrosa I. Structured reporting of multiphase CT for pancreatic cancer: potential effect on staging and surgical planning. *Radiology*. 2015;274:464-72.
- [8]. Marcal LP, Fox PS, Evans DB, Fleming JB, Varadhachary GR, Katz MH, et al. Analysis of free-form radiology dictations for completeness and clarity for pancreatic cancer staging. *Abdom Imaging*. 2015;40:2391-7.
- [9]. Wildman-Tobriner B, Allen BC, Davis JT, Miller CM, Schooler GR, McGreal NM, et al. Structured reporting of magnetic resonance enterography for pediatric Crohn's Disease: effect on key feature reporting and subjective assessment of disease by referring physicians. *Curr Probl Diagn Radiol*. 2017;46:110-4.
- [10]. Thompson AJ. The radiology report – are we getting the message across? *Clin Radiol*. 2012;67:723.
- [11]. Naik SS, Hanbidge A, Wilson SR. Radiology reports: examining radiologist and clinician preferences regarding style and content. *AJR Am J Roentgenol*. 2001;176:591-8.
- [12]. Bosmans JM, Weyler JJ, Parizel PM. Structure and content of radiology reports, a quantitative and qualitative study in eight medical centers. *Eur J Radiol*. 2009;72:354-8.
- [13]. Wildman-Tobriner B, Allen BC, Bashir MR, Camp M, Miller C, Fiorillo LE, et al. Structured reporting of CT enterography for inflammatory bowel disease: effect on key feature reporting, accuracy across training levels, and subjective assessment of disease by referring physicians. *Abdom Radiol (NY)*. 2017;42:2243-50, <http://dx.doi.org/10.1007/s00261-017-1136-1>.
- [14]. Ganeshan D, Duong PT, Probyn L, Lenchik L, McArthur TA, Retrouvey M, et al. Structured reporting in radiology. *Acad Radiol*. 2018;25:66-73.