



Original Article

Treatment of rats anal fistula with glycerin *Aloe barbadensis* Miller extract



Bruno Cabral Comparin^a, Carlos Henrique Marques dos Santos^{a,b,*},
Doroty Mesquita Dourado^b, Pâmela Micaela Gomes Reichel^a,
Roberta Silva de Paola^a, Elenir Rose Jardim Cury Pontes^a

^a Universidade Federal de Mato Grosso do Sul (UFMS), Hospital Universitário Maria Aparecida Pedrossian, Campo Grande, MS, Brazil

^b Universidade Anhuera (Uniderp), Campo Grande, MS, Brazil

ARTICLE INFO

Article history:

Received 17 April 2018

Accepted 26 May 2018

Available online 6 July 2018

Keywords:

Rats

Rectal fistula

Phytotherapy

Aloe

Therapy

ABSTRACT

Rationale: There is a need for a low cost treatment for complex anal fistulas that can heal without causing fecal incontinence, with room for the study of herbal medicines.

Objective: To evaluate the effect of the glycerin *Aloe barbadensis* Miller extract in the treatment of anal fistula in rats.

Method: Thirty Wistar rats underwent peritoneal anesthesia with ketamine and Xylasine, followed by transfixation of the anal sphincter with a steel wire, which remained for 30 days to develop the anal fistula. After this period, the steel wire was removed and three groups with 10 animals were formed: A (control), without treatment; B (seton), in which a cotton seton was introduced; C (therapeutic seton), in which a cotton thread was introduced as a seton, and *Aloe barbadensis* Miller extract was daily dripped in the seton; after 30 days, the setons of groups B and C were removed, and after two weeks without a seton euthanasia and removal of specimens was conducted, and the fistula closure and the inflammatory process were analyzed.

Results: Fistula persistence was observed in all animals in Group A, six in Group B and three in Group C ($p=0.015$). The mean local inflammation levels were 0.9 in Group A; 0.8 in Group B, and 0 in Group C ($p=0.015$).

Conclusion: The use of a seton soaked in a glycerin *Aloe barbadensis* Miller extract was effective in the healing of anal fistulas in rats, in addition to causing less inflammatory process than the non-phytotherapeutic seton.

© 2018 Sociedade Brasileira de Coloproctologia. Published by Elsevier Editora Ltda. This is an open access article under the CC BY-NC-ND license (<http://creativecommons.org/licenses/by-nc-nd/4.0/>).

* Corresponding author.

E-mail: chenriquems@yahoo.com.br (C.H. Santos).

<https://doi.org/10.1016/j.jcol.2018.05.009>

2237-9363/© 2018 Sociedade Brasileira de Coloproctologia. Published by Elsevier Editora Ltda. This is an open access article under the CC BY-NC-ND license (<http://creativecommons.org/licenses/by-nc-nd/4.0/>).

Tratamento de fístula anal em ratos com extrato glicerinado de *Aloe barbadensis* Miller

R E S U M O

Palavras-chave:

Ratos
Fístula retal
Fitoterapia
Aloe
Terapêutica

Racional: Há necessidade de um tratamento de baixo custo para as fístulas anais complexas que possa curar sem causar incontinência fecal, havendo espaço para o estudo de fitoterápicos.

Objetivo: Avaliar o efeito do extrato glicerinado de *Aloe barbadensis* Miller no tratamento de fístula anal em ratos.

Método: Utilizou-se 30 ratos Wistar, submetidos à anestesia peritoneal com Cetamina e Xilasina, seguida de transfixação do esfíncter anal com fio de aço, que permaneceu por 30 dias para desenvolvimento da fístula anal. Após este período, o fio de aço foi removido e foram formados três grupos com 10 animais: A (controle), sem tratamento; B (sedenho), em que foi introduzido sedenho de algodão; C (sedenho terapêutico), em que foi introduzido fio de algodão como sedenho, e diariamente foi gotejado no sedenho extrato de *Aloe barbadensis* Miller; após 30 dias os sedentos dos Grupos B e C foram removidos, e, após duas semanas sem sedenho foi praticada a eutanásia e remoção dos espécimes, analisando-se fechamento da fístula e processo inflamatório.

Resultados: Houve persistência da fístula em todos os animais do Grupo A, em seis do Grupo B e três do Grupo C ($p=0,015$). As médias do grau de inflamação local foram 0,9 no Grupo A; 0,8 no Grupo B e 0 no Grupo C ($p=0,015$).

Conclusão: O uso de sedenho embebido em extrato glicerinado de *Aloe barbadensis* Miller foi efetivo na cicatrização de fístulas anais em ratos, além de ter causado menor processo inflamatório que o sedenho sem fitoterápico.

© 2018 Sociedade Brasileira de Coloproctologia. Publicado por Elsevier Editora Ltda. Este é um artigo Open Access sob uma licença CC BY-NC-ND (<http://creativecommons.org/licenses/by-nc-nd/4.0/>).

Introduction

Anal fistulas are the second most common anorectal disease, second only to hemorrhoidal disease. They are classified according to Parks in intersphincteric, trans-sphincteric, suprasphincteric, and extra-sphincteric. The low intersphincteric and trans-sphincteric ones are usually treated with fistulotomy or fistulectomy, which are traditional and established techniques due to their good results. The others can be treated by a great number of techniques, since the greater the complexity of the fistula, the greater the risk of fecal incontinence.¹

Among the therapeutic possibilities for the more complex fistulas, one of the oldest alternatives is the use of seton. Apart from the discussion regarding seton material, it can be applied in different ways, with different intents as well.^{2,3} In Crohn's disease-associated fistulas, for example, seton is used to keep the path drained after curettage, in order that the biological agents control the disease so that the fistula closes.⁴ Seton can be tightly applied, to section the sphincter muscles progressively, and at the end of some exchanges, to reach the healing of the fistula, but with the possibility of fecal incontinence.⁵ The loose seton can be used as a step of the treatment, as in the case of the Ligation of Intersphincteric Fistula Tract (LIFT) technique where it can be placed to induce more intense fibrosis of the walls of the fistulous tract, facilitating the second step that consists of the section and ligation of the tract.^{6,7}

The therapeutic approach with the use of seton proposed here is inspired by ancient descriptions of the application

of setons soaked in drugs, usually herbal medicines, used mainly in India.^{8,9} Brazil, for its vast flora, has a large number of publications showing the therapeutic benefits of herbal remedies, but there are no reports of their use in anal fistulas.

Herbal medicines are synthesized drugs based on plant extracts. In general, there has been growing scientific support for its beneficial effects on the body. In addition, their use is consecrated, especially among some populations that have little or no access to the traditional medicine, quite common in several developing regions in Brazil. Among these, *Aloe vera* stands out, specifically the subtype *Aloe barbadensis* Miller, popularly known as aloe. Aloe belongs to the Liliaceae family, native to North Africa, to which more than 300 species belong in several localities, including Brazil. This plant has several documented properties, such as anticarcinogenic, antiallergic, immunostimulating and healing effects. Other studies also highlight, with increasing evidence, other biological effects, such as antibacterial, anti-inflammatory, antiviral and antifungal activities.^{10,11}

Considering that there is no research with the use of this herbal drug in the treatment of anal fistulas, this research aims to evaluate its action in this situation.^{10,11}

Objective

To evaluate the effect of glycerin *Aloe barbadensis* Miller extract on the treatment of anal fistula in rats.

Method

The project was approved by the Animal Experiment Ethics Committee of the Federal University of Mato Grosso do Sul (UFMS).

Thirty Wistar male, adult and albino rats weighing approximately 300 g each were studied, from the Vivarium of the Federal University of Mato Grosso do Sul, where the experiment was performed, observing all the ethical norms established by the Brazilian College of Animal Experimentation – COBEA.

The rats were anesthetized for the production of anal fistulas. Anesthesia was performed by intraperitoneal administration of ketamine and xylazine in the same syringe. The solution consisted of 2 mL of 10% ketamine and 1 mL of 2% xylazine. For each 100 g of body weight, 0.1 mL of the anesthetic solution was infused.

Following anesthesia, the anal fistulas were made. They were performed with the rats in the supine position, with the four limbs abducted. A #1 steel wire (Aciflex[®]) was introduced into the jagged line, crossing the anal sphincter, which was exteriorized 1 cm lateral to the anal margin on the left. After piercing the skin with the needle, the steel wire was cut and a loose knot was made through rotational movements.¹²

After 30 days, the rats were divided into three groups:

- 1 Control group (A): consisting of 10 rats that were only observed after the withdrawal of the steel wire, without other therapeutic actions.
- 2 Seton group (B): consisting of 10 rats in which the steel wires were replaced by a cotton seton 0.
- 3 Seton + glycerin *Aloe barbadensis* Miller extract Group (C): also consisting of 10 rats in which the steel wires were replaced by cotton seton 0 soaked in the extract, which was applied daily, followed by its rotation, so that the product reached the inside portion of the fistula. This second part of the study also lasted 30 days.

After this period, the setons were removed from all animals. After two weeks, new intraperitoneal anesthesia, euthanasia by deepening of the anesthetic plan and removal of the pieces for histological study were performed. A cube was resected, including the rectal canal and the distal rectum, and the area where the steel wire or seton was, to observe whether the fistula was persistent or not. The specimens were washed in saline solution and placed in properly identified flasks containing 10% formaldehyde solution for further histological analysis. Subsequently, hematoxylin- and eosin-stained slides were prepared. The reading and interpretation of the findings were done with the professional not being aware of each animal's group.

Histological analysis was performed with the following aspects being observed:

Persistence of the fistula: observation of persistence or not of the patent fistulous tract.

Inflammatory process: verification of local inflammatory process and its intensity, being classified in Grade 0 (absence of inflammation), Grade 1 (mild inflammation) and Grade 2 (moderate inflammation).

Table 1 – Evaluation of persistence of the fistulous tract in the specimens.

Rats	Group A	Group B	Group C
1	+	+	+
2	+	+	–
3	+	–	–
4	+	–	–
5	+	+	–
6	+	+	+
7	+	–	–
8	+	+	+
9	+	–	–
10	+	+	–
Total	10	6	3 ^a

+ , Persistence of fistula; – , absence of fistula.
^a $p = 0.015$.

Fistula tract area: in those specimens where fistula persistence was observed, its areas were measured by means of the software CT capture program in micrometers and compared to the means of the groups.

The results were submitted to statistical treatment by the Kruskal–Wallis test followed by the Dunn test. The level of significance was set at 5% and the Statistical Package for Social Sciences 24 (SPSS 24) software was used.

Results

Regarding the closure of the fistula, it was observed that in the control group (Group A), there was no closure of any of the 10 fistulas. In the seton group (Group B), four of the 10 fistulas were closed, and in Group C, seven of the 10 fistulas were closed, demonstrating that in this group there was less persistence of the fistulous tract than in the others; with $p = 0.015$ (Table 1).

Regarding the evaluation of the specimens inflammatory process, it was observed that in Group A four animals had no inflammation, three had mild inflammation and three had moderate inflammation, resulting in a mean of 0.9. In Group B, three animals had no inflammatory process, six had mild inflammation and only one had moderate inflammation, resulting in a mean of 0.8. In Group C, no animal had an inflammatory process. Thus, this group had the lowest degree of inflammation when compared to the others ($p = 0.015$) (Table 2).

By evaluating the area of the persistent fistulous tracts, a mean of 29.6 μm was obtained in Group A; 17.5 μm in Group B, and 8.16 μm in Group C; with $p = 0.015$ (Table 3) (Fig. 1A and B).

Discussion

According to Gokulakrishna, Hippocrates was the first one to detail the seton method in the anal fistula, when he used horse hair for it. However, it is believed that its use dates from the Egyptians, more than four thousand years ago.⁸

In about 500 BC, the Indian physician Sushruta, a pioneer of plastic surgery, described in his book, Sushruta Samhita, the

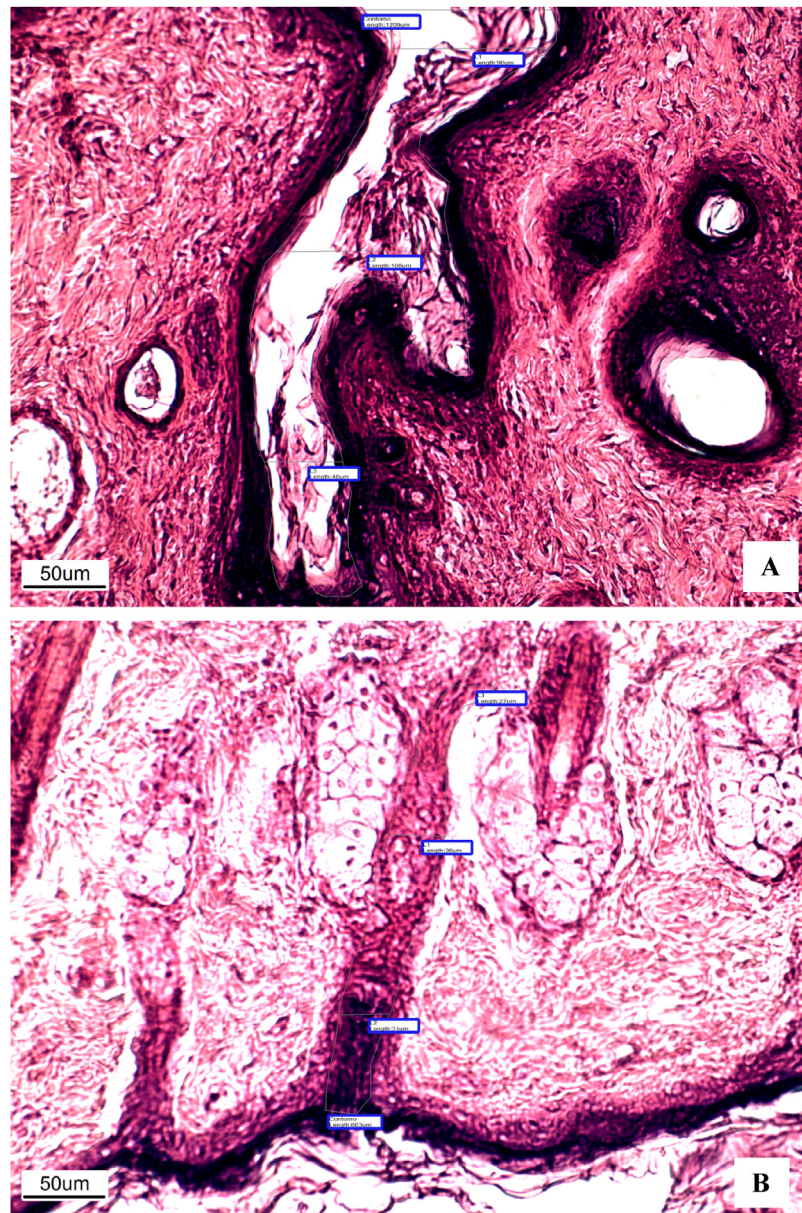


Fig. 1 – (A) Photomicrography of one of the animals in Group B which had the area of persistence of the fistulous tract measured (100 \times , HE). (B) Photomicrography of one of the animals in Group C which had the area of persistence of the fistulous tract measured (100 \times , HE).

use of seton with medications or extract of natural products for treating anal fistulas. Such treatment was named *Kshara-sutra*. The word derives from the Sanskrit *kshar*, that means something that is corrosive and *sutra*, that is translated as wire.⁸

Although not widespread in the Western world, the *Kshara-sutra* is widely used in the East, with emphasis on India. This country is known to have several families of plants that are born exclusively in their soil, justifying the Indian pioneering in this area.

In 2017, the Indian Council for Medical Research published a review of the country's studies on traditional and phytotherapeutic treatments, highlighting those established over

time due to their safety and good results presented, among them the treatment of anal fistulas with *Kshara-sutra*, or ayurvedic medicinal seton.¹³ Using the same term for the treatment, *Kshara-sutra*, several herbal medicines have been used in medicinal setons in India, such as *Apamarga Kshara*, *Snuhi Ksheera Sutra* and *Tilanal K.S*, most of them not available in our settings.

There are no publications available in the literature of experimental studies with the use of medicinal setons such as the present research, which makes it difficult to compare and analyze the results presented here.

It was observed that the group treated with medicinal setons had closure of the fistula and absence of a local inflam-

Table 2 – Evaluation of the degree of inflammation of the specimens.

Rats	Group A	Group B	Group C
1	0	0	0
2	0	0	0
3	0	0	0
4	0	1	0
5	1	1	0
6	1	1	0
7	1	1	0
8	2	1	0
9	2	1	0
10	2	2	0
Mean ± DP	0.9 ± 0.9	0.8 ± 0.6	0.0 ± 0.0 ^a
Median	1	1	0 ^a

Grade 0, absence of inflammation; Grade 1, mild inflammation; Grade 2, moderate inflammation.

^a $p=0.015$.

Table 3 – Evaluation of the area of remaining fistulous tract.

Rats	Measure of the area in micrometers		
	Group A	Group B	Group C
1	41,809	14,321	7611
2	38,635	10,782	–
3	25,629	–	–
4	20,351	–	–
5	16,115	32,647	–
6	16,317	17,176	8387
7	39,162	–	–
8	35,096	18,594	8556
9	44,147	–	–
10	18,839	12,177	–
Mean	29.6	17.5	8.16

matory process, which, in principle, reinforced the healing and anti-inflammatory effects of *Aloe barbadensis* Miller, already demonstrated in other situations, but not yet tested in the treatment of anal fistulas.^{10,11}

In the present study, none of the animals in the drug-sedentary group presented an inflammatory process after two weeks of treatment, in sharp contrast with the seton and control groups, in which, in fact, the presence of inflammation was expected, since the fistula is a chronic inflammatory process, and multifilament wire setons induce a greater inflammatory response.¹⁴ In a recent study investigating the activities of the *Aloe vera* extract, its anti-inflammatory activity was proven to treat skin wounds. Additionally, the healing of the group treated with this extract was superior, since only the animals treated by this drug achieved total re-epithelialization.¹¹ Thus, the results of this research are in line with the publications on this plant with regard to healing and anti-inflammatory effects.

Mohite et al.¹⁵ used a seton soaked in an herbal medicine in 114 patients with anal fistula for three weeks. All had local purulent secretion, 35 reported anal pain for two to three days, and 18 had local induration, and the mean time of elimination of the seton was eight weeks. At the end of the treatment, all patients showed healing of the fistula without fecal inconti-

nence, with a follow-up ranging from six months to a year and a half.

Another herbal medicine used in the treatment of anal fistulas was ginseng. Ohya et al.¹⁶ evaluated 22 children with anal fistula who had already been treated with the conventional method without success, obtaining healing in 21 of them, of which 5 presented recurrence after the end of the treatment; however, according to the authors, all had healing after the reintroduction of the treatment.

Recently, Mena et al.¹⁷ published a small series of cases of patients treated with medicinal seton of a compound of five herbal medicines. The authors pointed out that no patient had any adverse effects and all patients had healed fistulas in a one-year follow-up, proved by clinical and ultrasonographic evaluation.

Yokogawa et al.¹⁸ compared different herbal medicines in the treatment of anal fistula, and found that *Capsicum Annuum* tincture was superior to *Ficus carica* latex, *Aquirantos fauriei* Kshara and long Turmeric rhizome, for promoting greater inhibition in nitric oxide production.

The comparison of conventional treatment with fistulotomy and medicinal seton was made in the publication by Dutta et al.,¹⁹ in which the authors randomized 26 patients to the kshara-sutra group and 24 to the fistulotomy group, with the same number of intersphincteric and trans-sphincteric fistulas between the two. The phytotherapeutic group had a longer healing time, but less pain throughout the process, while the other factors compared, such as healing rate and incontinence, were similar. Similar results had already been obtained by Ho et al.,²⁰ with the difference that the healing time was the same, with only more pain in the medicinal seton group in the first days.

The comparison that is intended to be made of the medicinal seton is with the techniques used in the treatment of complex fistulas, since the simple ones have quite satisfactory results with the surgical treatment. In a recent study with medicinal seton, there was absence of fecal incontinence, and 3.33% recurrence of anal fistulas, while surgical treatment had fecal incontinence of up to 40%, and recurrence of up to 26.5%, with it being even greater with high anal fistulas. In a follow-up of 50 patients with anal fistula treated with medicinal seton, there was 100% cure after 29 weeks, with 56% of patients having achieved healing in less than 12 weeks. It should be added that 18% of these patients had between six and ten years of disease, 20% had high anal fistula, 28% had two or more concomitant fistulas and 64% had fistulas of more than 10 cm, with some cases reaching 20 cm. After six months of post-treatment follow-up there was no case of fecal incontinence or recurrence.^{9,21}

Considering all the data, the study with medicinal setons should be stimulated. Since its advantages in the treatment of anal fistulas, especially in complex fistulas, are known, because it is less invasive and more efficient, with less chance of complications and recurrence, the medicinal seton should gain more and more space in the scientific settings. Additionally, Aloe has also found growing evidence of medical use, with important antioxidant and healing activities. The antibacterial and anti-inflammatory activities of aloe would have an important impact on the evolution of anal fistulas, because their pathophysiology is based on chronic inflammatory and

infectious conditions. Thus, a seton with aloe extract tends to reach excellent results, and may even alter the paradigms of the treatment of anal fistulas.

An observation that should be carefully considered refers to the fact that even in the three animals of the medicinal seton group that persisted with fistula no inflammation was observed, demonstrating the anti-inflammatory effect of *Aloe barbadensis* Miller. Moreover, in these three cases, the area of the fistulous tract was smaller than in the other groups, showing that they could probably heal after a few days, opening the field for future research of this herbal medicine with different treatment times, in order to evaluate the optimal duration of aloe application.

Several publications have tried to identify the mechanisms by which this plant could offer the good medical results observed. The aloe parenchyma is rich in several substances, among them phenolic compounds. These compounds have a high antioxidant activity and reduce the synthesis of Reactive Oxygen Species (ROS). ROS are known to generate cell aging and are at the basis of various organic diseases, causing damage to DNA or oxidizing lipids and proteins. Among ROS, 2,2-Diphenyl-1-Picrylhydrazyl (DPPH) stands out. A recent study confirmed the *in vitro* sequestering action of the ethanol extract of the aloe gel of this compound, strengthening the antioxidant evidence of this plant.¹⁰

In addition to the aforementioned phenolic compounds, the aloe gel has enzymes, vitamins, mineral salts, and amino acids. In addition, it has anthraquinones, such as aloenine, barbaloin and isobarbaloin, which have been proven to be healers.¹⁰

Thus, it is clear that the use of medicinal setons is not new, which is shown by the large number of publications for several years demonstrating satisfactory results with the method. The greatest difficulty in their analysis, however, lies in the diversity of plants used in these setons, in particular the fact that many of them are not found in all countries, as most of those cited in Indian publications that do not exist in our country. On the other hand, considering our rich flora and also the national publications that show positive effects of several plants in the treatment of many diseases, the combination of these two therapeutic proposals was lacking. This was the intention of this research, where the technique of the medicinal seton was added with the aloe, perhaps the phytotherapeutic with the greatest number of publications demonstrating healing and anti-inflammatory efficacy, exactly what is desired in the treatment of the anal fistula. The results obtained here showed a greater number of healed tracts with aloe, and there was no inflammatory process in the parts of any animal after two weeks of removal of the seton, which did not occur in the other groups, confirming that in this model *Aloe barbadensis* Muller was effective.

Conclusion

The use of a seton soaked in a glycerin *Aloe barbadensis* Miller extract was effective in the healing of anal fistulas in rats, and led to lower inflammatory process than the non-phytotherapeutic seton.

Conflicts of interest

The authors declare no conflicts of interest.

REFERENCES

1. Memon AA, Murtaza G, Azami R, Zafar H, Chawla T, Loghari AA. Treatment of complex fistula in ano with cable-tie seton: a prospective case series. *ISRN Surg.* 2011;2011, 636952.
2. Williams JG, Farrands PA, Williams AB, Taylor BA, Lunniss PJ, Sagar PM, et al. The treatment of anal fistula: ACPGIBI position statement. *Colorectal Dis.* 2007;9 Suppl. 4:18–50.
3. Galvão MO, Santos CHM, Falcão GR. Avaliação da resposta inflamatória produzida por diferentes materiais utilizados como sedenho no tratamento de fistulas perianais: estudo experimental em ratos. *J Coloproctol.* 2016;36:16–20.
4. CMAO Lima, Junqueira FP, Rodrigues MCS, Gutierrez CAS, Domingues RC, Coutinho Junior AC. Avaliação por ressonância magnética das fistulas perianais: ensaio iconográfico. *Radiol Bras.* 2010;3:330–5.
5. Ritchie RD, Sackier JM, Hodde JP. Incontinence rates after cutting seton treatment for anal fistula. *Colorectal Dis.* 2009;11:564–71.
6. Tomyoshi SDT, CHMS Santos. Eficácia da técnica de ligadura interesfincteriana do trato fistuloso (LIFT) no tratamento da fístula anal: resultados iniciais. *ABCD Arq Bras Cir Dig.* 2014;27:101–3.
7. Eitan A, Koliada M, Bicke A. The use of the loose seton technique as a definitive treatment for recurrent and persistent high trans-sphincteric anal fistulas: a long-term outcome. *Dig Surg.* 2012;29:292–300.
8. Subhas G, Bhullar JS, Al-Omari A, Unawane A, Mittal VK, Pearlman R. Setons in the treatment of anal fistula: review of variations in materials and techniques. *Dig Surg.* 2012;29:292–300.
9. Ramesh PB. Anal fistula with foot extension – treated by kshara sutra (medicated seton) therapy: a rare case report. *Int J Surg Case Rep.* 2013;4:573–6.
10. Dias DMO, Silva ARA, Macêdo AAM. Atividade antioxidante *in vitro* do extrato etanólico do gel da Aloe vera (*Aloe barbadensis* Miller). VII CONIP; 2012. ISBN 978-85-62830-10-5.
11. Faleiro CC, Elias STH, Cavalcanti LC, Cavalcanti ASS. O extrato das folhas de babosa, Aloe vera na cicatrização de feridas experimentais em pele de ratos, num ensaio controlado por placebo. *Nat Online.* 2009;7:56–60.
12. Arakaki MS, Santos CHM, Falcão GR, Cassino PC, Nakamura RK, Gomes NF, et al. Experimental model of anal fistula in rats. *J Coloproctol.* 2013;33:135–8.
13. Tandon N, Yadav SS. Contributions of Indian Council of Medical Research (ICMR) in the area of medicinal plants/traditional medicine. *J Ethnopharmacol.* 2017;197:39–45.
14. Galvão MO, Santos CHM, Falcão GR. Evaluation of the inflammatory response induced by different materials in the treatment of perianal fistulas: experimental study in rats. *J Coloproctol.* 2016;36:16–20.
15. Mohite JD, Gawai RS, Rohondia OS, Bapat RD. Ksharsootra (medicated seton) treatment for fistula-in-ano. *Indian J Gastroenterol.* 1997;16:96–7.
16. Ohya T, Usui Y, Okamoto K, Inoue Y, Arai S, Iwai T. Management for fistula-in-ano with ginseng and tang-kuei ten combination. *Pediatr Int.* 2004;46:72–6.
17. Nema A, Gupta SK, Dudhamal TS, Mahanta V. Transrectal ultra sonography based evidence of ksharasutra therapy for

- fistula-in-ano – a case series. *J Ayurveda Integr Med.* 2017;8:113–21.
18. Yokogawa T, Sasaki Y, Ando H, Yamamoto K, Mikage M. Pharmacological evaluation for improvement of Kanazawa Sutra, medicinal thread for anal fistula. *J Nat Med.* 2017;71:339–48.
 19. Dutta G, Bain J, Ray AK, Dey S, Das N, Das B. Comparing Ksharasutra (ayurvedic seton) and open fistulotomy in the management of fistula-in-ano. *J Nat Sci Biol Med.* 2015;6:406–10.
 20. Ho KS, Tsang C, Seow-Choen F, Ho YH, Tang CL, Heah SM, et al. Prospective randomised trial comparing ayurvedic cutting seton and fistulotomy for low fistula-in-ano. *Tech Coloproctol.* 2001;5:137–41.
 21. Panigrahi HK, Rani R, Padhi MM, Lavekar GS. Clinical evaluation of Kshara sutra: therapy in the management of Bhagandara (fistula- in-ano) – a prospective study. *Anc Sci Life.* 2009;28:29–35.