



## Case Report

# Crohn's disease versus *Yersinia enterocolitica* infection – case report – a difficult differential diagnosis



Clarissa Maria Gomes de Almeida<sup>a,\*</sup>, Fauze Camargo Maluf<sup>a</sup>, Feres Camargo Maluf<sup>a</sup>, Valeria P. Lanzoni<sup>b</sup>, Desidério Roberto Kiss<sup>c</sup>, Maristela Gomes de Almeida<sup>c</sup>

<sup>a</sup> Faculdade de Medicina do ABC, Santo André, SP, Brazil

<sup>b</sup> Complexo Hospitalar Professor Edmundo Vasconcelos, Departamento de Patologia, São Paulo, SP, Brazil

<sup>c</sup> Complexo Hospitalar Professor Edmundo Vasconcelos, Serviço de Coloproctologia, São Paulo, SP, Brazil

### ARTICLE INFO

#### Article history:

Received 26 March 2018

Accepted 27 May 2018

Available online 28 June 2018

#### Keywords:

Crohn's disease

*Yersinia enterocolitica*

Infection

Ileitis

#### Palavras-chave:

Doença de Crohn's

*Yersinia enterocolitica*

Infecção

Ileíte

### ABSTRACT

The aim of this report is to present an unusual case of Crohn's disease affecting the terminal ileum; whose principal differential diagnosis was *Yersinia enterocolitica* infection, as the histological features of the resected ileum was common to both diseases. We also describe how the infectious etiology was discarded and the implications for the patient follow-up.

© 2018 Sociedade Brasileira de Coloproctologia. Published by Elsevier Editora Ltda. This is an open access article under the CC BY-NC-ND license (<http://creativecommons.org/licenses/by-nc-nd/4.0/>).

### Doença de Crohn's x *Yersinia enterocolitica* – um difícil diagnóstico diferencial – relato de caso

#### RESUMO

O objetivo desse relato é analisar um caso incomum de doença de Crohn, cujo diagnóstico diferencial, com possível infecção por *Yersinia enterocolitica*, foi dificultado pela presença de alterações histológicas das duas doenças. Descrevemos como foi realizada a exclusão de causas infecciosas e as implicações no acompanhamento do paciente.

© 2018 Sociedade Brasileira de Coloproctologia. Publicado por Elsevier Editora Ltda. Este é um artigo Open Access sob uma licença CC BY-NC-ND (<http://creativecommons.org/licenses/by-nc-nd/4.0/>).

## Introduction

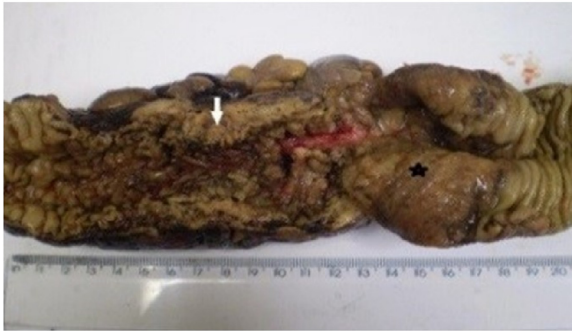Crohn's disease (CD) is a multifactorial disease characterized by a chronic inflammation affecting any segment of the gastrointestinal tract. The characteristic inflammation found in

\* Corresponding author.

E-mail: [dramaristelaga@gmail.com](mailto:dramaristelaga@gmail.com) (C.M. Almeida).

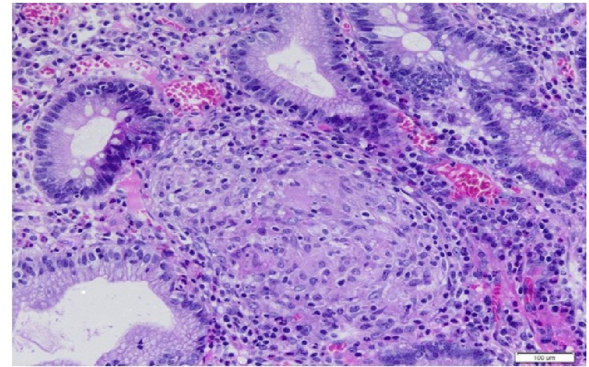
<https://doi.org/10.1016/j.jcol.2018.05.007>

2237-9363/© 2018 Sociedade Brasileira de Coloproctologia. Published by Elsevier Editora Ltda. This is an open access article under the CC BY-NC-ND license (<http://creativecommons.org/licenses/by-nc-nd/4.0/>).



Surgical specimen-Macroscopy

**Fig. 1 – Surgical specimen-commitment of ileum terminal, cecum and right colon. Mucosa of the ileum with extensive ulceration (\*), mucosa of the large intestine with serpiginous ulcers and numerous pseudopolyps. Wall of ileum and colon thickened (arrow).**



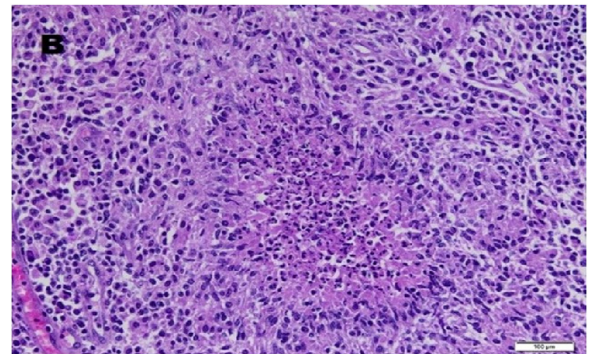
**Fig. 2 – Microscopy-granuloma epithelioid of Crohn's disease. Intestinal mucosa with epithelioid granuloma in the crypt. HE-400x.**

CD is transmural, involving all layers of the intestinal wall, and leading to complications as intestinal obstruction, intramural abscesses and fistulas, and the need of surgical treatment. The terminal ileum is the most frequent site of inflammation, either isolated or associated with lesions in the colon and perianal region. When terminal ileitis presented as an acute inflammatory or obstructive abdomen, with a mass in the right iliac fossa, the main differential diagnosis are acute appendicitis, intestinal tuberculosis and other bacterial infections.<sup>1</sup>

Among bacterial infections, ileitis caused by *Yersinia enterocolitica* (YE), many times, can have the diagnosis confirmed only by the histological examination of the resected segment. In these chronic forms of ileitis, in which histological examination of the surgical specimen presents associated infectious characteristics, the use of special stains, cultures or serological tests are not useful due to their low sensitivity and specificity. More refined histopathological techniques for antigen research, as immunohistochemistry, and detection of molecular material, as in Polymerase Chain Reaction (PCR), are needed. Frequently the association of immunohistochemistry and/or PCR, with clinical, laboratory, radiological and endoscopic findings, is required to confirm the proper diagnosis and follow-up of these patients.

### Case report

A 26 years-old male, animal care technician, living in a rural area, was admitted in May 2014 because of abdominal pain, diarrhea and progressive weight loss in the last three years that has worsened in the recent months. On admission, he presented nausea, vomiting and an acute obstructive abdomen with a palpable mass in the right iliac fossa. The computed tomography scan showed a large mass with decreased bowel lumen and marked distention of small bowel loops. Colonoscopy, after retrograde bowel cleansing,



**Fig. 3 – Microscopy-granuloma by YE. Epithelioid granulomas confluent in the mucosa and intestinal wall and mesenteric lymph nodes, many of them with central suppuration. HE-400x.**

showed an intensive inflammatory process in the cecum that did not allow the progression of the colonoscopy to the terminal ileum. He was submitted to a right hemicolectomy followed by a side-to-side stapled ileocolonic anastomosis. The patient evolved without complications in the postoperative period.

The analysis of the surgical specimen, presented macro and micro-characteristics of CD (Figs. 1 and 2). However, some granulomas found in the intestinal wall and mesenteric lymph nodes presented suppuration suggestive of YE infection (Fig. 3). Immunohistochemistry and PCR for YE, *Yersinia pestis*, *Yersinia pseudotuberculosis*, *Mycobacterium* sp. and only immunohistochemistry for *Brucella* sp. in the specimen's paraffin blocks were performed in the Centers for Disease Control and Prevention laboratory in Atlanta, USA. All tested negative for the bacteria aforementioned. The diagnostic of YE and other infectious agents was excluded and CD was confirmed.

The patient is in follow-up for four years. Currently he is asymptomatic, not taking medications for CD and without evidence of endoscopic recovery.

## Discussion

The characteristic microscopic finding in CD is non-necrotizing granulomas composed of epithelioid histiocytes.<sup>2</sup> In our patient, besides the typical histologic findings of CD we also found in the surgical specimen many suppurative granulomas suggesting YE infection. As the patient was living in rural area and had close contact with animals, the differential diagnosis between YE infection and CD was needed. A misdiagnosis could result in critical delays or errors in the patient management.

YE is a globally distributed gram-negative bacillus that grows especially in low temperature countries and is relatively common in parts of northern Europe. Contaminated foods of swine origin, milk, water and vegetables, and more rarely, contact with host animals, such as pigs, rodents, birds, cattle, horses, sheeps, goats, foxes, porcupines, dogs and cats, can lead to infection by this bacterium.<sup>3</sup> The most common presentation of the disease is a self-limiting gastroenteritis, accompanied by mesenteric adenitis, low-grade fever and abdominal pain, lasting one to three weeks, affecting mainly children. Ileal perforation, rectal bleeding, reactive polyarthrititis and septicemia have been reported as complications of yersiniosis.<sup>1</sup> YE penetrate the intestinal mucosa and invade the underlying lymphoid tissue, mostly Peyer's patches. Disease in older patients generally involves the terminal ileum, mesenteric lymph nodes and appendix, and sometimes can lead to an unnecessary appendectomy. Sonographic or computerized tomography examination may provide indications to the diagnosis, such as mucosal bowel wall thickening with enlarged mesenteric lymph nodes in yersiniosis, whereas in ileocecal CD, transmural inflammation and noncompressible inflamed fat surrounding the ileum is found.<sup>1</sup>

PCR based testing or isolation of the organism from stool, lymph nodes, bile, pharyngeal exudate, blood, abscesses or peritoneal fluid can help the diagnosis of YE infection. Serologic tests are available but generally not indicated in the clinical setting. PCR test in the operative specimens can identify the molecular material of YE and is considered the gold standard for diagnostic confirmation.<sup>4,5</sup> Other infectious agents should be considered in the differential diagnosis of suppurative necrosis granulomas, particularly, *Yersinia pseudotuberculosis*, *Brucella* sp. and *Mycobacterium tuberculosis*. Likewise, molecular and immunohistochemistry tests are important to establish the correct diagnosis for these agents.

The association of past intestinal YE infection and CD has been reported.<sup>4-6</sup> Some investigators consider that infections in childhood may precipitate Crohn's disease by generating an abnormal immune response directed toward cross-reacting antigens in the intestinal mucosa.<sup>4</sup> Indeed, geographic areas where Crohn's disease presents a high incidence, as Northern Europe, also have some of the highest rates of *Yersinia* infection. In the present case, we cannot rule out a past YE infection of our patient, especially when considering the presence of suppurative granulomas found in the pathologic exam.

In conclusion, the differential diagnosis between CD and YE infection was mandatory due to the histopathologic findings of the operative specimen, the occupation, origin of the patient and clinical features. The accurate diagnosis was essential for the adequate follow-up of the patient. Even if he is not currently taking medications for CD, there is a need for constant surveillance, to detect relapses and adequately treat them. Biomolecular methods were essential to achieve this goal.

## Conflicts of interest

The authors declare no conflicts of interest.

## REFERENCES

- [1]. Dilauro S, Crum-Cianflone NF. Ileitis: when it is not Crohn's disease. *Curr Gastroenterol Rep.* 2010;12:249-58.
- [2]. Dudley TH Jr, Dean PJ. Idiopathic granulomatous appendicitis, or Crohn's disease of the appendix revisited. *Hum Pathol.* 1993;24:595-601.
- [3]. Imoto A, Murano M, Hara A, Narabayashi K, Ogura T, Ishida K, et al. Adult intussusception caused by *Yersinia enterocolitica* enterocolitis. *Intern Med.* 2012;51:2545-9.
- [4]. Lamps LW, Madhusudhan KT, Greenson JK, Pierce RH, Massoll NA, Chiles MC, et al. The role of *Yersinia enterocolitica* and *Yersinia pseudotuberculosis* in granulomatous appendicitis: a histologic and molecular study. *Am J Surg Pathol.* 2001;25:508-15.
- [5]. Lamps LW, Madhusudhan KT, Havens JM, Greenson JK, Bronner MP, Chiles MC, et al. Pathogenic *Yersinia* DNA is detected in bowel and mesenteric lymph nodes from patients with Crohn's disease. *Am J Surg Pathol.* 2003;27:220-7.
- [6]. Zippi M, Colaiaicomo MC, Marcheggiano A, Pica R, Paoluzi P, Iaiani G, et al. Mesenteric adenitis caused by *Yersinia pseudotuberculosis* in a patient subsequently diagnosed with Crohn's disease of the terminal ileum. *World J Gastroenterol.* 2006;12:3933-5.