



## Original Article

# Robotic rectal resection: preliminary Russian experience



Igor Khatkov, Stepan Pozdnyakov, Andrey Atroshchenko\*, Mikhail Danilov, Sergey Chudnikh, Zaira Abdulatipova, Igor Dolgopyatov, Georgi Saakjan, Yuri Streltsov, Vladimir Yegorov

Loginov's Moscow Clinical and Scientific Center, Department of Colorectal Surgery, Moscow, Russia

### ARTICLE INFO

#### Article history:

Received 1 February 2018

Accepted 18 May 2018

Available online 8 June 2018

#### Keywords:

Robotic surgery

Rectal cancer

Colorectal surgery

### ABSTRACT

**Purpose:** To outline the preliminary experience of the da Vinci<sup>®</sup> robotic system used in a Moscow tertiary colorectal referral center for an unselected range of benign and malignant rectal conditions.

**Methods:** Prospective non-randomized single-center study which analyzed results of 26 robotic rectal resections performed between January 2014 and December 2016.

**Results:** The cohort included 10 females and 16 males (mean total age 61.6 years). Three patients underwent surgery for benign rectal villous adenomas. The median overall ASA score was 4 (ranged from 2 to 5). Of the surgeries, there were 19 total mesorectal excisions with 6 patients undergoing a multivisceral resection. The mean operating time was 358 minutes with a mean blood loss of 203 mL. All total mesorectal excision specimens were adjudged according Philip Quirke classification as mesorectal plane – Grade 3 with a mean of 18.5 lymph nodes identified (from 12 to 35). Of these there were 10 patients (38.5%) with lymph node metastases. After surgery the average pain score was 2.1 out of 10 on the “Visual-Analogue Pain Intensity Scale” and 1.5 score out of 10 on the “Brief Pain Inventory with Quality of Life”. Anal continency after rectal resection with total mesorectal excisions estimated according Wexner Scale: 10 days after surgery average score was –3.1 and a 6 month after surgery –1.6 score. The median length of hospital stay was 11 days (from 10 to 15).

**Conclusion:** Our initial experience with a totally robotic rectal resection has shown the technique to be safe and feasible, particularly in patients where conventional laparoscopic rectal resection would be anticipated to be challenging.

© 2018 Sociedade Brasileira de Coloproctologia. Published by Elsevier Editora Ltda. This is an open access article under the CC BY-NC-ND license (<http://creativecommons.org/licenses/by-nc-nd/4.0/>).

\* Corresponding author.

E-mail: [dr.atroshchenko@gmail.com](mailto:dr.atroshchenko@gmail.com) (A. Atroshchenko).  
<https://doi.org/10.1016/j.jcol.2018.05.006>

2237-9363/© 2018 Sociedade Brasileira de Coloproctologia. Published by Elsevier Editora Ltda. This is an open access article under the CC BY-NC-ND license (<http://creativecommons.org/licenses/by-nc-nd/4.0/>).

## Ressecção retal robótica: experiência preliminar russa

### R E S U M O

#### Palavras-chave:

Cirurgia robótica  
Câncer retal  
Cirurgia colorretal

**Objetivo:** Delinear a experiência preliminar do sistema robótico da Vinci® usado em um centro de referência colorretal terciário de Moscou para uma gama não selecionada de problemas retais benignos e malignos.

**Métodos:** Estudo unicêntrico prospectivo não randomizado que analisou os resultados de 26 ressecções retais robóticas realizadas entre janeiro de 2014 e dezembro de 2016.

**Resultados:** A coorte incluiu 10 mulheres e 16 homens (idade total média de 61,6 anos). Três pacientes foram submetidos à cirurgia para adenomas vilosos retais benignos. O escore global mediano da ASA foi de 4 (variou de 2 a 5). Das cirurgias, houve 19 excisões mesorretais totais com 6 pacientes submetidos à ressecção multivisceral. O tempo médio de cirurgia foi de 358 minutos, com perda sanguínea média de 203 mL. Todas as amostras de excisão total do mesorreto foram classificadas de acordo com a classificação de Philip Quirke como plano mesorretal - Grau 3 com uma média de 18,5 linfonodos identificados (de 12 a 35). Destes, havia 10 pacientes (38,5%) com metástases linfonodais. Após a cirurgia, o escore médio de dor foi de 2,1 de 10 na Escala de Intensidade da Dor Visual-Analógica e de 1,5 de 10 no "Inventário Breve de Dor com Qualidade de Vida". Continência anal após ressecção retal com excisões totais mesorretais estimadas de acordo com a Escala de Wexner: 10 dias após a cirurgia o escore médio foi -3,1 e um escore de -1,6 após 6 meses da cirurgia. A mediana do tempo de internação foi de 11 dias (de 10 a 15).

**Conclusão:** Nossa experiência inicial com uma ressecção retal totalmente robótica mostrou que a técnica é segura e viável, particularmente em pacientes nos quais a ressecção retal laparoscópica convencional seria prevista como um desafio.

© 2018 Sociedade Brasileira de Coloproctologia. Publicado por Elsevier Editora Ltda. Este é um artigo Open Access sob uma licença CC BY-NC-ND (<http://creativecommons.org/licenses/by-nc-nd/4.0/>).

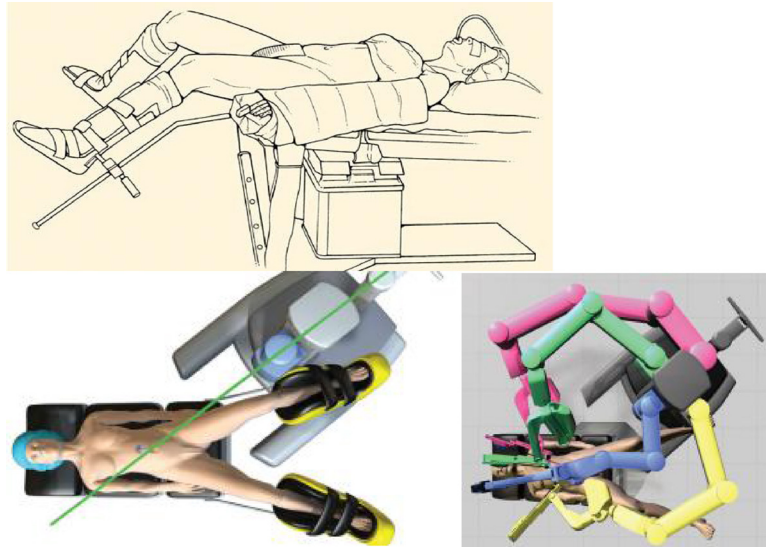
## Introduction

Although there are extensive data showing the feasibility and oncologic safety of laparoscopic rectal resection,<sup>1,2</sup> the approach can be technically challenging.<sup>3-5</sup> Some of the challenges with minimally invasive surgery reflect the ergonomic limitations of the current instrumentation as well as the effects of a restricted tactile feedback. In addition, the constraint of 2-dimensional visualization significantly reduces depth perception and hand-eye coordination.<sup>6</sup> The introduction of the da Vinci® robotic system (Intuitive Surgical, Sunnyvale CA) for proctectomy results in a 3-dimensional view with fixed retraction provided by the assisting robotic arm along with flexible instrumentation which enhances maneuverability. In some surgical environments, the philosophy has been to introduce the robot in order to overcome some of the pitfalls of laparoscopy, thereby providing an alternative to the conventional transition in training and surgical apprenticeship where the trainee would normally graduate from open through to laparoscopic and then to robotic surgery.<sup>7</sup> In rectal resection in particular, the robot can partially overcome the negative impact of a narrow field of vision, (most notably in a small pelvis), magnifying both the autonomic nerves and the correct plane of mesorectal fascial excision. The aims of this paper are to outline the preliminary experience of the da Vinci® robotic system as used in a Moscow tertiary col-

orectal referral centre for an unselected range of benign and malignant rectal diseases.

## Patients and methods

Ethical permission for the assessment of patient records was provided by the University Hospital Ethics Committee of the Loginov Clinical Scientific Centre Moscow. All patients provided informed consent for their procedures. The colorectal Unit performs 150 colorectal resections annually. The study analyzed patients retrospectively with the prospective accumulation of data, assessing all consecutive robotic cases performed between January 2014 and December 2016. All patients were operated upon by a single surgeon (IK). Patients undergoing robotic surgery received an equivalent preoperative work-up to those cases operated upon by different methods including full colonoscopy, tumour biopsy, CT scanning and Magnetic Resonance Imaging (MRI) along with CEA and CA 19-9 estimation. Demographic patient data were collated (American Society of Anesthesiologists Score – ASA score, International Prostate Symptom Score – IPSS score) with performance of preoperative Anorectal Manometry (ARM) and continence grading using the Wexner scale.<sup>8</sup> Postoperative pain was estimated by patients along a Visual-Analogue Pain Intensity Scale and a Brief Pain Inventory with Quality Of Life (QOL) determined by the EORTC-QLQ-C38 validated scale.<sup>9</sup>



**Fig. 1 – Modified padded Lloyd-Davies patient position.**

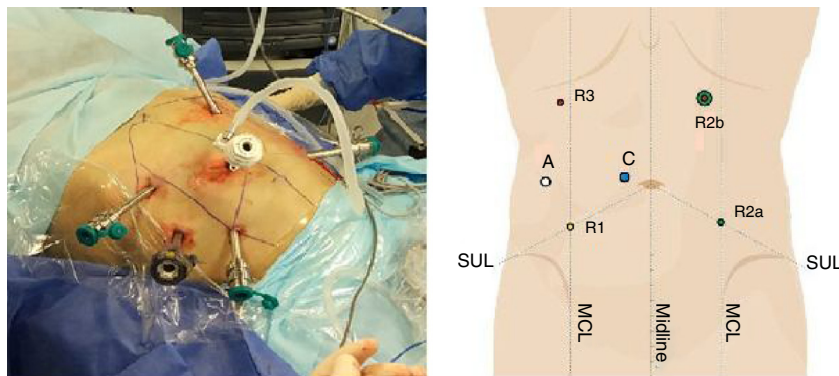
## Operative technique and experience

### Operating room set-up

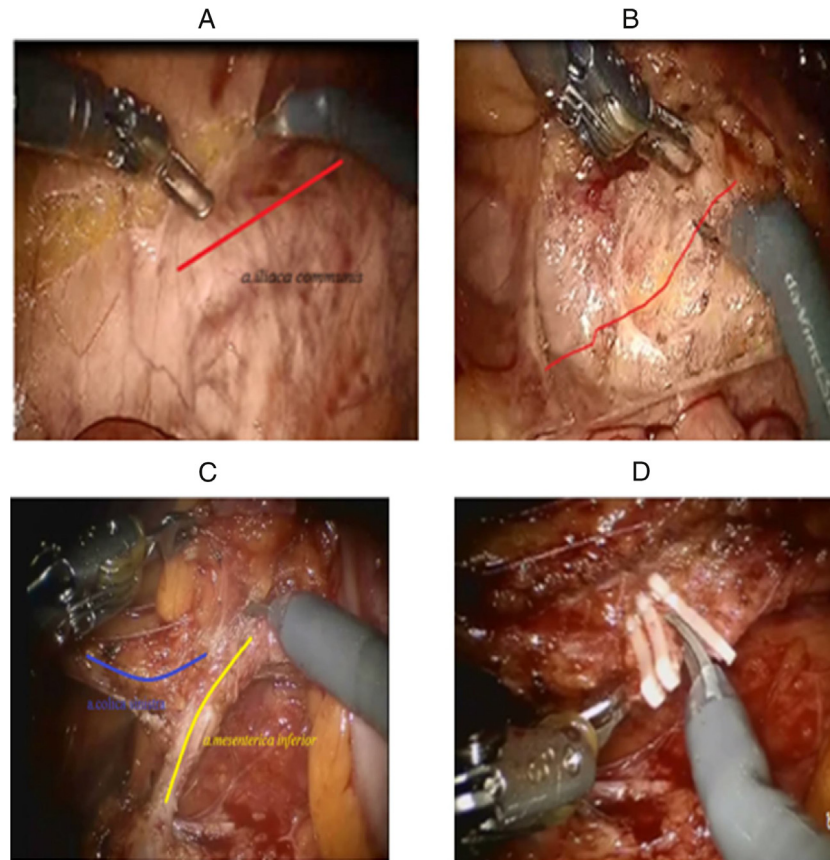
Following the induction of general anaesthesia, patients were placed in the Lloyd-Davies position (Fig. 1) with Trendelenburg tilt. The first 10 procedures were performed with a hybrid surgical technique, with laparoscopic mobilization of the left colon and splenic flexure and a robotic Total Mesorectal Excision (TME). This learning approach was initiated and developed in accordance with other reported studies.<sup>10</sup> The remainder of the cases were conducted as a single-stage totally robotic operation. The single-stage procedure is performed without changing the position of the robotic cart, although the robotic arms are repositioned between operative phases (*vide infra*). Fig. 2 shows a schematic and an operative view of the standard trochar placement following the induction of pneumoperitoneum.

The intra-abdominal pressure is monitored and maintained at 8 mmHg.

The positioning of the ports is demonstrated in Fig. 2. In brief, the robotic trochars (R1, R2 and R3) are placed as shown in the right flank (R1), the left flank (R2a) and the left hypochondrium (R2b) with an R3 right subcostal port. The 4 principal ports are each separated by at least 10 cm from one another and act as the robotic arms in the later cases of totally robotic resections. The robotic cart is positioned obliquely at the left lower quadrant of the abdomen in line between the camera port and the left anterior superior iliac spine. After placement of the ports and positioning of the robot cart, the arms are docked. There is necessary repositioning of the robotic arms during the different steps of surgery; namely during (1) dissection of the main mesenteric vascular pedicle and (2) mobilization of the sigmoid and descending colon and the splenic flexure. For both of these dissections the R1, R2b and R3 ports are used. When the rectum is mobilized down to the levators one of the dissectors is moved to



**Fig. 2 – Trocar positioning (operative and schematic images). Camera port C (12 mm); R1, Right flank trochar (8 mm); R2a, Left flank trochar (8 mm); R2b, Left Hypochondrial trochar (8 mm); R3, Right Hypochondrial trochar (8 mm); A, Assisting port (15 mm).**



**Fig. 3 – Inferior mesenteric vascular isolation (A) and preaortic dissection (B); IMA and IMV isolation (C) and transection (D). A, Opening of the peritoneum above the aorta and the right iliac artery. B, Mobilization of the Inferior Mesenteric Artery (IMA) in front of the embryologic preaortic fascial layer. C, Dissection of the IMA with preservation of the left colic artery (arteria colica sinistra). D, Clipping and transection of the IMA preserving the left colic vessel take-off.**

the R2a position for maximal assistance with the use of both hands.

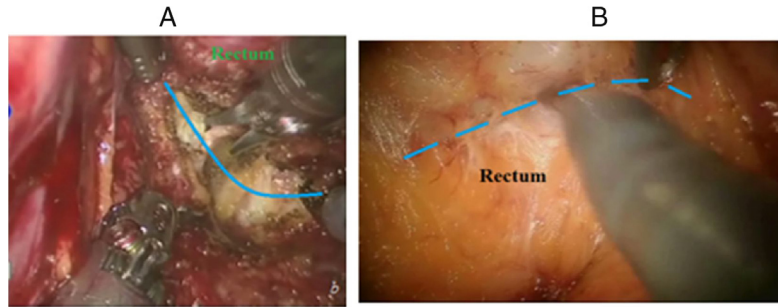
#### **Vascular pedicle ligation and splenic flexure mobilization**

Vascular ligation is performed robotically akin to that conducted laparoscopically. The peritoneum is opened above the right common iliac artery with further dissection of the abdominal aorta up to the Inferior Mesenteric Artery (IMA) and extending to between 1 and 1.5 cm below the visible part of the duodenum until the low horizontal branch of the IMA is demonstrated. Dissection is performed in accordance with the embryological layer which separates the sigmoid mesocolon from the preaortic fascia. A lymphadenectomy is extended distally to the left colic artery with preservation of this vessel, removing tissue from the root of the IMA take-off but taking care to protect the periaortic hypogastric neural plexus. The IMA is clipped with Hem-o-lock laparoscopic clips (Weck Closure System, Research Triangle Park NC) and then transected. The lower Inferior Mesenteric Vein (IMV) is dissected superiorly towards the ligament of Treitz and is divided near the lower border of the pancreas. In the second phase, the left colon is separated from the retroperitoneum identifying the left ureter and gonadal vessels with the assistant retracting the sigmoid medially and providing lateral counter-traction of

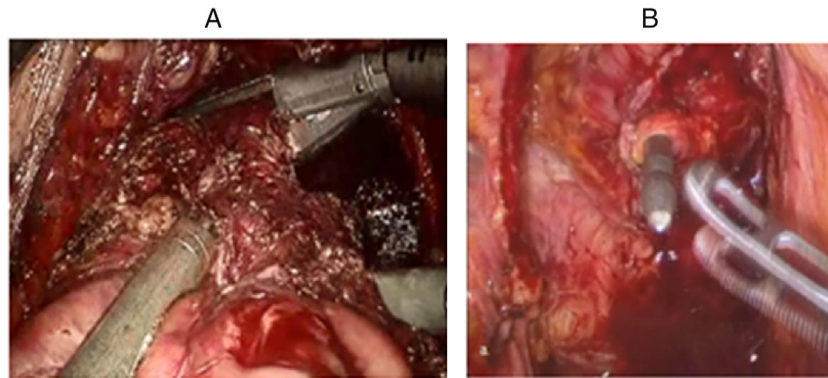
the R2b arm. The R3 arm can assist in pulling the omentum upwards during splenic flexure mobilization. These operative manoeuvres are shown in Fig. 3(A-D).

#### **Rectal mobilization**

The second robot arm is then moved from position R2b to site R2a with dissection of the pelvic peritoneum. The right hypochondrial port is used to retract the rectosigmoid upwards with demonstration of the embryologic TME plane in front of the hypogastric nerves. Further posterior dissection is approached from the left lateral plane lifting the rectum upwards and to the right. Right lateral rectal dissection is then completed in a reverse fashion of retraction with anterior dissection commenced by incising the peritoneal reflection in order to develop the plane between the rectum and either the prostate/seminal vesicle complex or the vagina (Fig. 4A, B). In rectal cancer cases, dependent upon the level of the tumour, either a partial or a Total Mesorectal Excision (TME) is performed. When the mobilization of the rectum is complete, it is transected with an Echelon Flex (Ethicon Endo Surgery, 3.8 mm) linear stapler (40 or 60 mm) or with an Endo-GIA Universal Reticulator (45 or 60 mm). And with intracorporeal anastomosis is constructed inserting the stapler through the rectal stump (Fig. 5A, B). Once the circumferential dissection



**Fig. 4 – Rectal mobilization. A, Left hand side posterior rectal mobilization; B, Line of anterior rectal dissection.**



**Fig. 5 – Rectal transection and intracorporeal anastomosis. A, Stapled rectal transection; B, Circular stapled intracorporeal anastomosis.**

of the rectum is completed, the robotic instruments are disengaged and the cart is withdrawn away from the operating table. The TME specimen is assessed for quality in the standard manner.

**Results**

The initial group included 10 females and 16 males (mean total age 61.6 years ± 9.3 years) with an even distribution in cancer cases of stage (3 patients Stage I, 8 patients Stage II, 7 patients Stage III and 5 patients Stage IV). Three patients were operated on for benign rectal villous adenomas. Two-thirds of patients had significant comorbidities (7 patients with diabetes, 5 patients with respiratory system diseases, 18 with cardiovascular and 12 with others comorbidities) with a median ASA score 4 (from 2 to 5). Of the surgeries, there were 19 total mesorectal excisions (TME) with 6 of whom underwent a multivisceral resection: one patient underwent simultaneous bladder resection in case with locally advanced rectal cancer with urine bladder invasion; one – hysterectomy for big – size hysteromyoma and 3 – undergoing oophorectomy for ovarian cysts) with one synchronous S-VI liver segmentectomy for rectal single small metastasis.

The mean operating time was 358 min (range 210–670 min) with a mean blood loss of 203 mL (range 50–600 mL). Longer operating times were noted with the few combined procedures as well as with the single docking technique of the robotic arms (Table 1). All mesorectal excision specimens were adjudged as a Grade IV according Philip Quirke Classification with average identified lymph nodes 18 (range 13–45). Of these

**Table 1 – Operative times and blood loss for hybrid procedures and single robotic docking.**

Type of operation	Hybrid operations			Robotic single docking		
	Mean	Min	Max	Mean	Min	Max
Time (min)	405	245	670	328	210	435
Blood loss (mL)	255	50	60	172	50	600

there were 10 patients (38.5%) with lymph node metastases. Lymph node detection was dependent upon whether a partial or a total mesorectal excision was performed (partial TME – 7, average lymph nodes – 14.6; range 13–16 vs. TME – 19 – average lymph nodes – 19.6; range 14–45, respectively; differences are not significant according Fisher test – 1.061).

The mean pain score was 2.1/10 (range 0–6.5), with indicators evaluated daily for 10 days after surgery on the visual analogue scale. Values were recorded as 1.5/10 (range 0–10) on the Brief Pain Inventory (BPI) with 2 patients recording a maximum value of 6.5. Only one patient suggested that their pain was severe enough to restrict their normal range of life activities which included day-to-day activities, mood, the ability to perform work duties, sleep and the perception of enjoyment. Part of this data is visually shown in Fig. 6. There were 3 patients with postoperative urinary difficulty (graded on the I-PSS score)<sup>11</sup> including one case of an atonic bladder requiring recatheterization which was converted to a suprapubic cystostomy and which recovered by 4 months of follow-up. The median preoperative Wexner continence score was 2.7 (range 0–7) with a 10 day postoperative Wexner score of 3.1 (range 1–8) and a 6 month postoperative Wexner score of 1.6 (range 0–4).

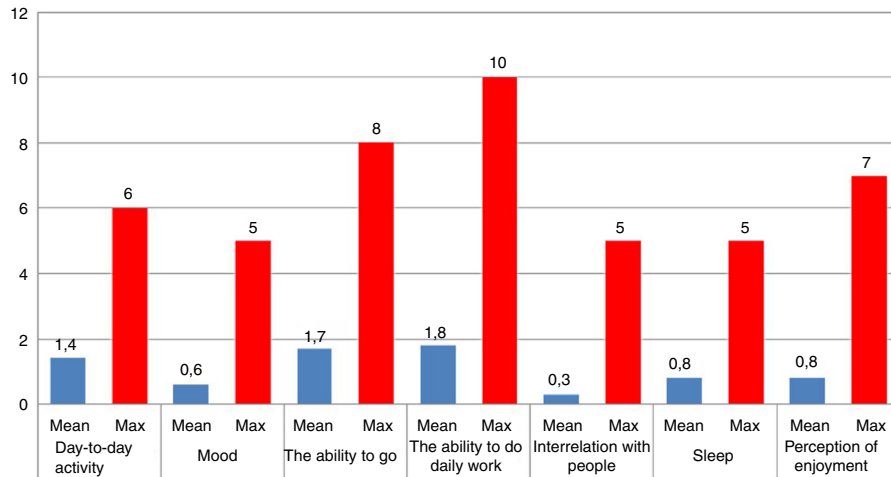


Fig. 6 – The pain assessment for day-to-day activity.

One patient underwent early repeat surgery for an adhesive small bowel obstruction. This patient underwent diagnostic laparoscopy which showed the single adhesion which was divided. The overall median length of hospital stay was 11 days (range 5–17).

## Discussion

This preliminary study outlines the first experience in Russia with the da Vinci® (Intuitive Surgical Inc., Sunnyvale CA) robotic system in rectal resection, showing that the technique is feasible and safe either in isolation or in hybrid procedures with synchronous resections. The operating times are considerable at this stage of our experience specifically for combined procedures and when single docking is used. The first robot utilized in clinical surgery was the automated endoscopic system for optimal positioning (AESOP; Computer Motion Santa Barbara CA) which in 1994 was the Zeus surgical system, originally designed as a surgical assistant. The da Vinci® system was introduced as the first telerobotic system constructed as an operative manipulator with its first use in rectal cancer excision reported by Pigazzi et al. in 2006.<sup>12</sup>

Despite its high cost, the robot has been adopted worldwide with translation to rectal cancer care usually after experience has been gained in laparoscopic rectal resection and anastomosis.<sup>13</sup> Comparative studies between laparoscopic and robotic rectal resection (specifically in rectal cancer), have shown an equivalent safety profile<sup>14–16</sup> with generally lower conversion rates to open surgery,<sup>17</sup> comparable quality of the resected TME specimens and equivalent or better circumferential and distal resection margins when the robotic method<sup>18</sup> is compared with the laparoscopic technique.<sup>1</sup> The MRC CLASSIC Trial<sup>1,19</sup> showed a higher conversion rate in the rectal laparoscopic group with a greater morbidity in those rectal cases needing open conversion. This early study highlighted the technical limitations of wholly laparoscopic surgery. In a meta-analysis of robotic rectal resection by Memon et al.,<sup>17</sup> the lower conversion rates seen in the robotic group were particularly recognized in those cases which would have represented

a greater challenge for laparoscopic resection. This was most notably in very obese patients, those who had undergone prior abdominal surgery, patients with lower rectal cancers and those undergoing resection after neoadjuvant chemoradiation.

The robotic approach overcomes some of the limitations in laparoscopic rectal surgery where straight instruments tend to encourage crowding and collision in the small working area of the pelvis and where there are limited degrees of freedom and comparatively poor ergonomics. These laparoscopic restrictions specifically can impair adequate pelvic nerve visualization with difficulties in retraction making rectal cross-stapling challenging. By contrast, the core technologies of the da Vinci® system provide a greater range of articulation with improved dexterity along with more natural hand-eye coordination, tremor filtration and a 3-dimensional stereoscopic view. In this respect, the ends of the robotic arm have an endwrist articulation permitting 7 degrees of freedom, a 180° articulation and 540° of rotation, allowing easier suturing and knot-tying than with the laparoscopic approach.<sup>20</sup> For certain surgical aspects of the procedure, however, it is accepted that there is no particular advantage over laparoscopic surgery most notably in achieving vascular control of the major pedicles. Moreover, there will be the occasional need with the robot to remove one of the arms from the LUQ during splenic flexure mobilization so as to diminish instrument collision.

As opposed to these advantages, there are several important disadvantages of the robotic technique. A lack of tactile sensation and tensile feedback may result in a higher risk of tissue damage during traction by the robotic arm and during movement of the robotic instrument. Our experience has shown that the docking and separation procedure of the robotic cart is time consuming although this is less so with the totally robotic technique, as opposed to either two- or three-phased robotic procedures<sup>10,21,22</sup> or the earlier hybrid techniques.<sup>23</sup> In general, both the total operating time and the console time diminishes after about 20 cases, however, this issue is complex where the lack of haptic sensation is an ultimate rate-limiting step for any of the robotic procedures. The learning curve for robotic surgery appears less steep than for

laparoscopic rectal surgery but it is multiphasic, where initial reductions in operative time may be countered within individual series by increases in the duration of operations once more difficult cases are performed.<sup>24,25</sup>

Any future effect on the total operating time will be indicative not only of an improved surgical proficiency (as evidenced by robotic console time) but also will reflect the efficiency of the entire operative team (as defined by robot docking time). Continued assessment of the robot in this manner will provide a better understanding of the optimal OR set-up and of measurable robot-related work processes. A graduated robotic approach will most likely influence our overall perioperative morbidity rate, although some complications such as voiding dysfunction, postoperative ileus and anastomotic leakage will not necessarily be robot-related. In this respect, our incidence of postoperative urinary difficulty was comparable to other studies<sup>26</sup> and was related to a greater ease with robotic visualization of the pelvic autonomic nerves. The influence of the robot on overall postoperative morbidity requires further assessment given that there has been no significant improvement in the complication rate over the last 20 years with laparoscopic colorectal resection.<sup>27</sup>

There are significant limitations of our study. Our data are retrospective, early and non-comparative, with only a small number of patients. We will need to significantly extend the patient numbers and experience, assessing the impact of more difficult cases and comparing different surgeons with differing levels of prior laparoscopic experience. Currently in Russia there are 24 centres nationwide which have acquired the da Vinci<sup>®</sup> system and it has been estimated that approximately 7000 robot-assisted surgeries have so far been conducted (1581 procedures performed in 2016 alone). Since 80% of these cases are urologic surgeries, 10% are gynaecological operations and 10% are general surgical, there needs to be a future rationalization of available resources and a cost analysis of the impact of the robot in dedicated centres performing high-volume colorectal surgery.<sup>28</sup> In summary, our initial experience with a totally robotic rectal resection has shown it to be safe and feasible, particularly in patients where conventional laparoscopic rectal resection would be anticipated to be challenging. Future studies will need to address the ergonomics of the OR where currently the performance of surgery with the robot in more than one anatomical area remains time consuming.

## Conflicts of interest

The authors declare no conflicts of interest.

## REFERENCES

1. Jayne DG, Guillou PJ, Thorpe H, Quirke P, Copeland J, Smith AM, et al., UK MRC CLASICC Trial Group. Randomized trial of laparoscopic-assisted resection of colorectal carcinoma: 3 year results of the UK MRC CLASICC Trial Group. *J Clin Oncol*. 2007;25:3061–8.
2. van der Pas MH, Haglind E, Cuesta MA, Fürst A, Lacy AM, Hop WC, et al., COLORECTAL cancer Laparoscopic or Open Resection II (COLOR II) Study Group. Laparoscopic versus open surgery for rectal cancer (COLOR II): short-term outcomes of a randomised, phase 3 trial. *Lancet Oncol*. 2013;14:210–8.
3. Ortiz-Oshiro E, Sánchez-Egido I, Moreno-Sierra J, Pérez CF, Díaz JS, Fernández-Represa JÁ. Robotic assistance may reduce conversion to open in rectal carcinoma laparoscopic surgery: systematic review and meta-analysis. *Int J Med Robot*. 2012;8:360–70.
4. Park SP, Kim NK. The role of robotic surgery for rectal cancer: overcoming technical challenges in laparoscopic surgery for advanced techniques. *J Korean Med Sci*. 2015;30:837–46.
5. Jiménez-Rodríguez RM, Rubio-Dorado-Manzanares M, Díaz-Pavón JM, Reyes-Díaz ML, Vazquez-Monchul JM, García-Cabrera AM, et al. Learning curve in robotic rectal cancer surgery: current state of affairs. *Int J Colorect Dis*. 2016;31:1807–15.
6. Rencuzogullari A, Gorgun E. Robotic rectal surgery. *J Surg Oncol*. 2015;112:326–31.
7. Choi DJ, Kim SH, Lee PJM, Kim J, Woo SU. Single-stage totally robotic dissection for rectal cancer surgery: technique and short-term outcome in 50 consecutive patients. *Dis Colon Rectum*. 2009;52:1824–30.
8. Jorge JM, Wexner SD. Etiology and management of fecal incontinence. *Dis Colon Rectum*. 1993;36:77–97.
9. Sprangers MA, te Velde A, Aaronson NK. The construction and testing of the EORTC colorectal cancer-specific quality of life questionnaire module (QLQ-CR38). European Organization for Research and Treatment of Cancer Study Group on Quality of Life. *Eur J Cancer*. 1999;35:238–47.
10. Hellan M, Anderson C, Ellenhorn JD, Paz B, Pigazzi A. Short-term outcomes after robotic-assisted total mesorectal excision for rectal cancer. *Ann Surg Oncol*. 2007;14:3168–73.
11. Barry MJ, Fowler FJ Jr, O'Leary MP, Bruskewitz RC, Holtgrewe HL, Mebust WK, et al. The American Urological Association symptom index for benign prostatic hyperplasia. The Measurement Committee of the American Urological Association. *J Urol*. 1992;148:1549–57.
12. Pigazzi A, Ellenhorn JD, Ballantyne GH, Pasz IB. Robotic-assisted laparoscopic low anterior resection with total mesorectal excision for rectal cancer. *Surg Endosc*. 2006;20:1521–5.
13. Baik SH. Robotic colorectal surgery. *Yonsei Med J*. 2008;49:891–6.
14. Baik SH, Kwon HY, Kim JS, Hur H, Sohn SK, Cho CH, et al. Robotic versus laparoscopic low anterior resection of rectal cancer: short-term outcome of a prospective comparative study. *Ann Surg Oncol*. 2009;16:1480–7.
15. Bianchi PP, Ceriani C, Locatelli A, Spinoglio G, Zampino MG, Sonzogni A, et al. Robotic versus laparoscopic total mesorectal excision for rectal cancer: a comparative analysis of oncological safety and short-term outcomes. *Surg Endosc*. 2010;24:2888–94.
16. Park JS, Choi G-S, Lim KH, Jang YS, Jun SH. Robotic-assisted versus laparoscopic surgery for low rectal cancer: case-matched analysis of short-term outcomes. *Ann Surg Oncol*. 2010;17:3195–202.
17. Memon S, Heriot AG, Murphy DG, Bressel M, Lynch CL. Robotic versus laparoscopic proctectomy for rectal cancer: a meta-analysis. *Ann Surg Oncol*. 2012;19:2095–101.
18. D'Annibale A, Pernazza G, Monsellato I, Pende V, Lucandri G, Mazzocchi P, et al. Total mesorectal excision: a comparison of oncological and functional outcomes between robotic and laparoscopic surgery for rectal cancer. *Surg Endosc*. 2013;27:1887–95.
19. Guillou PJ, Quirke P, Thorpe H, Walker J, Jayne DG, Smith AM, et al., MRC CLASICC trial group. Short-term endpoints of conventional versus laparoscopic-assisted surgery in patients with colorectal cancer (MRC CLASICC Trial): multicenter randomized controlled trial. *Lancet*. 2005;365:1718–26.

20. Chandra V, Nehra D, Parent R, Woo R, Reyes R, Hernandez-Boussard T, et al. A comparison of laparoscopic and robotic assisted suturing performance by experts and novices. *Surgery*. 2010;147:830-9.
21. D'Annibale A, Morpurgo E, Fiscon V, Trevisan P, Sovernigo G, Orsini C, et al. Robotic and laparoscopic surgery for treatment of colorectal diseases. *Dis Colon Rectum*. 2004;47: 2162-8.
22. Baik SH, Lee WJ, Rha KH, Kim NK, Sohn SK, Chi HS, et al. Robotic total mesorectal excision for rectal cancer using four robotic arms. *Surg Endosc*. 2008;22:792-7.
23. Spinoglio G, Summa M, Priora F, Quarati R, Testa S. Robotic colorectal surgery: first 50 cases experience. *Dis Colon Rectum*. 2008;51:1627-32.
24. Sng KK, Hara M, Shin J-W, Yoo B-E, Yang K-S, Kim S-H. The multiphasic learning curve for robot-assisted rectal surgery. *Surg Endosc*. 2013;27:3297-307.
25. Park EJ, Kim CW, Cho MS, Baik SH, Kim DW, Min BS, et al. Multidimensional analyses of the learning curve of robotic low anterior resection for rectal cancer: 3-phase learning process comparison. *Surg Endosc*. 2014;28:2821-31.
26. Kim JY, Kim NK, Lee KY, Hur H, Min BS, Kim JH. A comparative study of voiding and sexual function after total mesorectal excision with autonomic nerve preservation for rectal cancer: laparoscopic versus robotic surgery. *Ann Surg Oncol*. 2012;19:2485-93.
27. Shearer R, Gale M, Aly O, Aly E. Have early postoperative complications from laparoscopic rectal cancer surgery improved over the past 20 years? *Colorectal Dis*. 2013;15:1211-26.
28. Baek SJ, Kim SH, Cho JS, Shin JW, Kim J. Robotic versus conventional laparoscopic surgery for rectal cancer: a cost analysis from a single institute in Korea. *World J Surg*. 2012;36:2722-9.