



Original Article

Establishing the normal ranges of female and male anal canal and rectal wall vascularity with color Doppler anorectal ultrasonography



Sthela M. Murad-Regadas^{a,b,c,*}, Francisco Sergio Pinheiro Regadas^a,
Iris Daiana Dealcanfreitas^a, Francisco Sergio Pinheiro Regadas Filho^{a,c},
Graziela Olivia da S. Fernandes^a, Matheus Couto Furtado Albuquerque^a,
Carolina Murad Regadas^c, Marina Murad Regadas^c

^a Universidade Federal do Ceará (UFC), Faculdade de Medicina, Departamento de Cirurgia, Fortaleza, CE, Brazil

^b Universidade Federal do Ceará (UFC), Hospital das Clínicas, Unidade de Fisiologia Anorretal e Assoalho Pélvico, Fortaleza, CE, Brazil

^c Hospital São Carlos, Departamento de Cirurgia Colorretal, Unidade de Fisiologia Anorretal e Assoalho Pélvico, Fortaleza, CE, Brazil

ARTICLE INFO

Article history:

Received 1 March 2018

Accepted 26 March 2018

Available online 30 April 2018

Keywords:

Anal canal vascularization

Rectum vascularization

Color-doppler

Endoanal ultrasound

Endorectal ultrasound

ABSTRACT

Study objectives: To evaluate blood supply in the anal canal, rectal wall and mesorectal fat of men and women, using color Doppler endorectal sonography to establish normal ranges for vascular parameters.

Methods: A prospective cross-sectional study conducted at a tertiary-care hospital recruited asymptomatic volunteers (≤ 50 years). Vascularity percentage and index were calculated for defined regions.

Results: Vascularity percentage and index were significantly higher in the puborectalis, mid-level external and upper internal anal sphincter compared to the low anal canal; these parameters were higher in men than in women at upper and middle levels of the inner anal canal structures. At mid-level, vascularity was greater in the external compared to the internal anal sphincter in both sexes; however, at the upper level it was greater in the puborectalis compared to the internal anal sphincter in women. Vascularity was greater in the rectal wall compared to the mesorectal fat, with no difference between middle and lower levels.

* Corresponding author.

E-mail: smregadas@hospitalsaocarlos.com.br (S.M. Murad-Regadas).

<https://doi.org/10.1016/j.jcol.2018.03.005>

2237-9363/© 2018 Sociedade Brasileira de Coloproctologia. Published by Elsevier Editora Ltda. This is an open access article under the CC BY-NC-ND license (<http://creativecommons.org/licenses/by-nc-nd/4.0/>).

Conclusions: Blood supply is highest at upper levels of the anal canal; however, inner structures are better irrigated in men. Moreover, the rectal wall is better irrigated than the mesorectal fat. Establishing normal ranges may permit future comparisons of the studied structures in disease states as well as the hormonal and age related changes.

© 2018 Sociedade Brasileira de Coloproctologia. Published by Elsevier Editora Ltda. This is an open access article under the CC BY-NC-ND license (<http://creativecommons.org/licenses/by-nc-nd/4.0/>).

Estabelecendo padrões normais da vascularização do canal anal e da parede retal em indivíduos do sexo masculino e feminino com ultrassom anorretal com Doppler colorido

R E S U M O

Palavras-chave:

Vascularização do canal anal
Vascularização do reto
Doppler colorido
Ultrassom endoanal
Ultrassom endorretal

Objetivo: Avaliar vascularização do canal anal, parede retal e gordura mesorretal em homens e mulheres, usando ultrassonografia endorretal com Doppler colorido para estabelecer parâmetros vasculares de normalidade.

Métodos: Estudo prospectivo transversal incluindo voluntários assintomáticos com até 50 anos. Medidos os valores da porcentagem e do índice de vascularização foram calculados para regiões escolhidas.

Resultados: Valores da porcentagem e do índice foram significativamente maiores no puborretal, esfíncter externo (canal anal médio) e o esfíncter interno (canal anal superior) comparado ao canal anal inferior; esses parâmetros foram maiores em homens que em mulheres no canal anal médio e alto. No médio, a vascularização foi maior no esfíncter externo comparado ao interno em ambos os sexos; contudo, no canal anal superior, foi maior no puborretal comparado ao esfíncter anal interno em mulheres. A vascularização foi maior na parede retal comparada à gordura mesorretal, sem diferenças entre os níveis.

Conclusões: O suprimento sanguíneo é maior nos níveis altos do canal anal. As estruturas internas são mais irrigadas nos homens. A parede retal é mais irrigada que a gordura mesorretal. Os parâmetros vasculares estabelecidos permitirá futuras comparações das estruturas estudadas nos casos de doenças, assim como, alterações que ocorrem com a idade e mudanças hormonais.

© 2018 Sociedade Brasileira de Coloproctologia. Publicado por Elsevier Editora Ltda. Este é um artigo Open Access sob uma licença CC BY-NC-ND (<http://creativecommons.org/licenses/by-nc-nd/4.0/>).

Introduction

Ultrasonography enables visualization of the anatomical and functional aspects of the anal canal and rectum and is a well-established tool for evaluating benign, malignant, and functional disorders. Numerous studies have shown good correlation between ultrasound imaging and surgical findings.¹⁻⁸ Ultrasound can also be used to assess vascularity, and several studies have evaluated the efficacy of intrarectal ultrasound with color Doppler and Doppler flow analysis in detecting possible differences in blood flow patterns between malignant⁹⁻¹¹ and benign¹²⁻¹⁴ anal canal and rectal diseases. Although color Doppler ultrasound has been used to evaluate tissue changes, to our knowledge no data are available concerning normal vascularization in the anal canal and rectal wall.

It is known that the anal canal and rectal wall differ from each other in anatomic structures and in blood vessel supply and distribution. The purpose of this study was to use 360° color Doppler endorectal ultrasonography to determine normal ranges for vascular parameters at different levels of the female and male anal canal, rectal wall, and mesorectal fat

in order to provide reference values that can facilitate future comparisons of anal canal structures in disease states.

Subjects and methods

Subjects

Consecutive asymptomatic volunteers (aged ≤ 50 years) were recruited among employees at two academic hospitals in Fortaleza (Clinical Hospital of the Federal University of Ceará and São Carlos Hospital). The clinical protocol was approved by the Research Ethics Committee of the Walter Cantídio University Hospital, and all subjects gave written informed consent.

Prospective subjects were evaluated clinically and underwent a physical examination which included digital examination and assessment for pelvic organ prolapse according to the Pelvic Organ Prolapse Quantification system (POP-Q) in women.¹¹ Men and nulliparous women were included if they had no anal canal, rectal, or urinary disorders. Women were included if their POP-Q status was stage 0. Subjects with fecal incontinence, constipation, urinary symptoms,

inflammatory bowel disease, Human Immunodeficiency Virus (HIV), anal sphincter injury, a history of colorectal or proctological surgery, or vaginal delivery were excluded.

Endorectal ultrasonography

All subjects underwent 360° color Doppler endorectal ultrasonography (5–7 MHz). A Doppler 360° radial-array endorectal ultrasound transducer (Hitachi-Aloka EUP-R54AW-33, Hitachi Medical Systems, Tokyo, Japan) was used with a Hi Vision Avius Ultrasound System (Hitachi).

Subjects were examined in the left lateral position after administration of a rectal enema (completed 2 h before scanning). After digital rectal examination, the endoprobe was introduced into the anal canal and the rectum. The vascular patterns of the anal canal and rectum were acquired in color Doppler mode.

Assessments

To define vascular parameters and assess potential differences among various levels and structures, the anal canal and rectum were divided into different manually delineated regions of interest. The anal canal region was divided into 3 levels (upper, middle, and low anal canal) at 2 depths (outer and inner structures). The outer structures included the puborectalis plus longitudinal muscle at the upper level, the External Anal Sphincter (EAS) plus longitudinal muscle at the middle level, and the EAS at the lower level. The inner (deeper) structures included the Internal Anal Sphincter (IAS) plus the subepithelial tissues at both the upper and middle levels (Figs. 1–3).

The regions of interest for the rectum included the rectal wall and mesorectal fat at 2 positions: 5–6 cm (low) and 8–9 cm (middle) from the anal verge (Fig. 4).

The system automatically calculated the vascularity percentage and vascularity index within each region of interest. Vascularity percentage was defined as the percentage of pixels within the region of interest that showed a color Doppler signal of any intensity (indicating the presence of blood flow). Vascularity index was defined as the mean power of each pixel within the region of interest.

The system also automatically calibrated distances and color hues as flow velocities and calculated the color pixel area and flow velocity – encoded by each pixel – inside each region of interest. The same setup of color Doppler mode was used for all participants (Pulse Repetition Frequency [PRF] = 0.5; gain = 50%; velocity = 3.3 cm/s).

The structures were traced manually at each level and the device automatically measured the vascular parameters twice, calculated the mean, and made comparisons by level, structure, and sex.

Statistical analysis

The anatomic structures were compared according to level, depth, and sex and with regard to vascularity percentage and index. Differences between groups were assessed by means of the Student *t* test for continuous data. The level of statistical significance was set at $p < 0.05$.

Data were analyzed using SPSS software (version 14.0 for Windows; IBM-SPSS, Chicago, IL).

Results

Subject characteristics

Between August 2012 and February 2013, a total of 31 volunteer subjects consented to participate in this study. Of these, 31 subjects met inclusion criteria and were enrolled in the study. The study population included 15 women, with a mean age of 31 (SD = 6.4; range 23–47 years), and 16 men, with a mean age of 38 (SD = 7.4; range 27–48 years).

Anal canal

Table 1 presents the vascular parameters for the outer and inner structures of the anal canal at 3 levels (upper, middle, and low) in women and men.

Women

Evaluation of the outer structures of the anal canal in women showed significantly higher mean vascular percentage and vascular index values in the puborectalis (upper level) and in the mid-level EAS than in the EAS at the lower level, but there was no difference between the puborectalis and the EAS at the middle level. Evaluation of the inner structures at the upper and middle levels showed that the vascular percentage and index for the IAS were significantly higher at the upper level than at the middle level. Comparison of the outer and inner structures showed that both vascular percentage and index were significantly higher in the puborectalis than in the upper IAS and also significantly higher in the mid-level EAS than in the mid-level IAS.

Men

As in women, assessment of the outer structures of the anal canal in men showed that the vascular percentage and index were both significantly higher in the puborectalis and in the mid-level EAS than in the low EAS, but no difference was observed between the puborectalis and the mid-level EAS. Of the inner structures in men, the IAS had significantly higher mean vascularity percentage and index values at the upper level than at the middle level. In contrast to women, men showed no difference in vascularity percentage between the puborectalis and the upper IAS. However, as in women, the vascularity index in men was significantly higher in the puborectalis than in the upper IAS. Both vascularity percentage and index were significantly higher in the mid-level EAS than in the mid-level IAS.

Comparisons between men and women

No significant differences were found between men and women regarding either vascularity percentage or index in any of the outer anal canal structures. However, men had higher values for both vascularity percentage and index at the upper and middle levels of the inner anal canal structures.

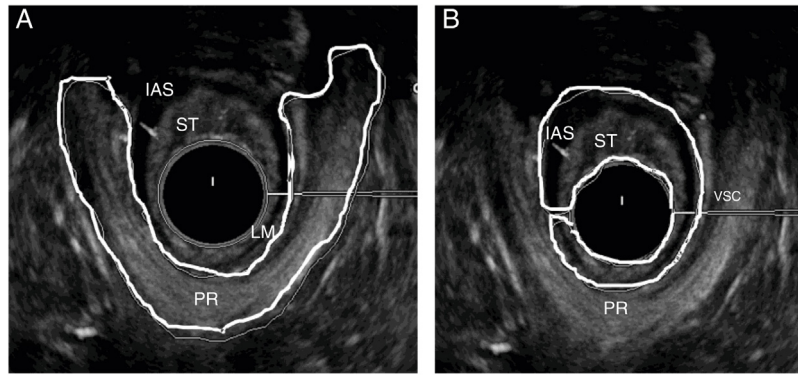


Fig. 1 – Female anal canal – upper anal canal – regions of interest. PR, puborectal; LM, longitudinal muscle; IAS, internal anal sphincter; ST, subepithelial tissues. (A) Outer structures; (B) Inner structures.

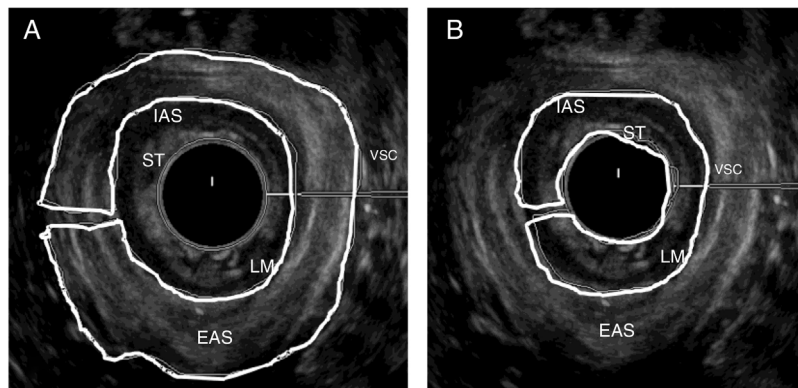


Fig. 2 – Female anal canal – middle anal canal – regions of interest. EAS, external anal sphincter; LM, longitudinal muscle; IAS, internal anal sphincter; ST, subepithelial tissues. (A) Outer structures; (B) Inner structures.

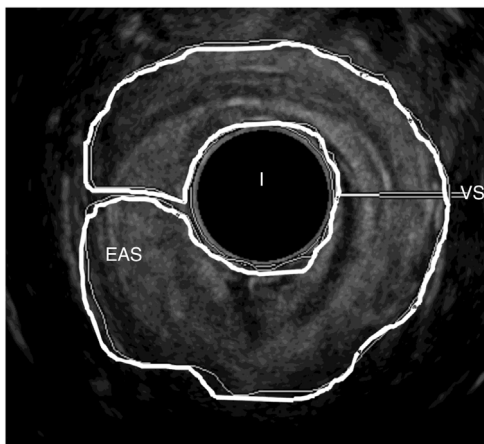


Fig. 3 – Female anal canal – low anal canal – region of interest – outer structures.

Rectum and mesorectal fat

Table 2 presents the vascular parameters for the rectum and the mesorectum at the middle and low levels.

Women

The mean vascularity percentage and index were significantly higher in the rectal wall than in the mesorectal fat at both the middle and low levels. However, no differences in vascularity percentage or index were observed between middle and low levels of either the rectal wall or the mesorectal fat.

Men

As in women, the mean vascularity percentage and index in men were both significantly higher in the rectal wall than in the mesorectal fat at low and middle positions, and no significant differences were seen in vascularity percentage or index in comparisons of middle vs low levels of the rectal wall or of mesorectal fat.

Comparisons between men and women

No significant differences were found between men and women regarding vascularity of the rectal wall or mesorectal fat at either middle or low levels.

Discussion

Treatment of anorectal disorders requires extensive knowledge of anatomy. Detailed evaluation of vascularity may be important for understanding the pathophysiology of

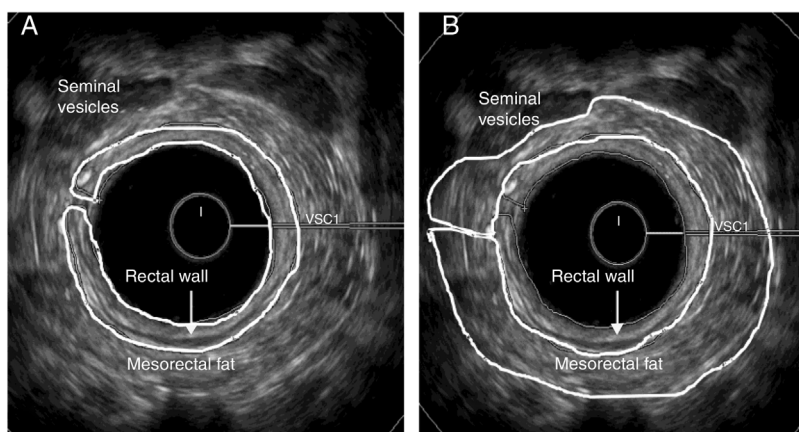


Fig. 4 – Male anal canal – middle position – regions of interest. (A) Rectal wall; (B) Mesorectal fat.

Table 1 – Vascularity percentage and vascularity index for the outer and inner structures of the anal canal at 3 levels (upper, middle, and low) in women and men.

	Vascularity %		Vascularity index	
	Women (n = 14)	Men (n = 16)	Women (n = 14)	Men (n = 16)
<i>Outer structures, mean ± SD (range)</i>				
Upper-level PR + LM	6.0 ± 2.2 ^a (3.1–10.7)	6.4 ± 2.6 ^a (2.6–10.3)	0.29 ± 0.19(0.12–0.71)	0.25 ± 0.17(0.05–0.61)
Mid-level EAS + LM	5.0 ± 2.4 ^a (1.8–8.9)	6.0 ± 1.6 ^a (3.3–7.7)	0.27 ± 0.18(0.12–0.71)	0.28 ± 0.14(0.07–0.53)
Lower-level EAS	2.4 ± 1.2 ^a (0.7–4.7)	3.2 ± 1.9 ^a (0.6–6.1)	0.06 ± 0.03(0.01–0.13)	0.09 ± 0.07(0.01–0.26)
<i>Comparison by level (p)</i>				
Upper-level PR vs. mid-level EAS	0.29	0.66	0.10	0.72
Upper-level PR vs. lower-level EAS	0.0001	0.007	0.0009	0.01
Mid-level EAS vs. lower-level EAS	0.005	0.002	0.0009	0.002
<i>Inner structures, mean ± SD (range)</i>				
Upper-level IAS + SE	3.7 ± 2.7 ^b (0.8–8.1)	6.6 ± 2.9 ^b (1.5–10.9)	0.30 ± 0.30(0.02–0.79)	0.76 ± 0.52(0.09–1.80)
Mid-level IAS + SE	0.6 ± 0.4 ^c (0.1–1.1)	2.0 ± 1.7 ^c (0.2–4.8)	0.03 ± 0.04(0.0–0.11)	0.14 ± 0.17(0.0–0.49)
<i>Comparison by level (p)</i>				
Upper IAS vs. mid IAS	0.001	0.001	0.01	0.01
<i>Outer vs. inner structures (p)</i>				
Upper-level PR vs. upper-level IAS	0.04	0.84	0.01	0.01
Mid-level EAS vs. mid-level IAS	0.0001	0.0001	0.0003	0.03

PR, Puborectalis; LM, Longitudinal Muscle; EAS, External Anal Sphincter; IAS, Internal Anal Sphincter; SE, Subepithelial Tissues.

^a No significant difference between men and women: $p > 0.05$.

Significantly higher in men than in women:

^b $p = 0.02$.

^c $p = 0.01$.

^d $p = 0.048$.

such disorders in order to choose the best methods of treatment. Various Doppler techniques have been used to understand distribution of vascularity in benign and malignant disorders.⁹⁻¹⁵ This is the first report using 360° color Doppler anorectal ultrasonography to assess the vascularity of structures at different levels of the anal canal, rectum, and mesorectal fat. The advantage of this technique is that it makes it possible to measure vascularity circumferentially instead of by quadrant. The 360° endoluminal approach clearly identified and enabled quantitative assessment of vascular parameters for inner and outer anatomic structures at upper, mid, and low levels of the anal canal, and at middle and low levels of the rectal wall and mesorectal fat.

Because the participants were asymptomatic volunteers aged up to 50 years, the study provides reference values for these areas. There was a very large variation in the normal ranges for all measurements. In both sexes, the greatest degree of vascularity was found at the upper levels of the anal canal and least in the low anal canal. Compared with the upper levels, the low anal canal requires only a modest blood supply and many of its blood vessels are small in diameter. We also analyzed the anal canal according to the functions of the muscles in the outer structures, including the longitudinal muscle, puborectalis, and EAS (voluntary muscles), as well as the inner structures, including subepithelial tissues and the IAS (a smooth muscle in a state of continuous maximal contraction,

Table 2 – Vascularity percentage and vascularity index measured in the rectal wall and mesorectal fat at 2 levels (middle and lower) in women and men.

	Vascularity %		Vascularity index	
	Women (n = 14)	Men (n = 16)	Women (n = 14)	Men (n = 16)
<i>Middle level, mean ± SD (range)</i>				
Rectal wall	10.9 ± 8.3 ^a (4.0–29.7)	12.2 ± 7.0 ^a (1.9–24.0)	1.59 ± 1.37 (0.39–5.46)	1.74 ± 0.98 (0.14–3.27)
Mesorectal fat	4.1 ± 3.2 ^a (0.4–9.6)	4.6 ± 2.6 ^a (1.1–9.6)	0.37 ± 0.27 (0.03–0.73)	0.59 ± 0.34 (0.20–1.30)
Rectal wall vs. mesorectal fat	0.01	0.0008	0.006	0.0003
<i>Lower-level, mean ± SD (range)</i>				
Rectal wall	12.8 ± 7.0 ^a (2.2–22.3)	11.4 ± 7.2 ^a (1.1–23.5)	1.52 ± 1.27 (0.28–4.21)	1.72 ± 1.23 (0.09–3.60)
Mesorectal fat	5.9 ± 4.1 ^a (0.5–12.6)	4.0 ± 3.3 ^a (0.2–10.5)	0.52 ± 0.57 (0.04–2.11)	0.51 ± 0.58 (0.01–2.20)
Rectal wall vs. mesorectal fat	0.01	0.002	0.02	0.003
<i>Comparison by level (p)</i>				
Mid vs. lower rectal wall	0.7	0.78	0.9	0.96
Mid vs. lower mesorectal fat	0.25	0.62	0.45	0.68

^a No significant difference between men and women: $p > 0.05$.

representing a natural barrier to the involuntary loss of stool and gas). In both sexes, greater vascularity was found in the outer structures of the upper and mid-level anal canal than in the inner structures, reflecting requirements for a large supply of blood in the outer structures, possibly because they contain striated muscles, which are thicker than smooth muscles.

Previous studies have shown that anal canal muscles (both striated and smooth muscles) are longer in men than in women. We found greater vascularity at the upper and middle levels of the inner anal canal structures in men compared with women. However no differences were found between the sexes regarding vascularity of the middle or low rectal wall or mesorectal fat. Vascularity was greater in the rectal wall than in the mesorectal fat at both levels and in both sexes. Despite its thinner rectal layer, the rectal wall requires a large blood supply and has many high-diameter blood vessels.

One limitation of this method is the necessity for manual delineation of the region of interest. However, the image has high resolution and is therefore able to easily identify the anatomic structures and muscles in order to assess vascularity. Future development of the method may enable 3D/4D analysis of the vascular distribution and quantitative volumetric assessment of the vessel network. In the meantime, because the Doppler 360° endorectal ultrasound is a relatively new technique, further studies should compare it with the use of different ultrasound methods, such as transperineal or transvaginal techniques.

Application of 360° color Doppler endorectal ultrasonography can be useful in many different situations. For example, patients with hemorrhoids should be investigated with this method. Changes in the vascularity of inner and outer structures may correlate with the results of treatment, making it possible to demonstrate the efficacy of different surgical techniques.^{14,15} In another application, Drudi et al.¹⁰ compared the ability of gray-scale transrectal ultrasound with that of color Doppler imaging to differentiate between post-radiation fibrosis and residual tumor or local relapse. Color Doppler increased the specificity of transrectal ultrasound in differentiating tumor relapse from fibrosis, demonstrating its value in the evaluation of carcinoma of the anal canal, both in the pre-therapeutic stage and during follow-up, when color

Doppler-guided biopsy should be preferred to ultrasound-guided biopsy.

New research should evaluate some of the factors that could affect the Doppler flow spectrum in the anal canal and rectum, for example, previous studies have demonstrated the influence of factors such as sex hormones, aging, parity, body mass index, and menopause on the vascularity of various structures.¹⁶ Oliveira et al.¹² evaluated the Doppler velocimetric parameters of the levator ani muscle vessels in premenopausal women with and without urinary stress incontinence and found that Doppler velocimetric differences in the levator ani muscle vessels might be due to hormonal status. Jármy-Di Bella et al.¹⁷ used Doppler velocimetric analysis to investigate the effect of hormone therapy in periurethral vessels and demonstrated that hormonal therapy of short duration had a positive effect on the urethral continence mechanism, increasing the number of periurethral vessels.

A further study in patients with symptoms of fecal incontinence and/or obstructed defecation syndrome with perineal descent should be conducted to investigate vascular parameters in such patients and to identify any risk factors that could negatively affect treatment outcome. A previous study¹⁸ demonstrated that pregnancy and labor may lead to perineal trauma, deterioration of vascular supply, and nerve function in the pelvic floor area, thereby impairing urinary continence, but no correlation with fecal incontinence was found.

It would also be interesting to study a group of patients with inflammatory disease, because a previous investigation¹⁹ using power Doppler abdomen sonography has shown a correlation between bowel wall vascularity and disease activity in patients with confirmed Crohn's disease. The authors suggested that power Doppler abdomen ultrasound may be able to monitor activity changes of the bowel wall caused by pharmaceutical treatment. A further study should be conducted to investigate the relationship between anal canal vascularity and disease activity in patients with perianal Crohn's disease.

The usefulness of endorectal Doppler sonographic analysis of rectal tumor vascularization before and after preoperative radiotherapy has also been described in the literature. Barbaro et al.²⁰ used color Doppler ultrasound to study the relationship between the vasculature supplying blood flow

to rectal cancer and response to a neoadjuvant regimen in patients with rectal cancer. Homogeneous vascularity and low pulsatility index values from arterial signals sampled from the peripheral portion of rectal masses were positive indicators of therapy outcome. Ogura et al.⁹ suggested that the intratumoral vascular point index as assessed by transanal color Doppler ultrasonography is better than conventional immunohistochemical analysis as a preoperative indicator of angiogenesis and may also be a predictor for hematogenous metastasis in rectal carcinoma.

In conclusion, the degree of vascularity varies among the different levels and structures of the anal canal. Blood supply is highest at upper levels of outer and inner structures of the anal canal in both men and women, but inner structures are better supplied in men than in women. In both sexes, the rectal wall is better supplied than in mesorectal fat. Considering these variations, the normal ranges determined in this study using 360° color Doppler ultrasonography may facilitate future comparisons of anal canal and rectal structures in disease states, as well as, the hormonal and age related changes.

Compliance with ethical standards

The Institutional Review Board of the Walter Cantídio University Hospital approved the study protocol and all subjects gave their written informed consent.

Conflicts of interest

The authors declare no conflicts of interest.

REFERENCES

- Nielsen MB, Hauge C, Pedersen JF, Christiansen J. Endosonographic evaluation of patients with anal incontinence: findings and influence on surgical management. *Am J Roentgenol*. 1993;160:771–5.
- West RL, Dwarkasing S, Felt-Bersma RJ, Schouten WR, Hop WC, Hussain SM, et al. Hydrogen peroxide-enhanced three-dimensional endoanal ultrasonography and endoanal magnetic resonance imaging in evaluating perianal fistulas: agreement and patient preference. *Eur J Gastroenterol Hepatol*. 2004;16:1319–24.
- Christensen AF, Nielsen MB, Engelholm SA, Roed H, Svendsen LB, Christensen H. Three-dimensional anal endosonography may improve staging of anal cancer compared with two-dimensional endosonography. *Dis Colon Rectum*. 2004;47:341–5.
- Murad-Regadas SM, Regadas FS, Rodrigues LV, Barreto RG, Monteiro FC, Landim BB, et al. Role of three-dimensional anorectal ultrasonography in the assessment of rectal cancer after neoadjuvant radiochemotherapy: preliminary results. *Surg Endosc*. 2009;23:1286–91.
- Regadas FS, Murad-Regadas SM, Lima DM, Silva FR, Barreto RG, Souza MH, et al. Anal canal anatomy showed by 3-dimensional anorectal ultrasonography. *Surg Endosc*. 2007;21:2207–11.
- Regadas FS, Haas EM, Abbas MA, Marcio Jorge J, Habr-Gama A, Sands D, et al. Prospective multicenter trial comparing echodefecography with defecography in the assessment of anorectal dysfunction in patients with obstructed defecation. *Dis Colon Rectum*. 2011;54:686–92.
- Murad-Regadas SM, Regadas FS, Rodrigues LV, Holanda EC, Barreto RG, Oliveira L. The role of 3-dimensional anorectal ultrasonography in the assessment of anterior transsphincteric fistula. *Dis Colon Rectum*. 2010;53:1035–40.
- Vitton V, Vignally P, Barthet M, Cohen V, Durieux O, Bouvier M, et al. Dynamic anal endosonography and MRI defecography in diagnosis of pelvic floor disorders: comparison with conventional defecography. *Dis Colon Rectum*. 2011;54:1398–404.
- Ogura O, Takebayashi Y, Sameshima T, Maeda S, Yamada K, Hata K, et al. Preoperative assessment of vascularity by color Doppler ultrasonography in human rectal carcinoma. *Dis Colon Rectum*. 2001;44:538–46.
- Drudi FM, Giovagnorio F, Raffetto N, Ricci P, Cascone F, Santarelli M, et al. Transrectal ultrasound color Doppler in the evaluation of recurrence of anal canal cancer. *Eur J Radiol*. 2003;47:142–8.
- Tankova LT, Penchev PI, Kovatchki D, Stoilov G, Hadjieva T. Endosonographic assessment of rectal cancer after neoadjuvant radiotherapy. *Med Ultrason*. 2012;14:19–23.
- Oliveira E, Castro RA, Takano CC, Bezerra LR, Sartori MG, Lima GR, et al. Ultrasonographic and Doppler velocimetric evaluation of the levator ani muscle in premenopausal women with and without urinary stress incontinence. *Eur J Obstet Gynecol Reprod Biol*. 2007;133:213–7.
- Kobata SA, Girão MJ, Baracat EC, Kajikawa M, Di Bella V Jr, Sartori MG, et al. Estrogen therapy influence on periurethral vessels in postmenopausal incontinent women using Dopplervelocimetry analysis. *Maturitas*. 2008;61:243–7.
- Miyamoto H, Asanoma M, Miyamoto H, Takasu C, Masamune K, Shimada M. Visualization and hypervascularization of the haemorrhoidal plexus in vivo using power Doppler imaging transanal ultrasonography and 3-dimensional power Doppler angiography. *Colorectal Dis*. 2013;15:e686–91.
- Miyamoto H, Asanoma M, Miyamoto H, Takasu C, Shimada M. Three-dimensional power Doppler transanal ultrasonography, to monitor haemorrhoidal blood flow after Doppler-guided ALTA sclerosing therapy. *Colorectal Dis*. 2013;15:e84–8.
- Miodrag A, Castleden CM, Vallance TR. Sex hormones and the female urinary tract. *Drugs*. 1988;36:491–504.
- Jármy-Di Bella ZI, Girão MJ, Di Bella V, Sartori MG, Szejnfeld J, Baracat EC, et al. Hormonal influence on periurethral vessels in postmenopausal incontinent women using Doppler velocimetry analysis. *Maturitas*. 2007;56:297–302.
- Lien KC, Mooney B, DeLancey JO, Ashton-Miller JA. Levator ani muscle stretch induced by simulated vaginal birth. *Obstet Gynecol*. 2004;103:31–40.
- Drews BH, Barth TF, Hänle MM, Akinli AS, Mason RA, Muche R, et al. Comparison of sonographically measured bowel wall vascularity, histology, and disease activity in Crohn's disease. *Eur Radiol*. 2009;19:1379–86.
- Barbaro B, Valentini V, Coco C, Mancini AP, Gambacorta MA, Vecchio FM, et al. Tumor vascularity evaluated by transrectal color Doppler US in predicting therapy outcome for low-lying rectal cancer. *Int J Radiat Oncol Biol Phys*. 2005;63:1304–8.