



Journal of Coloproctology

www.jcol.org.br



Case Report

A case study of ileal metaplasia and neoplasia in a patient with an ileal-rectal anastomosis



Beth M. Campbell^{a,b,*}, David Clark^a, James Harvey^a, Andrew Reid^{b,c}

^a Royal Brisbane and Women's Hospital, Herston, Australia

^b The University of Queensland, Brisbane, Australia

^c Pathology Queensland, Herston, Australia

ARTICLE INFO

Article history:

Received 27 September 2017

Accepted 10 December 2017

Available online 12 February 2018

Keywords:

Ulcerative colitis

Colectomy

Follow-up

Neoplasms

ABSTRACT

A clear link between ulcerative colitis and the formation of dysplasia and neoplasia has been described. This increased risk remains even after subtotal colectomy and ileo-rectal anastomosis, necessitating life-long surveillance of the remaining ano-rectum. This case study highlights the importance in long-term follow up in this population, including proximal to the anastomosis as dysplastic changes can occur in the distal ileum.

Crown Copyright © 2018 Published by Elsevier Editora Ltda. on behalf of Sociedade Brasileira de Coloproctologia. This is an open access article under the CC BY-NC-ND license (<http://creativecommons.org/licenses/by-nc-nd/4.0/>).

Um caso de estudo de metaplasia ileal e neoplasia em paciente com anastomose ileal-retal

RESUMO

Uma ligação clara entre colite ulcerativa e a formação de displasia e neoplasia tem sido descrita. Esse risco aumentado permanece mesmo após colectomia subtotal e ileo-retal, necessitando de uma vigilância ao longo da vida do ano-recto restante. Este caso de estudo realça a importância no acompanhamento a longo prazo dessa população, incluindo áqueles próximos à anastomose já que podem ocorrer alterações displásicas no íleo distal.

Crown Copyright © 2018 Publicado por Elsevier Editora Ltda. em nome de Sociedade Brasileira de Coloproctologia. Este é um artigo Open Access sob uma licença CC BY-NC-ND (<http://creativecommons.org/licenses/by-nc-nd/4.0/>).

Palavras-chave:

Colite ulcerativa

Colectomia

Seguimento

Neoplasias

* Corresponding author.

E-mail: Beth.Campbell2@health.qld.gov.au (B.M. Campbell).

<https://doi.org/10.1016/j.jcol.2017.12.006>

2237-9363/Crown Copyright © 2018 Published by Elsevier Editora Ltda. on behalf of Sociedade Brasileira de Coloproctologia. This is an open access article under the CC BY-NC-ND license (<http://creativecommons.org/licenses/by-nc-nd/4.0/>).

Case report

A 60-year-old female presented for endoscopic surveillance of her rectum and ileorectal anastomosis (IRA). She was diagnosed with ulcerative colitis (UC) at age 25 and underwent an open subtotal colectomy and IRA following failure of twelve months of medical therapy. She had not received follow up following this due to anxiety and unwillingness to undergo further endoscopy or surgeries. She was referred by her GP with loose and frequent bowel motions (5-7 times per day), faecal incontinence and urgency.

Endoscopy revealed high-grade dysplasia in the rectum with evidence of chronic inflammation affecting the distal ileum. The appearance was consistent with ulcerative colitis and a restorative proctectomy and ileal J pouch was performed. Histopathology demonstrated two distinct foci of malignancy. A moderately differentiated mucinous adenocarcinoma (T3N1M0) was seen at the ileorectal anastomosis with invasion to the pericolic fatty tissue (Fig. 1). Tumour was present within 1.9 mm of the circumferential margin. The ileum showed high-grade polypoid adenoma-like dysplasia with evidence of colonic cell metaplasia (Fig. 2). Lymphoid aggregates were prominent.

Discussion

Increased incidence of colorectal cancer is well described in UC. Risk increases with prolonged duration of disease, presence of pancolitis and concomitant primary sclerosing cholangitis. Subtotal colectomy with ileorectal anastomosis was first performed in the 1940s as the only surgical alternative to permanent ileostomy in patients with medically refractory UC.¹ In 1978 Parks et al. described an ileal pouch anal anastomosis (IPAA).² This procedure has since become the treatment of choice for some patients with UC and familial adenomatous polyposis (FAP).

The risk of dysplasia and colorectal cancer following IRA is considerably higher than in IPAA. Da La Moreira reported the incidence of malignancy following IRA as 0%, 2%, 5% and 14% at 5, 10, 15 and 20 years respectively.³ Tumours identified

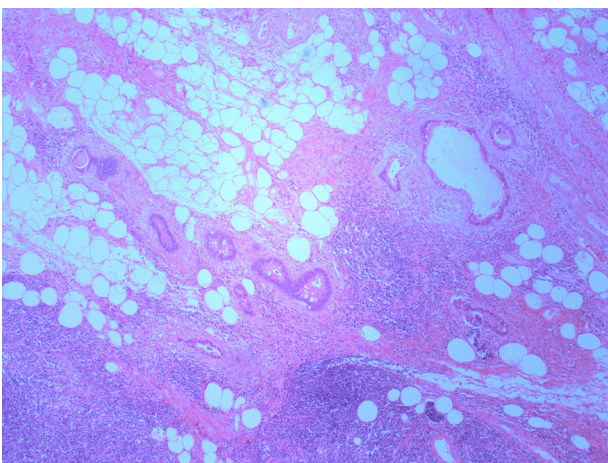


Fig. 1 – Mucinous adenocarcinoma: pericolic fat invasion.

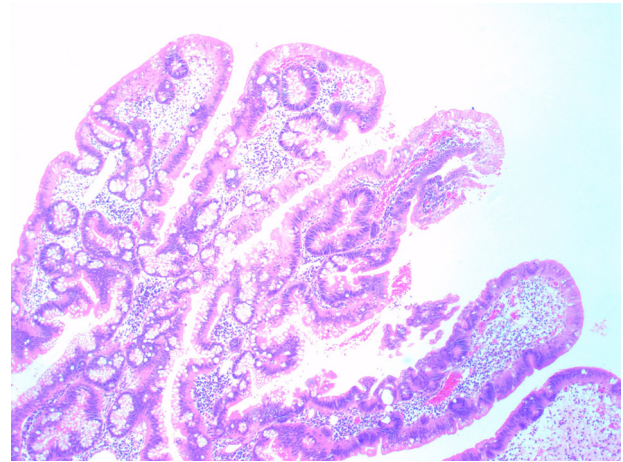


Fig. 2 – Polypoid adenoma-like dysplasia and colonic cell metaplasia.

in these patients frequently present at an advanced stage (III-IV), with Baker et al. reporting that 62% of patients died within three years of diagnosis.⁴

Colonic metaplasia and rarely malignancy are described in the ileal pouches of patients with IPAA. This may occur as a result of chronic pouchitis. While the aetiology behind these changes remains unclear, a number of mechanisms have been proposed. These include altered bacterial flora, stasis of the faecal stream in the pouch and presence of short-chain fatty acids. Histological changes include villous flattening, proliferation of Goblet cells and change in mucin type from sialomucin to sulphomucin.⁵ These changes occur more commonly in patients with UC than FAP, suggesting that the underlying inflammatory nature of the UC disease plays a role.⁶

Some degree of chronic inflammation is evident in virtually all pouches without clinical pouchitis.^{7,8} The association with pouchitis in IPAA and subsequent necessity or frequency of surveillance is less clear. One study of 3203 patients found pouch neoplasia or dysplasia in 38 patients over 25 years.⁹ This included not only adenocarcinoma of the pouch and/or the transition zone, but also squamous cell carcinoma and lymphoma. Pouchitis has been shown to significantly increase the risk of low-grade dysplasia progressing to high-grade dysplasia.

Biancone explored whether these inflammatory changes occur in the ileum proximal to IRA anastomoses. They identified histological change towards colonic epithelium in the neo-terminal ileum. These changes included increased expression of the colonic epithelial antigen human tropomyosin isoform 5 (hTM5). The authors cautioned that patients with IRA need endoscopic assessment not only for cancer surveillance but also for assessing the possible development of ileal lesions above the anastomosis.¹⁰ We describe such a lesion.

The role of IRA in ulcerative colitis is controversial but may be beneficial in carefully selected patient subsets. IRA patients generally experience a lower post-operative morbidity than IPAA. Specifically IPAA conveys a higher rate of infertility,

pelvic sepsis, pelvic nerve damage and portal vein thrombosis. Operating time for IRA is also shorter. Andersson suggests that IRA may still be of value in young patients where sexual function or fertility is important. A definitive procedure is usually anticipated in the medium term.¹¹ In such cases, the need to exclude dysplasia or malignancy prior to definitive surgery is essential. Patient understanding regarding the importance of follow up cannot be understated. This case emphasizes the importance of careful patient selection prior to IRA and importance of regular endoscopic surveillance.

Conflicts of interest

The authors declare no conflicts of interest.

REFERENCES

1. Devine H, Devine J. Subtotal colectomy and colectomy in ulcerative colitis. *Br Med J*. 1948;2:127–31.
2. Parks AG, Nicholls RJ. Proctocolectomy without ileostomy for ulcerative colitis. *Br Med J*. 1978;2:85–8.
3. da Luz Moreira A, Kiran RP, Lavery I. Clinical outcomes of ileorectal anastomosis for ulcerative colitis. *Br J Surg*. 2010;97:65–9.
4. Baker WN, Glass RE, Ritchie JK, Aylett SO. Cancer of the rectum following colectomy and ileorectal anastomosis for ulcerative colitis. *Br J Surg*. 1978;65:862–8.
5. de Silva HJ, Millard PR, Kettlewell M, Mortensen NJ, Prince C, Jewell DP. Mucosal characteristics of pelvic ileal pouches. *Gut*. 1991;32:61–5.
6. Back SP, Mortensen NJ. Ileal pouch surgery for ulcerative colitis. *World J Gastroenterol*. 2007;13:3288–300.
7. Moskowitz RL, Shepherd NA, Nicholls RJ. An assessment of inflammation in the reservoir after restorative proctocolectomy with ileoanal ileal reservoir. *Int J Colorectal Dis*. 1986;1:167–74.
8. Shepherd NA, Jass JR, Duval I, Moskowitz RL, Nicholls RJ, Morson BC. Restorative proctocolectomy with ileal reservoir: pathological and histochemical study of mucosal biopsy specimens. *J Clin Pathol*. 1987;40:601–7.
9. Kariv R, Remzi FH, Lian L, Bennett AE, Kiran RP, Kariv Y, et al. Preoperative colorectal neoplasia increases risk for pouch neoplasia in patients with restorative proctocolectomy. *Gastroenterology*. 2010;139, 812.e1–2.
10. Biancone L, Calabrese E, Palmieri G, Petruzzello C, Onali S, Sica GS, et al. Ileal lesions in patients with ulcerative colitis after ileo-rectal anastomosis: relationship with colonic metaplasia. *World J Gastroenterol*. 2008;14:5290–300.
11. Andersson P, Norblad R, Söderholm JD, Myrelid P. Ileorectal anastomosis in comparison with ileal pouch anal anastomosis in reconstructive surgery for ulcerative colitis—a single institution experience. *J Crohns Colitis*. 2014;8:582–9.