



Technical Note

Sphincter-saving extrasphincteric rectal dissection and proximal segmental sphincteric excision techniques by using combined abdominal and transvaginal anterior perineal access in female patients who have lower rectal cancer (Transvaginal low anterior rectal resection)



Ali Naki Yücesoy

Batı Bahat Hospital, General Surgery Department, Istanbul, Turkey

ARTICLE INFO

Article history:

Received 29 March 2017

Accepted 17 May 2017

Available online 15 July 2017

Keywords:

Lower rectal cancer

Sphincter-saving surgery

Combined abdominal and perineal approach

ABSTRACT

Background: Combined abdominal and transvaginal anterior perineal approaches have been used as an alternative surgical method for the surgical treatment of the lower rectal cancer. The main aim of this paper is to describe the surgical stages of the combined abdominal and transvaginal approaches performed for lower rectal cancer, especially in transvaginal anterior perineal stage.

Method: We have performed sphincter-saving surgical operations by using transvaginal anterior perineal access by combining with the abdominal access in four female patients who had lower rectal cancer.

Results: Sphincter-saving extrasphincteric dissection and proximal segmental sphincteric excision techniques were performed in four female patients operated with combined abdominal and transvaginal anterior perineal approach. All patients were found to have continence. Postoperatively, one patient was converted to abdominoperineal rectal amputation due to the detected distal resection margin positivity.

Conclusion: Transvaginal anterior perineal access provides the extrasphincteric rectal dissection possibility in the ischioanal fossa. Therefore, the combined abdominal and transvaginal anterior perineal approaches have been based on the different anatomical and surgical features when compared to intersphincteric dissection technique which is the most common used surgical procedure in lower rectal cancer surgery.

© 2017 Sociedade Brasileira de Coloproctologia. Published by Elsevier Editora Ltda. This is an open access article under the CC BY-NC-ND license (<http://creativecommons.org/licenses/by-nc-nd/4.0/>).

E-mail: alinakiyucesoy@gmail.com

<http://dx.doi.org/10.1016/j.jcol.2017.05.005>

2237-9363/© 2017 Sociedade Brasileira de Coloproctologia. Published by Elsevier Editora Ltda. This is an open access article under the CC BY-NC-ND license (<http://creativecommons.org/licenses/by-nc-nd/4.0/>).

Técnicas de dissecação retal extra-esfincteriana e de excisão esfincteriana segmentar proximal com preservação de esfíncter com o uso de acesso abdominal e perineal anterior transvaginal combinado em mulheres portadoras de câncer retal baixo (Ressecção anterior do reto baixa por via transvaginal)

R E S U M O

Palavras-chave:

Câncer de reto baixo
Cirurgia com preservação de esfíncter
Abordagem abdominal e perineal combinada

Introdução: Uma combinação de abordagens abdominal e perineal anterior transvaginal tem sido empregada como método cirúrgico alternativo para o tratamento cirúrgico do câncer de reto baixo. O principal objetivo do presente artigo é a descrição dos estágios cirúrgicos das abordagens abdominal e transvaginal combinadas realizadas para câncer de reto baixo, especialmente no estágio perineal anterior transvaginal.

Método: Realizamos operações cirúrgicas com preservação de esfíncter com o uso do acesso perineal anterior transvaginal, em combinação com o acesso abdominal, em quatro pacientes mulheres portadoras de câncer de reto baixo.

Resultados: Realizamos técnicas de dissecação extra-esfincteriana e de excisão esfincteriana segmental proximal com preservação de esfíncter em quatro pacientes operadas com uma combinação de abordagens abdominal e perineal anterior transvaginal. Todas as pacientes estavam continentas. Em uma paciente, houve necessidade de conversão para amputação retal abdominoperineal, por ter sido detectada, no pós-operatório, positividade na margem de ressecção distal.

Conclusão: O acesso perineal anterior transvaginal torna possível a dissecação retal extra-esfincteriana na fossa isquioanal. Portanto, as abordagens combinadas abdominal e perineal anterior transvaginal se baseiam em diferentes características anatômicas e cirúrgicas, em comparação com a técnica de dissecação interesfincteriana, que é o procedimento cirúrgico de uso mais comum na cirurgia para câncer de reto baixo.

© 2017 Sociedade Brasileira de Coloproctologia. Publicado por Elsevier Editora Ltda. Este é um artigo Open Access sob uma licença CC BY-NC-ND (<http://creativecommons.org/licenses/by-nc-nd/4.0/>).

Introduction

Transvaginal access in rectal surgery has been used for over one hundred years. Transvaginal local resection of rectal neoplasms using transvaginal route is encountered as Murphy method in Sir Charles Ball's book "The Rectum".¹ We have found a report describing transvaginal rectal resection in addition to abdominal access written by Castro.²

Combined abdominal and perineal (anterior or posterior) approaches have been collecting a rising interest as alternative sphincter-saving surgical methods in lower rectal cancer surgery in recent years.³⁻⁵ Also, transvaginal access use provides the perfect anterior perineal rectal exposition. All of the combined abdominal and perineal (anterior or posterior) approaches have been based on the similar anatomical and surgical features unlike the intersphincteric rectal dissection technique.⁶ These features can be summarized as the use of the sphincter-saving extrasphincteric dissection and proximal segmental sphincteric excision techniques.^{3,5}

The main aim of the perineal access use in combined approaches is to provide the extrasphincteric rectal exposition of the surgical anal canal in the ischioanal fossa. Surgical anal canal is constituted by two intertwined cylindrical muscular tubes. The external sphincteric musculature, which has a coil-like shape, can be considered as the outer one of these two intertwined muscle tubes. Anatomical anal canal and distal parts of the lower rectum constitute the inner side muscular

tube settled inside the external anal sphincteric system. Intersphincteric space is a potential space between two cylindrical muscular tubes in which intersphincteric dissection is carried out. Extrasphincteric dissection possibility on the surgical anal canal provided via the perineal approach reveals the anatomical and surgical differences of the combined abdominal and perineal approaches unlike the intersphincteric dissection technique.

Method

The patients were prepared in the Lloyd-Davies lithotomy position on the operating table. Operations were performed in two phases, including abdominal and transvaginal anterior perineal phases. The rectosigmoid dissection and total mesorectal excision were done until reaching up to the puborectal muscle level in the abdominal phase of the operation. In the transvaginal anterior perineal phase of the operation, transsphincteric distal rectal resection, proximal segmental sphincter excision and coloanal anastomosis were performed after providing the extrasphincteric rectal dissection in the ischioanal fossa. Ischioanal fossa do not contain the mesorectal tissue. Therefore, total mesorectal excision is performed in the abdominal phase of the operations.

While the abdominal phase of the operation is very familiar for surgeons, the transvaginal anterior perineal phase may

not be familiar for most of them. Therefore, we would like to refer about anatomical and surgical features encountered in the transvaginal anterior perineal phase of the operation, rather than in the abdominal phase.

An elliptic incision between the vaginal mucosa and the dermis at the posterior vaginal fourchette was used for providing the transvaginal rectal access. Surgical anal canal liberalization from surrounding tissues was performed in the extrasphincteric plane after passing through rectovaginal septal tissues. When the surgical exposition was provided in the ischioanal fossa by using transvaginal rectal access, distal part of the rectum surrounded with external anal sphincteric system (the surgical anal canal) was encountered. At this stage of the operation, abdominal and transvaginal perineal dissection lines were connected with each other after the separation of the fibrous adhesions at the puborectal muscle level. Therefore, full rectal mobilization was provided by connecting the abdominopelvic space and ischioanal fossa. After the distal resection line determination and the placement of the fixation sutures, distal rectal resection was performed transvaginally.

When the distal rectal resection was commenced in the ischioanal fossa transvaginally, it is possible to show that distal resection line is in the transsphincteric plane as dependent to transection of the external sphincteric musculature surrounding the distal rectum. At this stage of the operation, the proximal external sphincteric segment, which would be excised, was separated from corresponding distal rectal segment for showing the proximal segmental sphincteric excision (Figs. 1 and 2). After the completion of the transsphincteric distal rectal resection, the distal anal external sphincteric segment was fixated to bowel edges to prevent the distal anal sphincteric segment retraction (Fig. 3). A full-thickness coloanal anastomosis by using transvaginal route was performed between the colon and distal anal sphincteric segment, after completion of the rectosigmoid resection (Fig. 4). Abdominal and vaginal incisions were closed following the covering ileostomy. Postoperatively, covering ileostomies were closed in the second months.

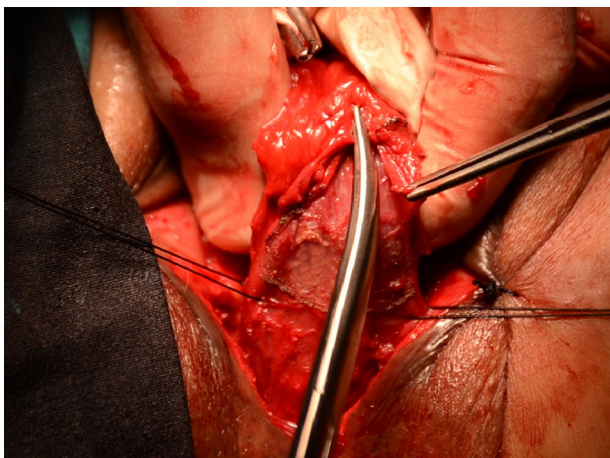


Fig. 1 – The vertical incision performed to proximal anal sphincteric segment for showing the lower rectum.

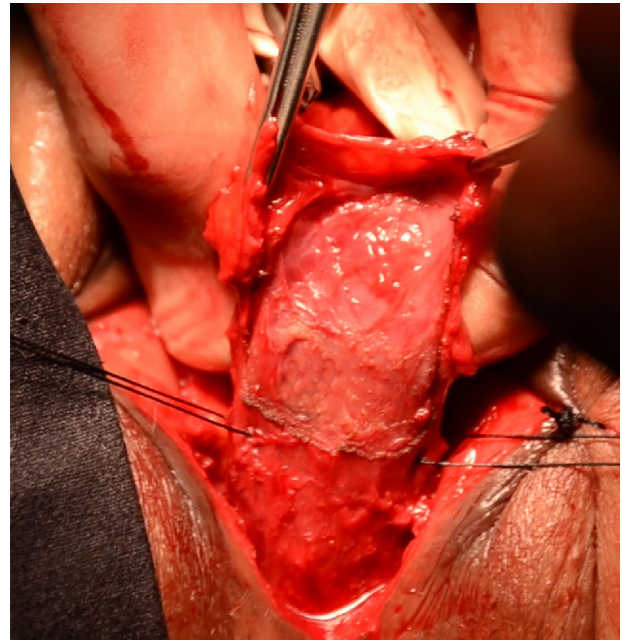


Fig. 2 – The retraction of the proximal anal sphincteric segment for showing the intersphincteric space and lower rectum.

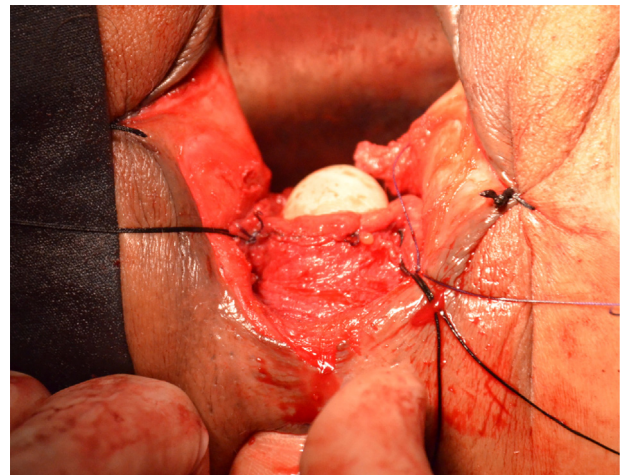


Fig. 3 – The fixation of the distal anal sphincteric segment to the bowel edges for preserving the remaining distal anal sphincteric retraction after transsphincteric rectal resection.

Results

We have performed sphincter-saving surgical operations by using transvaginal anterior perineal access by combining with the abdominal access in four female patients who have very low rectal cancer in a low-volume hospital. Although the proximal segmental sphincteric excision was performed in the patients, anal incontinences were not seen. The mean Wexner continence score was found to be 5. Rectovaginal fistula or anastomotic stricture was not seen in the patients. Proximal, distal and circular resection margins were found as negative

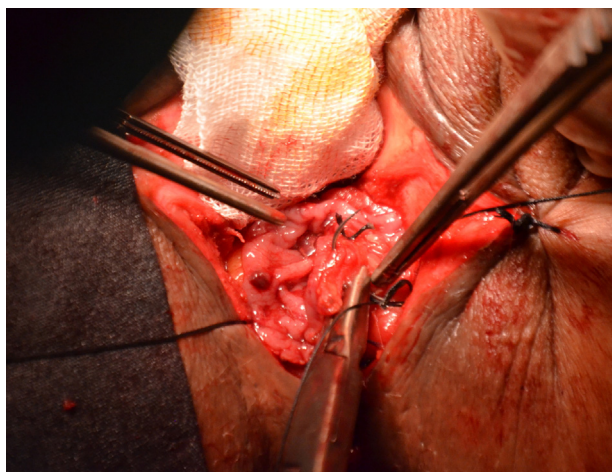


Fig. 4 – Ultra-low coloanal anastomosis via transvaginal access in the ischioanal fossa.

except one patient who had converted to abdominoperineal rectal amputation due to distal resection margin positivity.

Discussion

Combined abdomino-transvaginal rectal resection technique has different anatomical and surgical features when compared with intersphincteric dissection technique which is the most commonly used sphincter-saving surgical technique in the lower rectal cancer surgical treatment described by Schissel et al.⁶ There is a common truth behind all conceptually similar scientific studies. The main reason for the anatomical and surgical differences in the combined and perineal approaches is to use the perineal access. Perineal access use allows extrasphincteric rectal dissection on the surgical anal canal in the ischioanal fossa. All of the combined abdominoperineal (anterior or posterior) approaches have been based on the similar anatomical and surgical features.^{3,5} Combined abdominal and perineal (anterior or posterior) approaches can be described as surgical procedures in which the sphincter-saving extrasphincteric dissection and proximal segmental sphincteric excision techniques are performed. It is possible to reach to ischioanal fossa easily with transvaginal route and to realize an alternative

sphincter-saving resection method in the surgical treatment of lower rectal cancers.

Although the combined abdominoperineal approaches seem to have the higher complication ratios compared to the intersphincteric dissection technique, it should be remembered that the combined abdominoperineal approaches have been performed in the extrasphincteric plane. It was shown that rectal resections performed by means of extrasphincteric rectal dissection technique are oncologically superior to rectal resections realized by means of intersphincteric dissection technique in lower rectal cancer surgery.⁷ Although it is too early to discuss on the oncological outcomes of the combined abdominal and perineal approaches, the safer oncological results in terms of the radial spread of the tumor cannot be a surprise.

Conflicts of interest

The author declares no conflicts of interest.

REFERENCES

1. Ball C. *The rectum. Its diseases and developmental defects.* London: Oxford Medical; 1908. p. 276-82.
2. Castro AF. Vaginal approach in resection of low-lying malignant lesions. *Tex Med.* 1974;69:65-9.
3. Pena A, Hong A. The posterior sagittal trans-sphincteric and trans-rectal approaches. *Tech Coloproctol.* 2003;7:35-44.
4. Williams NS, Murphy J, Knowles CH. Anterior perineal plan for ultra-low anterior resection of the rectum (the APPEAR technique): a prospective clinical trial of a new procedure. *Ann Surg.* 2008;247:750-75.
5. Yücesoy AN, Poçan S. Letter to editor on "The combined abdominal and perineal approach for dissection of the rectum. The development of new indications". How can we describe the anatomical and surgical basis of the combined abdominal and perineal approaches in lower rectal cancer surgery? *Int J Surg.* 2015;19:33-4.
6. Schiessel R, Karner-Hanusch J, Herbst F, Teleky B, Wunderlich M. Intersphincteric resection for low rectal tumours. *Br J Surg.* 1994;81:1376-8.
7. West NP, Finan PJ, Anderin C, Lindholm J, Holm T, Quirke P. Evidence of the oncologic superiority of cylindrical abdominoperineal excision for low rectal cancer. *J Clin Oncol.* 2008;26:3517-22.