



## Original Article

# Differences between polydioxanone and poliglactin in intestinal anastomoses – a comparative study of intestinal anastomoses



Carlos Henrique Marques dos Santos<sup>a,b,\*</sup>, Kerginaldo Gondim dos Santos Filho<sup>a</sup>, Pedro Carvalho Cassino<sup>a</sup>, Camila Vieira Chiquetti<sup>a</sup>, Alvaro Pereira de Mello<sup>a</sup>, Doroty Mesquita Dourado<sup>b</sup>

<sup>a</sup> Universidade Federal de Mato Grosso do Sul (UFMS), Hospital Universitário Maria Aparecida Pedrossian (HUMAP), Campo Grande, MS, Brazil

<sup>b</sup> Universidade Anhanguera (Uniderp), Campo Grande, MS, Brazil

### ARTICLE INFO

#### Article history:

Received 30 March 2017

Accepted 17 May 2017

Available online 14 July 2017

#### Keywords:

Anastomosis, surgical

Polydioxanone

Polyglactin 910

Rats

Small intestine

### ABSTRACT

**Introduction:** Intestinal anastomosis is a surgical practice constantly realized by surgeons worldwide. When the option is to perform manual anastomosis, which is still widely used for its low cost, the question arises as to the best material to be applied.

**Objective:** To compare polydioxanone and polyglactin threads for healing and tensile strength in intestinal anastomosis in rats.

**Method:** We used 25 rats Wistar; after anesthesia, in groups A and B (10 rats each), laparotomy was performed, transection of the ileum at 5 and 10 cm proximally to the ileocecal valve; in group A, anastomosis was performed with 4 separate extra mucosal sutures with polydioxanone; in group B, anastomosis was performed with polyglactin; in group C (5 rats), laparotomy and manipulation of the ileum were performed. After 21 days, the animals were anesthetized and submitted to euthanasia. The specimens were sent for histopathological study and tensile strength analysis. Statistical analysis was performed using the Turkey and Student's t tests, with a significance of  $p < 0.05$ .

**Results:** The results showed that in the tensile strength analysis, there were no significant differences between them. The histological analysis showed significant differences between the cicatrization pattern, where polydioxanone caused less fibrosis than polyglactin.

**Conclusion:** Polydioxanone caused less fibrosis than polyglactin in intestinal anastomoses of rats.

© 2017 Sociedade Brasileira de Coloproctologia. Published by Elsevier Editora Ltda. This is an open access article under the CC BY-NC-ND license (<http://creativecommons.org/licenses/by-nc-nd/4.0/>).

\* Corresponding author.

E-mail: [chenriquems@yahoo.com.br](mailto:chenriquems@yahoo.com.br) (C.H. Santos).

<http://dx.doi.org/10.1016/j.jcol.2017.05.004>

2237-9363/© 2017 Sociedade Brasileira de Coloproctologia. Published by Elsevier Editora Ltda. This is an open access article under the CC BY-NC-ND license (<http://creativecommons.org/licenses/by-nc-nd/4.0/>).

## Diferenças entre polidioxanona e poliglactina em anastomoses intestinais – estudo comparativo de anastomoses intestinais

### R E S U M O

#### Palavras-chave:

Anastomose cirúrgica  
Polidioxanona  
Poliglactina 910  
Ratos  
Intestino delgado

**Introdução:** Anastomose intestinal é uma prática cirúrgica constantemente realizada pelos cirurgiões em todo o mundo. Quando a opção é a anastomose manual – um procedimento ainda amplamente empregado, graças a seu baixo custo – coloca-se o problema de saber qual é o melhor material a ser aplicado.

**Objetivo:** Comparar fios de polidioxanona e poliglactina quanto à cicatrização e resistência à tração em anastomoses intestinais em ratos.

**Método:** Utilizamos 25 ratos Wistar; depois da anestesia, foi realizada laparotomia nos grupos A e B (10 ratos cada), com transecção do íleo a 5 e 10 centímetros proximalmente à válvula ileocecal; no grupo A, a anastomose foi realizada com 4 suturas de mucosa separadas com uso de polidioxanona; no grupo B, a anastomose foi realizada com poliglactina; no grupo C (5 ratos), foi realizada apenas a laparotomia e manipulação do íleo. Transcorridos 21 dias, os ratos foram anestesiados e submetidos à eutanásia. Os espécimes foram enviados para estudo histopatológico e análise de resistência à tração. A análise estatística foi efetuada com a aplicação dos testes de Tukey e de t de Student, com significância de  $p < 0,05$ .

**Resultados:** Os resultados demonstraram que, na análise de resistência à tração, não foram observadas diferenças significativas entre os materiais. A análise histológica revelou diferenças significativas entre padrões de cicatrização, em que polidioxanona causou menos fibrose versus poliglactina.

**Conclusão:** Polidioxanona causou menos fibrose versus poliglactina em anastomoses intestinais realizadas em ratos.

© 2017 Sociedade Brasileira de Coloproctologia. Publicado por Elsevier Editora Ltda. Este é um artigo Open Access sob uma licença CC BY-NC-ND (<http://creativecommons.org/licenses/by-nc-nd/4.0/>).

## Introduction

Many methods of intestinal suture have been performed since the earliest days of surgery. However, only in the year 1264, Ruggiero presented the surgical practice of the digestive suture, using silk threads. Richerand, in the nineteenth century, presented the theory of incoherence of the union of serosa with mucosa, beginning the idea of performing an intestinal anastomosis joining the extramucosal layers.<sup>1</sup>

A feared complication in this type of anastomosis, dehiscences and fistulas represent an important problem for specialists dealing with the digestive tract, since they can lead to severe electrolyte depletion, acid-base imbalance, infection and severe malnutrition, with a long hospital stay and the high cost of treatment. Several factors such as malnutrition, infection, ischemia, etc. may be related, but the technical failure and type of anastomosis performed must also be considered.<sup>2</sup>

Intestinal anastomoses can be performed with one or two continuous layers, separate stitches, with an invaginating or evading end result of the edges of the anastomosis. Various materials are used to make these sutures, such as: silk, cotton, linen and synthetic threads. The most commonly used manual technique is single-layer, extra-mucosal, with monofilament yarns, while many use mechanical staplers, which have the advantage of shortening operative time, although they increase the cost of the procedure.<sup>3</sup>

There is no evidence that stapled anastomosis is superior to manual. In fact, the stapled suture may even lead to a higher

rate of postoperative bleeding in some situations.<sup>4,5</sup> Despite this, stapling was a very important advance in intestinal anastomoses and should be increasingly improved. However, there is still room for manual anastomosis, especially since it allows for lower costs.

Garude et al.<sup>6</sup> demonstrated that there is no benefit in performing intestinal anastomosis in two planes, the anastomosis in an extramucosal single plane being as efficient as that, but performed more quickly and economically.

Bernis-Filho et al.<sup>7</sup> compared cotton, polyglecaprone and polyglactin threads in intestinal anastomoses of dogs and observed no difference between these materials. It would be expected that multifilament threads such as cotton and polyglactin caused a greater tissue reaction, which was not proven when compared to polyglecaprone. Although polydioxanone and polyglecaprone are both absorbable and monofilamentary, they have different characteristics, and polydioxanone has been preferred for intestinal anastomosis, although there is no scientific evidence of its superiority. Thus, it remains to be seen whether there is any difference between the type of material used for such anastomoses, and the objective of this study is to compare polydioxanone and polyglactin threads for healing and tensile strength in intestinal anastomoses in rats.

## Objective

To compare polydioxanone and polyglactin threads for healing and tensile strength in intestinal anastomoses in rats.

## Material and methods

The study was submitted to the approval of the Animal Ethics Committee of the Federal University of Mato Grosso do Sul, following all the rules of the CEUA – Ethics Committee on Animal Use, and COBEA – Brazilian Society of Animal Laboratory Science.

Twenty-five male Wistar (*Rattus norvegicus*) rats, weighing approximately 300 g were studied, from the Vivarium of the Federal University of Mato Grosso do Sul. The animals were kept in the experimental area of the UFMS Central Vivarium, according to all standards.

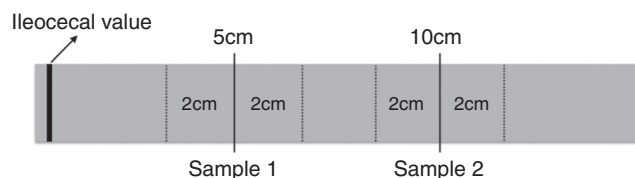
The animals were distributed into three groups:

- Group A (polydioxanone): 10 rats subjected to intestinal section and anastomosis with polydioxanone 4–0.
- Group B (polyglactin): 10 rats subjected to intestinal section and anastomosis with polyglactin 4–0.
- Group C (control): 5 rats subjected to laparotomy and manipulation of the ileum, without intestinal section and anastomosis.

Anesthesia was performed by intraperitoneal administration of ketamine and xylazine, in the same syringe. The solution was composed of 1.0 mL of ketamine 10% and 1.0 mL of xylazine 2%, 0.1 mL of the solution being administered per 100 g of weight.

Each animal was anesthetized and then placed in dorsal decubitus position, with abduction paws, with a median laparotomy of 3 cm. In group C, the ileum was only manipulated, followed by closure of the abdominal wall. In the other groups, the intestine was externalized to the location of the ileocecal valve; 5 cm and 10 cm proximal to the ileocecal valve were performed the transections of the entire intestinal circumference with cold scalpel, preserving the mesentery. An extra mucosal end-to-end anastomosis was then performed with four separate sites in the two transection areas, with 4–0 polydioxanone (PDS<sup>®</sup>, Ethicon, USA) in group A and 4–0 polyglactin (Vicryl<sup>®</sup>, Ethicon, USA) in group B. The intestine was repositioned in the abdominal cavity, which was closed by continuous suture with 3–0 nylon thread.

The animals were kept in individual cages for 21 days, with food and water *ad libitum*. After this period, they were again anesthetized and subjected to euthanasia by intracardiac administration of sodium thiopental. A new laparotomy was performed and 15 cm of the ileum from the ileocecal valve were resected. The segments containing the 5 cm point anastomosis of groups A and B and the equivalent area without suture of group C, with proximal and distal margins of 2 cm (sample 1) (Fig. 1), were removed, washed with saline solution and placed in previously identified tubes containing 10% formaldehyde for further histological analysis. This material was sent to the pathology for the preparation of the slides that were stained with hematoxylin and eosin for analysis of granulation tissue and healing with a Nikon E200 microscope and millimeter eyepieces. The segments containing the 10 cm point anastomosis of groups A and B and the equivalent area without suture of group C, with proximal and distal margins of 2 cm (sample 2) (Fig. 1), were removed, washed with saline



**Fig. 1 – Schematic diagram showing the resected segments for study. Sample 1: histopathological study; Sample 2: tensile force analysis.**

solution and submitted to tensile strength analysis with the use of the Instrol apparatus, calibrated in Newton (N). The apparatus was programmed to exert tensile force until the rupture of the tissue that was mounted in the apparatus with the use of own claws, respecting the distance of 2 cm of margin of the anastomosis for each side of the fixation. The value of the result in Newton (N) was converted to kilogram force (kgf), to perform the statistical analysis.

Statistical analysis was performed using the Turkey and Student's *t* tests, with a significance of  $p < 0.05$ .

## Results

The results in relation to the tensile strength of rupture showed average 0.098 in group A, 0.13 in group B and 0.139 in group C (Table 1 and Fig. 2).

The analysis of variance applied to the different groups revealed no significant difference between them ( $p = 0.085$ ). Thus, there was no need to complement the analysis by the Tukey test for two-to-two comparisons.

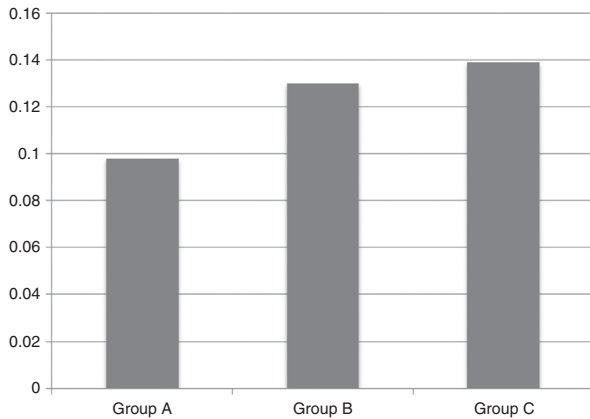
The results of fibrosis evaluation found were 0.075 for group A and 0.165 for group B (Table 2 and Fig. 3). Student's *t*-test applied to the length of the mucosal borders, revealed a significant difference between the measured healing pattern ( $p = 0.027$ ), and there was less fibrosis with polydioxanone.

## Discussion

The cicatricial process is of extreme importance in an intestinal anastomosis, and occurs in three phases: inflammatory,

**Table 1 – Analysis of tensile strength between different groups.**

Rats	Measurements of tensile strength rupture (kgf)		
	Group A	Group B	Group C
1	0.099	0.121	0.323
2	0.094	0.05	0.099
3	0.122	0.106	0.164
4	0.078	0.193	0.543
5	0.085	0.132	0.136
6	0.098	0.134	
7	0.148	0.158	
8	0.152	0.089	
9	0.069	0.143	
10	0.037	0.18	
Average	0.098	0.13	0.139

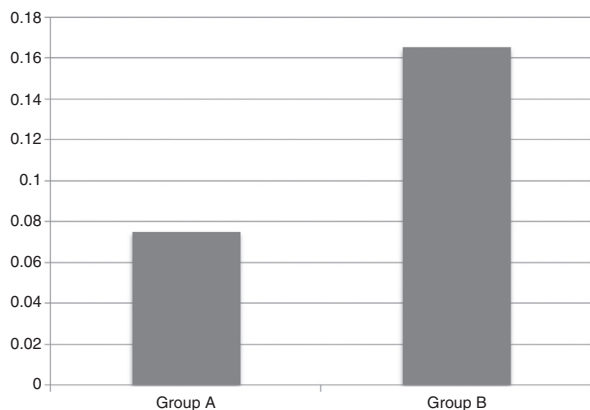


**Fig. 2 – Average of rupture tensile between the different groups, expressed in kgf.**

**Table 2 – Measurements of granulation tissue in the anastomosis area between the different groups.**

Rats	Measurements of the granulation tissue from the edge of the mucosa (mm)	
	Group A	Group B
1	0.05	0.25
2	0.1	0.2
3	0.1	0.2
4	0.1	0.3
5	0	0.2
6	0.2	0.15
7	0	0.2
8	0.05	0
9	0	0.15
10	0.15	0
Average	0.075	0.165

proliferative and maturation and remodeling, which present certain overlap at certain moments. A healthy body should have adequate healing, which could be hampered by factors such as malnutrition, local and systemic infection, use of certain drugs such as corticosteroids, etc. These are usually factors inherent to the patient and with limited possibility of the attending physician. Thus, those factors directly related



**Fig. 3 – Average length of edges of the mucosa, expressed in millimeters.**

to the surgeon's performance during an anastomosis, such as the preservation of adequate blood supply, the operative technique and the material used, become more important in medical practice.<sup>8</sup>

When a hand-sewn anastomosis is performed, the thread used will play a role in the first stage of healing, when there is a reaction against the material, since this is a foreign body and will trigger an inflammatory process that will be of longer or shorter duration, as well as larger or less intensity depending on the amount of thread used, its structure, i.e. whether it is mono or multi-filament and the material of which it is composed.<sup>9</sup> Whether these factors influence tensile strength and the incidence of dehiscence are still to be answered.

In the present study, it was observed that the polydioxanone thread presented less fibrosis formation than polyglactin, which can be understood by the fact that the first one is monofilament, which would lead to a lower inflammatory process and consequently less tissue fibrosis.<sup>10</sup> Comparison of hand-sewn anastomoses with stapled ones and more recently with the use of compression devices make us observe that the smaller the use of foreign material, the better the anastomosis due to the lower fibrosis. In a recent study using a compression device, satisfactory results were obtained without the presence of foreign material and its possible complications.<sup>11</sup> In a systematic review of 1233 patients comparing mechanical staplers with hand-sewn bowel suture, no differences were found in the results, however, staples are known to trigger a lower inflammatory response than multi-filament threads such as polyglactin.<sup>12</sup>

The sutures are performed for two purposes: to maintain coaptation of the edges of the operative wound and to resist the extrinsic tension forces until the scar acquires its own tension force. Normally in the first four days this intrinsic force is virtually zero, growing progressively until healing keeps the edges together independently of the stitches. The time taken for this to occur is variable, depending on the tissue analyzed, the species and the factors related to surgery, such as infection and drug use, for example. In the rat intestine it is not yet well defined what this time would be, but the results obtained here showed that at 21 days there was no difference in tensile strength between the studied materials, proving that both are effective with the same intensity in maintaining the integrity of the anastomosis until this period. As there was greater fibrosis with polyglactin, one could expect greater resistance than with polydioxanone, which did not happen, that is, greater fibrosis does not mean greater protection against dehiscence.<sup>13</sup>

Comparative studies between polydioxanone and polyglactin are rare, especially in the analysis of factors related to intestinal anastomosis, so the present study contributes to this gap in the literature. Although there was no difference in tensile strength between the studied threads, there was a greater inflammatory reaction and fibrosis with polyglactin, which allows us to infer that during a period there was more edema in the suture line in this group. Local edema can lead to increased digestive transit difficulty, abdominal discomfort and colicky pain. Although these factors have not been studied here, there may be a greater advantage in the use of polydioxanone in intestinal anastomoses because they produce less edema in the anastomosis line.

Werra et al.<sup>14</sup> had compared different threads in intestinal anastomoses of rats, among them polydioxanone and polyglactin, and found no important differences in the histopathological study, however, using different evaluation periods than those used here. Considering the scarcity of publications on the subject and its great relevance, considering that hand-sewn anastomosis is still practiced on a large scale, studies should be carried out in this direction.

---

## Conclusion

Polydioxanone caused less fibrosis than polyglactin in intestinal anastomoses of rats. There was no difference between the studied threads as regards tensile strength.

---

## Conflicts of interest

The authors declare no conflicts of interest.

---

## REFERENCES

1. Fernandes LC, Matos D, Novelli MD, Kim SB. Comparative study of intestinal anastomosis with manual suture and biofragmentable ring in dogs under corticosteroid administration. *Rev Assoc Med Bras.* 2000;46:113–20.
2. Connel ME. An experimental contribution looking to an improved technique in enterorrhaphy, whereby the number of knots is reduced to two, or even one. *Med Rec.* 1982;42:335–7.
3. Barros M, Gorgal R, Machado AP, Correia A, Montenegro N. Surgical basic skills: surgical sutures. *Acta Med Port.* 2011;24:1051–6.
4. Jiang HP, Lin LL, Jiang X, Qiao HQ. Meta-analysis of hand-sewn versus mechanical gastrojejunal anastomosis during laparoscopic Roux-en-Y gastric bypass for morbid obesity. *Int J Surg.* 2016;32:150–7.
5. Kayani B, Garas G, Arshad M, Athanasiou T, Darzi A, Zacharakis E. Is hand-sewn anastomosis superior to stapled anastomosis following oesophagectomy. *Int J Surg.* 2014;12:7–15.
6. Garude K, Tandel C, Rao S, Shah NJ. Single layered intestinal anastomosis: a safe and economic technique. *Indian J Surg.* 2013;75:290–3.
7. Bernis-Filho WO, Wouters F, Wouters AAP, Bernis VMO, Lopes LR, Andreolo NA. Comparative study of cotton, polyglactin and polyglycaprone sutures in intestinal anastomoses in dogs. *ABCD Arq Bras Cir Dig.* 2013;26:18–26.
8. Golub R, Golub RW, Cantu R, Stein HD. A multivariate analysis of factors contributing to leakage of intestinal anastomoses. *J Am Coll Surg.* 1997;184:364–72.
9. García-Osogobio SM, Takahashi-Monroy T, Velasco L, Gaxiola M, Sotres-Vega A, Santillán-Doherty P. Single-layer colonic anastomoses using polyglyconate (Maxon) vs. two-layer anastomoses using chromic catgut and silk. *Experimental study. Rev Invest Clin.* 2006;58:198–203.
10. Holzner P, Kulemann B, Seifert G, Glatz T, Chikhladze S, Höppner J, et al. Double 90 degrees counterrotated end-to-end-anastomosis: an experimental study of an intestinal anastomosis technique. *Eur J Pediatr Surg.* 2015;25:269–76.
11. González-Contreras QH, Jesús-Mosso M, Bahena-Aponte JA, Aldana-Martínez O, Pineda-Solís K, Mejia-Arcadia SN. Colorectal anastomosis using a compression device. *Cir Cir.* 2016;84:482–6.
12. Neutzling CB, Lustosa SA, Proenca IM, Silva EM, Matos D. Stapled versus handsewn methods for colorectal anastomosis surgery. *Cochrane Database Syst Rev.* 2012;15:CD003144.
13. Duell JR, Thieman Mankin KM, Roach MC, Regier PJ, Singh A, Luther JK, et al. Frequency of dehiscence in hand-sutured and stapled intestinal anastomoses in dogs. *Vet Surg.* 2016;45:100–3.
14. Werra C, Rendano F, D'Armiento F, Somma P, Forestieri P. Comparison of five synthetic absorbable suture materials in intestinal anastomosis: experimental study in rats. *Chir Ital.* 2003;55:227–33.