



Original Article

Use of endoanal ultrasound as complimentary evaluation for detection of anal sphincter injury after vaginal birth



Ahmad Izadpanah^a, Ensieh Izadpanah^b, Mehrzad Lotfi^b, Alamtaj Samsami^c,
Alireza Safarpour^a, Mohammad Rezazadehkermani^{d,*}

^a Shiraz University of Medical Sciences, Colorectal Research Center, Shiraz, Iran

^b Shiraz University of Medical Sciences, School of Medicine, Department of Radiology, Shiraz, Iran

^c Shiraz University of Medical Sciences, School of Medicine, Department of Obstetrics & Gynecology, Shiraz, Iran

^d Shiraz University of Medical Sciences, School of Medicine, Department of General Surgery, Shiraz, Iran

ARTICLE INFO

Article history:

Received 6 November 2016

Accepted 21 April 2017

Available online 18 May 2017

Keywords:

Endosonography

Vaginal delivery

Sphincter injury

Manometry

ABSTRACT

Purpose: Anal sphincter injury after delivery is the main factor in the pathogenesis of fecal incontinence. Clinical obvious and specific injury to anal canal sphincter is seen in 3% of vaginal deliveries. There are many women who do not have a clear and specific laceration but they are damaged by sphincter muscles of anal canal. The purpose of the present study is to investigate the frequency of occult anal sphincter injury after vaginal delivery by Endo-anal sonography.

Methods: Fifty women with first pregnancy were assessed at 27–33 weeks of pregnancy, and at 6 weeks and 6 months after vaginal delivery by questionnaire, examination and Endo-anal sonography. Women age, duration of delivery, the effect of epidural anesthesia, episiotomy and birth weight were studied and Endo-anal sonography results were recorded. Anal manometry was performed for all mothers before delivery and 5 ones with sphincter injury at 6 months and 3 years after delivery.

Results: Five (10%) patients, with mean age 29.4 ± 6.5 years, mean neonatal weight of 3874 ± 287 , and mean duration of delivery 11.6 ± 1.51 h, had signs of sphincter injury in Endo-anal sonography. The injury was persisted at six months after delivery. Also, significant differences were seen between anal manometry before delivery and 6 months and 3 years after delivery ($p = 0.006$ for mean squeezing pressure) in the five mothers.

Conclusion: Endo-anal sonography might be a good screening tool for early detection of post-partum anal sphincter damages. However, further prospective cost benefit studies should be performed to propose it as a standard of care.

© 2017 Sociedade Brasileira de Coloproctologia. Published by Elsevier Editora Ltda. This is an open access article under the CC BY-NC-ND license (<http://creativecommons.org/licenses/by-nc-nd/4.0/>).

* Corresponding author.

E-mail: rezazadehkermani@yahoo.com (M. Rezazadehkermani).

<http://dx.doi.org/10.1016/j.jcol.2017.04.006>

2237-9363/© 2017 Sociedade Brasileira de Coloproctologia. Published by Elsevier Editora Ltda. This is an open access article under the CC BY-NC-ND license (<http://creativecommons.org/licenses/by-nc-nd/4.0/>).

Uso da ultrassonografia endoanal como avaliação complementar para a detecção de lesão do esfíncter anal após parto vaginal

R E S U M O

Palavras-chave:

Ultrassonografia endoanal
Parto vaginal
Lesão esfínctérica
Manometria

Finalidade: A lesão de esfíncter anal após o parto é o fator principal na patogênese da incontinência fecal. Observa-se uma lesão clínica óbvia e específica ao esfíncter no canal anal em 3% dos partos vaginais. Em muitas mulheres não se percebe uma laceração nítida e específica, mas houve lesão nos músculos esfínctéricos do canal anal. A finalidade desse estudo é investigar a frequência de lesão oculta de esfíncter no canal anal em seguida ao parto vaginal por meio da ultrassonografia endoanal.

Métodos: Cinquenta mulheres primíparas foram avaliadas no período de 27-33 semanas de gestação e também a 6 semanas e 6 meses após o parto vaginal por meio de questionário, exame e ultrassonografia endoanal. Foram anotados a idade das pacientes, a duração do parto, o efeito da anestesia epidural, episiotomias e peso do bebê ao nascer; também foram registrados os resultados da ultrassonografia endoanal. Antes do parto, todas as gestantes foram submetidas a um exame de manometria; e 5 mães com lesão esfínctérica também passaram por esse procedimento a 6 meses e 3 anos após o parto.

Resultados: Cinco (10%) pacientes, com média de idade = $29,4 \pm 6,5$ anos, peso médio do bebê ao nascer = 3874 ± 287 gramas e duração média do parto = $11,6 \pm 1,51$ horas, apresentavam sinais de lesão esfínctérica ao exame por ultrassonografia endoanal. Seis meses após o parto, as lesões persistiam. Também foram observadas diferenças significativas entre a manometria anal antes do parto e a 6 meses e 3 anos após o parto ($p = 0,006$ para média de pressão de contração) nas cinco mães.

Conclusão: A ultrassonografia endoanal pode ser um bom instrumento de triagem para a detecção precoce de lesões do esfíncter anal no pós-parto. Contudo, é importante que sejam realizados novos estudos prospectivos e de custo-benefício, para que essa técnica possa ser proposta como padrão terapêutico.

© 2017 Sociedade Brasileira de Coloproctologia. Publicado por Elsevier Editora Ltda. Este é um artigo Open Access sob uma licença CC BY-NC-ND (<http://creativecommons.org/licenses/by-nc-nd/4.0/>).

Introduction

Every year, 50 million women during pregnancy, childbirth, or after that are stricken with complications and 15% of women live with chronic complications and disabilities.¹ One of these complications is anal sphincter injuries. Some risk-factors are proposed which associate with increase of anal injuries are: induction of labor, epidural analgesia, birth weight more than 4 kg, persistent occipitoposterior position, prim parity, second stage of delivery longer than 1 h and use of forceps in delivery.²

Studies showed that women who experience perineal trauma complain from urine and stool incontinence, painful intercourse, bleeding, lasting pain and pelvic muscles weakness. These problems are less in women who have healthy perineum.³ Pain, urinary incontinence, sexual dysfunction, and hemorrhoids are some problems that last up to one year after delivery and appear as chronic complications.⁴ It is reported that 85% of women have some degrees of perineal damage after delivery, and some of them need future surgical intervention.^{4,5}

Postpartum bleeding due to large cut episiotomy, extension of lacerations and a delay in repair of episiotomy can endanger mothers' health.⁴ It is also stated that anal canal sphincter injury after vaginal delivery is considered as the main factor of pathogenesis of fecal incontinence and in some cases gas

incontinence, in young and healthy women. Pelvis floor during a vaginal delivery due to stretching of perineum by head of embryo is at risk of trauma which can cause anterior portion lacerations in sphincters.⁶ Obvious and specific clinical injury to the sphincter of anal canal (lacerations of grade 3 and 4) is seen in 3% of vaginal deliveries. The amount of this injury in the United States is reported up to 18%. The amount of this clinical injury has been less in cases of mediolateral episiotomy (0.4–2.5%) and is more in cases of midline episiotomy (19%).²

In addition, there are women who do not have any laceration but their sphincter is injured. This kind of injury is called occult anal sphincter injuries that are not obvious in these women and can be detected by Endo-anal sonography. The amount of the injury has been reported in different studies from 9% to 35%.² Anal sphincter complex could be evaluated with various methods such as manometry, electromyography, MRI, and Endo-anal sonography. Endo-anal sonography has acceptable accuracy in detecting sphincter complex injuries.⁶ The position of sphincter injury in this method is reported as a clock face so that 12 o'clock position is located at the anterior midline and injury is observed as defect and disruption of sphincters.⁷

Previous reports demonstrate the role of postpartum Endo-anal sonography to detect occult sphincter injuries; such study has not been done in Iran previously. The aim of this study is

to detect the rate of postpartum anal sphincter injuries in a random sample of women in south of Iran.

Methods

This cross sectional descriptive study was approved by Ethics Committee of Shiraz University of Medical Science and all participants were completely aware from their presence in the project.

All women with a first pregnancy at 27 weeks up to 33 weeks of pregnancy (average 30 weeks) were enrolled. Patients who referred to university affiliated hospitals include Zainabieh and Hafez hospitals to evaluate before delivery and they were referred by obstetricians to participate in this project. Mothers with current anal disease or previous anal surgery were excluded from the study. Finally 50 women with mean age 26 years (16-37 years) were included and assessed by questionnaire, examination and Endo-anal sonography in average 30 weeks of gestation and 6 weeks and 6 months after vaginal delivery. Required information was recorded in the form of pre-designed questionnaire.

The questionnaire contains information including patients' age and symptoms, Endo-anal sonography findings, duration of delivery, type of anesthesia, episiotomy, and birth weight. The method of filling out the questionnaire was as face-to-face questions, examination and performance of Endo-anal sonography.

The efficiency condition of anal canal sphincters, gas and stool control was specified in these patients just before delivery and after that.

In order to functional evaluation of anal sphincter, manometry was performed for all mothers before delivery and five ones with sphincter injury, detected in Endo-anal sonography, at six months and three years after delivery.

Endo-anal sonography was done using BK Medical Class I type B Ultrasound Scanner with 12 MHz probe. Two dimensional scan was done by radiologist and colorectal consultant surgeon rechecked those patients with report of any damages in their ultrasound. No specific Bowel prep was used either in Endo-anal sonography or manometry. Manometry was done by colorectal surgery fellows using Sphincterometer System Machine (Germany).

The patients' data was entered in SPSS software (version 20, SPSS, Chicago, IL, USA) and statistical analysis was performed. Mean, maximum and minimum indices were used for describing of data. Some statistical tests such as chi square and Mann-Whitney test were used. *p* value greater than 0.05 accepted null hypothesis.

Results

Of the 84 individuals who were initially examined, 50 women were finally involved in the study and completely investigated. They all had normal examination at first visit and did not have any clinical complaints; also all had normal Endo-anal sonography.

The results show that the lowest age in the study was 16 years and the maximum age was 37 years, with mean age of 26.3 ± 5.6 years. Duration of delivery was also calculated from the time of entrance to hospital until baby birth. The minimum and maximum times for delivery were 6 and 15 h,

Table 1 – Characteristics of 5 patients with sphincter injury.

	Age	Duration of delivery (h)	Kind of episiotomy	Birth weight (g)	Sonographic findings
First patient	32	11	Mediolateral	4000	Injury to anterior portion of external sphincter
Second patient	34	12	Mediolateral	3420	Injury to anterior portion of external sphincter
Third patient	24	14	Mediolateral	4200	Injury to anterior portion of external and internal sphincter
Forth patient	21	10	Mediolateral	3850	Injury to anterior portion of external sphincter and levatorani muscle involvement
Fifth patient	36	11	Mediolateral	3900	Injury to anterior portion of external and internal sphincter

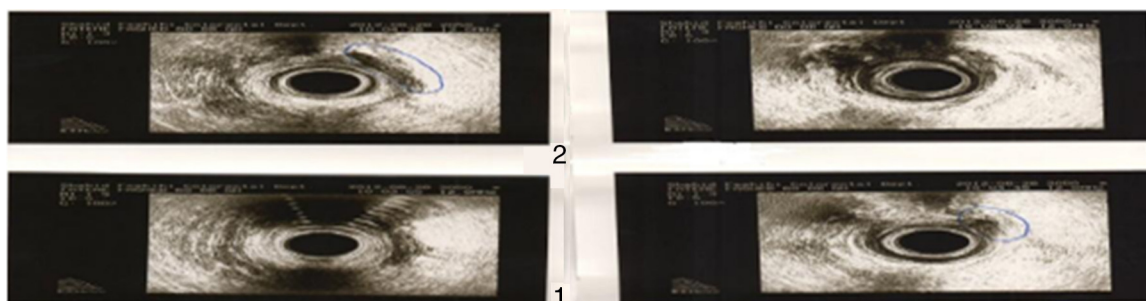


Fig. 1 – Injury to anterior portion of external sphincter of the first patient (blue circle shows site of injury).

respectively. The lowest and heaviest weights were 2550 g and 4200 g, respectively, while the mean weight was reported as 3342 ± 484.9 g (Table 1). Also, mediolateral episiotomy was performed for 45 (90%) of 50 patients.

The results showed that epidural analgesia was used only for 3 patients who were delivered in Hafez hospital and 94% of patients had done their vaginal delivery without any anesthesia and/or analgesia.

In the investigations carried out by sonography, a number of 45 individuals had normal sonography in their first postpartum visit which was performed 6 weeks after delivery. Also, any finding based on sphincter injury was not found in the individuals at the second time of sonography.

Just five patients (mean age 29 years) with mean duration of delivery 11.5 h and average birth weight 3340 g, without having any symptoms and clinical complaints had findings of

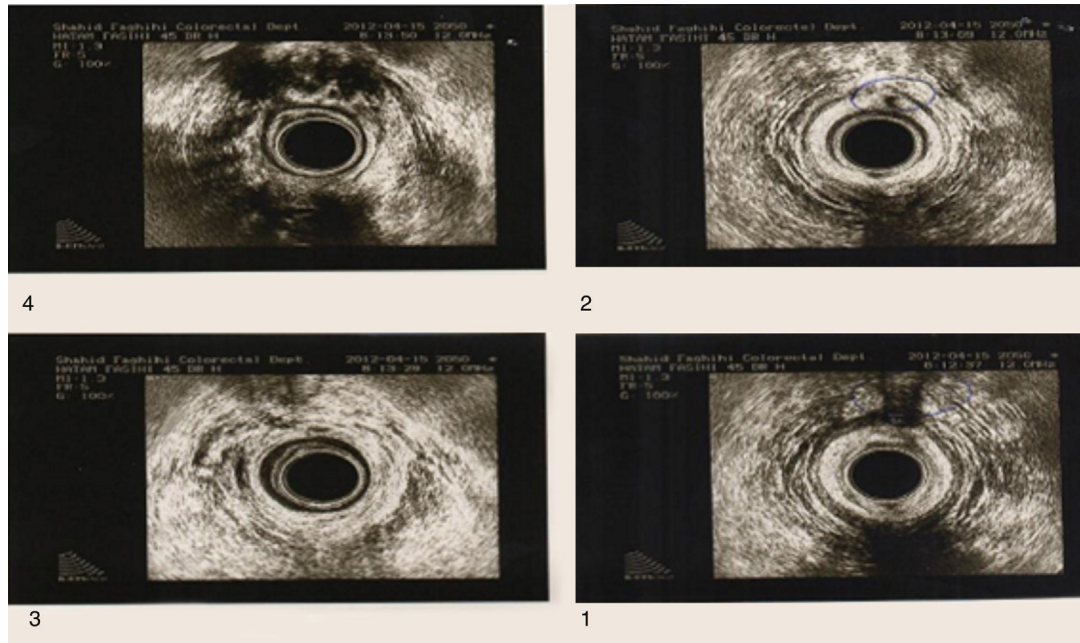


Fig. 2 – Injury to anterior portion of external sphincter of the second patient (blue circle shows site of injury).

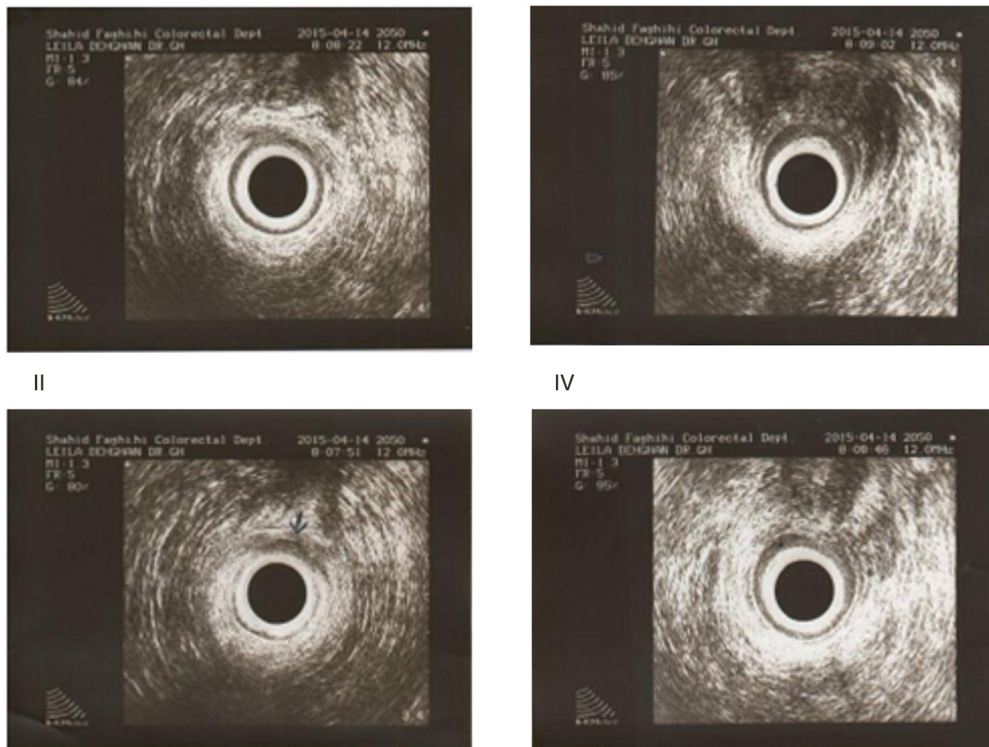


Fig. 3 – Injury to anterior portion of external and internal sphincter of the third patient (the index in the left lower image shows injury site).

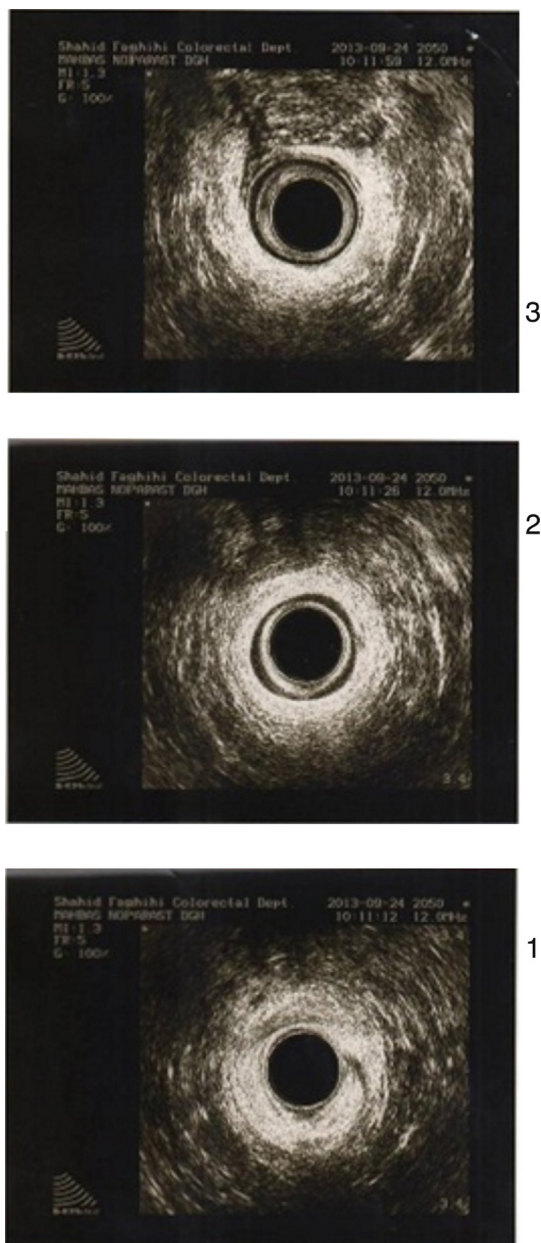


Fig. 4 – Injury to anterior portion of external sphincter and levatorani muscle involvement of the forth patient.

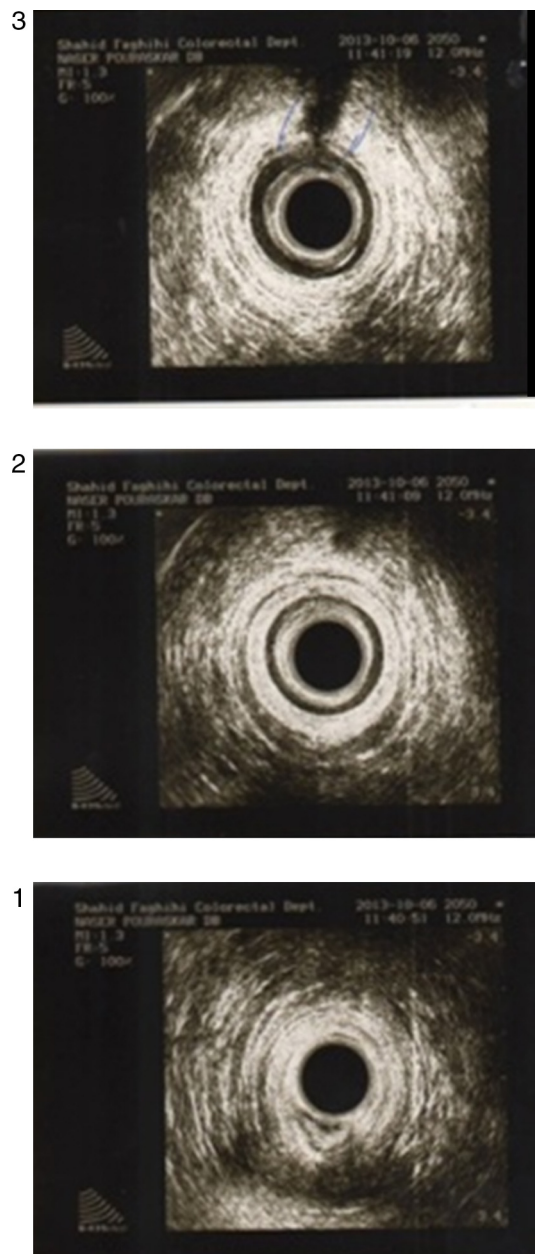


Fig. 5 – Injury to anterior portion of external and internal sphincter of fifth patient (blue circle shows site of injury).

sphincter injury in their first postpartum Endo-anal sonography. The patients' characteristics are listed in [Table 1](#). Sonography was performed for these 5 patients for the third time after 6 months and persistent damages were seen ([Figs. 1-5](#)).

Also, significant differences were seen between anal sphincter manometry before delivery and 6 months and 3 years after delivery ($p=0.006$ for mean squeezing pressure) in the five mothers ([Table 2](#)).

Discussion

In the present study occult anal sphincter injuries after vaginal delivery were investigated. Anal sphincter injury after vaginal

delivery is considered as the main and most common factor in pathogenesis of fecal incontinence in healthy young women. These injuries are seen either as obvious and specific injury in terms of clinical (laceration of grade 3 and 4), or as occult anal sphincter injuries which are not obvious after delivery but can be detected by Endo-anal sonography.² Sultan et al. in their studies concluded that sonographic findings for external sphincter injury has 100% accuracy compared to manometry (70%) and electromyography (75%).⁸

We detect the rate of 10% for postpartum sphincter injury prevalence based on Endo-anal sonography. None of these patients maintained clinical findings in terms of gas and fecal incontinence. Occult anal sphincter injuries were reported

Table 2 – Manometry findings in five patients with sphincter injury before delivery and six months and three years after delivery.

Patients	Before delivery		Six month after delivery		Three years after delivery	
	MRP ^a	MSP ^b	MRP ^a	MSP ^b	MRP ^a	MSP ^b
1	72	118	65	93	61	80
2	51	89	39	71	34	62
3	57	96	32	61	28	45
4	63	105	56	75	52	70
5	55	82	31	67	28	74

MRP, mean resting pressure; MSP, mean squeezing pressure.
^a p value of MRP differences: 0.09.
^b p value of MSP differences: 0.006.

12% by Corton et al. in women with primiparity. This frequency of Endo-anal sonography in results of these women after 72 h⁹ is consistent with results of the present study. Carlos Belmonte et al. in 2001 in a study on 98 women with vaginal delivery stated that 20 patients had clinical injury (laceration of grade 3) after delivery. They also reported that 28 (29%) patients had sonographic evidence of sphincter injury without any clinical symptoms.¹⁰ Martinez et al. in 2003, in a study on trauma caused by vaginal delivery in women, stated that 22 patients with mean age 43 years were faced with complication in secondary fecal incontinence, and scar in perineum was found in their tissue examination. Also, injury to anterior portion of external sphincter was observed in 16 (73%) patients and injuries to anterior portion of both external and internal sphincters were observed in 6 (23%) patients.⁷ William et al. in their studies expressed that they had observed 13 (29%) individuals with postpartum trauma. These injuries included external sphincter injury in 5 (11%), puboanal injury in 9 (20%), transverse perineal injury in 3 (7%), and structure injury in 4 patients.¹¹ In the present study anterior portion of external sphincter injury compare to anterior portion of both sphincters was observed in most of patients and is in accordance with past researches.

The average age of participants in our study was higher than average age of all the studied people that can be an indication of high aged mother in primiparity as a risk factor for sphincter injuries, which is compatible with results of Martinez et al. studies in 2003⁷; the average age of 30 years was reported in results of Williams et al.¹¹; but according to statistical tests, the obtained p-values in the present study were not significant and further studies with larger sample size are needed.

The average duration of delivery in these women was 11.5 h, which is higher than the average of duration in total studied women that was 10.5 h. It is in accordance with previous studies that considered a delivery with prolonged second stage as a risk factor.² However, the obtained p-values in the present study were not statistically significant, which it could be due to the inability of the study in evaluation of various phases of delivery. So, the argument in this case would be avoided.

The average birth weight was 3874 g which is higher than the average weight of total newborns that was 3340 g. This proves high weight of newborn as a risk factor for sphincter injuries during delivery. p-Value was significant in this

case. Past researches on perineal trauma by vaginal deliveries also stated that average birth weight is 3245.7 g expressed that high birth weight is associated with anal injuries in vaginal deliveries,¹² which agrees with the present study. In the present study, episiotomy was also performed for all women during delivery. Performance of episiotomy during delivery is a definite risk factor for sphincter injuries, particularly for obvious injury cases. As in studies carried out, it was stated in the past that reducing the use of episiotomy in performed researches was supported and showed that harm of routine episiotomy usage is greater than its benefits.¹³ Also stated that episiotomy is one the risk factors of reduction of normal action of muscles, and it has role in urinary stress incontinence and increase laceration of anal sphincters.¹⁴ In the present study episiotomy method was used for these 5 patients that were not relevant to anal sphincter damage.

The results of this study is limited because of small number of patients and authors suggest same study with large number of patients in future.

Conclusions

Like previous reports it seems that vaginal delivery is a risk factor for anal sphincter injuries. Whether these injuries were symptomatic or asymptomatic Endo-anal sonography should be done for treatment planning. Here we showed that screening Endo-anal sonography could find asymptomatic anal sphincter damages that would become symptomatic in later ages. In order to propose Endo-anal sonography as a screening tool we need further cost benefit studies.

Conflicts of interest

The authors declare no conflicts of interest.

Acknowledgments

The authors would like to thank patients who attend this study. This study was granted by Shiraz Colorectal Research Center; project No. 91-01-69-4566.

REFERENCES

1. Ministry of Health and Medical Education: Office of Family Health and Population. Maternity Health Office. Guideline for obstetric & delivery services in baby friendly hospital. 1st ed. Tehran ChaharsooyeHonar Publishing; 2006 [Article in Persian].
2. Fowler GE. Obstetric anal sphincter injury. *J Assoc Chart Physiother Women's Health*. 2009;104:12-9.
3. Thompson JF, Roberts CL, Currie M, Ellwood DA. Prevalence and persistence of health problems after childbirth: associations with parity and method of birth. *Birth*. 2002;29:83-94.
4. MacArthur C, Glazener CM, Wilson PD, Herbison GP, Gee H, Lang GD, et al. Obstetric practice and faecal incontinence three months after delivery. *BJOG*. 2001;108:678-83.
5. Omidvar A. Behavior change techniques, cognitive-behavioral therapy. Mashhad: Publication Learns Motivation. First Printing; 2006.
6. Zeelha A, Abdul H, Rane T. Ultrasound imaging of the anal sphincter complex. *Br J Radiol*. 2012;85:865-75.
7. Martínez Hernández Magro P, Villanueva Sáenz E, Jaime Zavala M, Sandoval Munro RD, Rocha Ramírez JL. Endoanal sonography in assessment of fecal incontinence following obstetric trauma. *Ultrasound Obstet Gynecol*. 2003;22:616-21.
8. Sultan AH, Kamm MA, Hudson CN, Thomas JM, Bartram CI. Anal-sphincter disruption during vaginal delivery. *N Engl J Med*. 1993;329:1905-11.
9. Corton MM, McIntire DD, Twickler DM, Atnip S, Schaffer JJ, Leveno KJ. Endoanal ultrasound for detection of sphincter defects following childbirth. *Int Urogynecol J*. 2013;24:627-35.
10. Belmonte-Montes C, Hagerman G, Vega-Yepez PA, Hernández-de-Anda E, Fonseca-Morales V. Anal sphincter injury after vaginal delivery in primiparous females. *Dis Colon Rectum*. 2001;44:1244-8.
11. Williams AB, Bartram CI, Halligan S, Spencer JA, Nicholls RJ, Kmiot WA. Anal sphincter damage after vaginal delivery using three-dimensional endosonography. *Obstet Gynecol*. 2001;97 Pt 1:770-5.
12. Zaree OB, Pasha H, Jamali B. Rytgn exercise influence and not touching the perineum are perineal trauma during childbirth. *J Family Health*. 2013;1:29-34 [Article in Persian].
13. Hartmann K, Viswanathan M, Palmieri R, Gartlehner G, Thorp J Jr, Lohr KN. Outcomes of routine episiotomy: a systematic review. *JAMA*. 2005;293:2141-8.
14. Singerrello LB, Harlow BL, Chekos AK, Repke J. Post partum sexual functioning and its relationship to perineal trauma: a retrospective cohort study of primiparous women. *Am J Obstet Gynecol*. 2001;184:881-8.