



Review Article

Genetic profile, risk factors and therapeutic approach of desmoid tumors in familial adenomatous polyposis[☆]



Ana Catarina Ribeiro Freitas^{a,*}, Laura Elisabete Ribeiro Barbosa^{a,b}

^a Universidade do Porto, Faculdade de Medicina, Porto, Portugal

^b Hospital São João, Serviço de Cirurgia Geral, Porto, Portugal

ARTICLE INFO

Article history:

Received 20 December 2016

Accepted 2 April 2017

Keywords:

Desmoid disease, hereditary
Fibromatosis, aggressive
Adenomatous polyposis coli
Risk factors and therapeutics

ABSTRACT

Introduction: Desmoid tumors are the main extraintestinal manifestation of FAP, presenting high morbidity and mortality. It is a neoplasia without metastasis capacity, but with infiltrative growth and with a high rate of recurrence. In familial forms, these tumors are associated with a germinal mutation in the APC gene, with a genotype–phenotype correlation influenced by other risk factors.

Materials and methods: A review of articles published since the year 2000 in Portuguese, English or Spanish on desmoid tumors in patients with FAP was carried out. A total of 49 publications were included.

Results: The site of the mutation in the APC gene is related to the severity of FAP and to the frequency of desmoid tumor. Mutations located distally to codon 1309 are associated with a more attenuated polyposis, but with higher frequency of desmoid tumors. Clinically, these tumors may or may not be symptomatic, depending on their size and location. In their treatment, priority should be given to medical therapy, especially in intra-abdominal tumors, with surgery being the last option if there are no other complications.

Discussion: These tumors are associated with certain risk factors: genetic (mutation site), hormonal (estrogenic environment) and physical (surgical trauma) ones. In young women, a later prophylactic colectomy is suggested. Moreover, the laparoscopic approach to prophylactic surgery seems to be an option that reduces surgical trauma and consequently the appearance of desmoid tumors.

Conclusion: The step-up medical approach has been shown to be valid in the treatment of intra-abdominal desmoid tumors, and medical treatment should be the first therapeutic option.

© 2017 Sociedade Brasileira de Coloproctologia. Published by Elsevier Editora Ltda. This is an open access article under the CC BY-NC-ND license (<http://creativecommons.org/licenses/by-nc-nd/4.0/>).

[☆] Study conducted at Universidade do Porto, Faculdade de Medicina, Departamento de Cirurgia Geral, Porto, Portugal.

* Corresponding author.

E-mail: ana.cat.freitas1@gmail.com (A.C. Freitas).

<http://dx.doi.org/10.1016/j.jcol.2017.04.001>

2237-9363/© 2017 Sociedade Brasileira de Coloproctologia. Published by Elsevier Editora Ltda. This is an open access article under the CC BY-NC-ND license (<http://creativecommons.org/licenses/by-nc-nd/4.0/>).

Perfil genético, fatores de risco e abordagem terapêutica dos tumores desmóides na Polipose Adenomatosa Familiar

R E S U M O

Palavras-chave:

Doença desmoide hereditária
Fibromatose agressiva
Polipose adenomatosa do cólon
Fatores de risco e terapêuticas

Introdução: Os tumores desmóides são a principal manifestação extraintestinal da PAF, apresentando elevada morbimortalidade. É uma neoplasia sem capacidade de metastização, mas com crescimento infiltrativo e com alta taxa de recorrência. Nas formas familiares associa-se a uma mutação germinativa no gene APC, havendo uma correlação genótipo-fenótipo influenciada por outros fatores de risco.

Materiais e métodos: Foi efetuada uma revisão de artigos publicados desde o ano 2000, em português, inglês ou espanhol, acerca de tumores desmóides em doentes com PAF. Foram incluídas, no total, 49 publicações.

Resultados: O local da mutação no gene APC relaciona-se com a gravidade da PAF e frequência de tumor desmóide. Mutações localizadas distalmente ao códon 1309 associam-se a uma polipose mais atenuada, mas a maior frequência de tumor desmóide. Clinicamente podem ser, ou não, sintomáticos, dependendo do seu tamanho e localização. No seu tratamento deve ser dada prioridade à terapêutica médica, sobretudo nos tumores intra-abdominais, colocando a cirurgia como última opção, caso não hajam outras complicações.

Discussão: Estes tumores associam-se a determinados fatores de risco: genéticos (local da mutação), hormonais (ambiente estrogénico) e físicos (trauma cirúrgico). Nas mulheres jovens sugere-se a realização de colectomia profilática mais tardiamente. Além disso, a abordagem laparoscópica para a cirurgia profilática parece ser uma opção que diminui o trauma cirúrgico e conseqüentemente o aparecimento de tumores desmóides.

Conclusão: A abordagem médica em step-up mostrou ser válida no tratamento de tumores desmóides intra-abdominais, devendo o tratamento médico ser a primeira opção terapêutica.

© 2017 Sociedade Brasileira de Coloproctologia. Publicado por Elsevier Editora Ltda. Este é um artigo Open Access sob uma licença CC BY-NC-ND (<http://creativecommons.org/licenses/by-nc-nd/4.0/>).

Introduction

Familial adenomatous polyposis (FAP) is an inherited pathology that results from the autosomal dominant transmission of a germline mutation in the adenomatous polyposis coli (APC) tumor suppressor gene located on the long arm of chromosome 5.

Phenotypically, FAP is characterized by the development of hundreds to thousands of adenomatous polyps in the colon and rectum, with subsequent risk of developing colorectal carcinoma (CRC) if a prophylactic proctocolectomy is not performed.¹

However, even after the proctocolectomy, patients with FAP present higher mortality versus the general population, due to the extra-colic manifestations of this disease: desmoid tumors, upper gastrointestinal tract adenomas, osteomas, and epidermoid cysts, as well as thyroid, adrenal gland, and central nervous system neoplasms.² Of these, desmoid tumors are the most frequent cause of death in patients with FAP.³

Desmoid tumors develop from connective tissue, fasciae, and aponeuroses,^{4,5} corresponding to a monoclonal proliferation of well-differentiated fibroblasts.^{6,7} From the histological point of view, this is considered a benign neoplasm, since it does not have metastization capacity; but biologically, it is a tumor with great local aggressiveness, given the infiltrative growth and the invasion of adjacent structures,⁸ besides

the high rate of local recurrence, even after its resection: 25–65%.^{2,5}

This neoplasm may occur in the context of FAP or may arise sporadically; in this case, the tumor is a result of somatic mutations in the APC gene or in the beta-catenin gene.⁹ Sporadic desmoid tumors are relatively rare, affecting about 2–4 individuals per million in the general population.^{10,11}

As for the familial forms, the development of desmoid tumors is related to a germline mutation in the APC gene, and its frequency is much higher. In fact, it is estimated that between 10 and 25% of patients with FAP will develop at least one desmoid tumor throughout their lives,^{12,13} with a risk 850 times higher than that for the general population.⁵

Regarding the risk factors for the development of desmoid tumors in a FAP context, studies point to several possibilities, such as family history, previous abdominal surgery, and gender, in addition to the site of mutation in the APC gene,^{10,14,15} which is also related to the severity of these tumors.¹⁶

Thus, since the desmoid tumors are one of the most important manifestations of FAP, with high associated morbidity and mortality, and considering that there is no established therapeutic guideline for these tumors, the aim of this review article is to enumerate the various therapeutic options, as well as to order them in a logical sequence, taking into account the characteristics of these tumors, with the purpose of proposing the best approach.

Materials and methods

A literature search through the MEDLINE database via PubMed was performed, and different combinations of terms were used: desmoid disease, hereditary; familial adenomatous polyposis; fibromatosis, familial infiltrative; adenomatous polyposis coli; risk factors and therapeutics.

In this study, the inclusion criteria were publications from the year 2000 and text in Portuguese, English or Spanish. The titles and abstracts were read, with priority given to the most recent and complete articles that corresponded to the proposed objectives. Subsequently, other articles were identified by cross-references of articles obtained in the initial survey. In total, 49 publications were included in this study.

Results

The development of desmoid tumors in patients with FAP is described in several studies as a condition associated with risk factors, namely, a positive family history, previous abdominal surgery, and, more recently, the site of the mutation in the APC gene.¹⁷

In fact, the genotype–phenotype relationship has been analyzed in several studies, and their conclusions are much in the same line: those mutations located distally to codon 1309 and especially at the 3' end are associated with a high risk of developing desmoid tumors, and particularly in a severe form.^{10,18,19}

According to the study by Bertario et al., patients with FAP present a 12-fold higher risk of a desmoid tumor when the mutation is located beyond codon 1444 (“desmoid region”) versus patients whose mutations are located more proximally.¹²

In addition, it has further been shown that the severity of the disease and of the tumor may depend on the site of the mutation. Jean Couture et al.²⁰ showed that mutations at codon 1309 are associated with a severe form of FAP, with the development of polyps and CRC at an earlier age, compared to mutations between codons 1445 and 1578, which are associated with a more attenuated polyposis, but with greater frequency of desmoid tumors.²⁰

On the other hand, currently the function of the APC gene is only partially known; therefore, one cannot maintain that the more distal the mutation, the greater the risk of occurrence of a desmoid tumor. To date, more than 400 germline mutations have been described in this tumor suppressor gene, most of which result in a truncated protein.

Experimental information has shown that mutations in the APC gene have the potential to cause loss of beta-catenin-mediated regulation of signal transduction pathways.¹²

The segment of the APC gene between codons 1265 and 2035 contains the nucleotides that encode the APC protein binding zone to beta-catenin, the binding of which triggers beta-catenin degradation (which functions as a transcription factor). Thus, the integrity of the APC protein is essential, because it was found that the presence of binding sites altered by mutations in the referred segment compromises the degradation of the beta-catenin transcription factor, affecting

cell differentiation, proliferation, and apoptosis, which contributes to the manifestations of FAP.^{10,21}

Depending on their size and location, the desmoid tumors may be clinically asymptomatic or may present manifestations, usually with compressive symptoms. In many patients, intra-abdominal tumors are asymptomatic, appearing as accidental findings on the occasion of a physical or imaging examination. When these tumors reach larger dimensions, they can cause intestinal obstruction, mesenteric ischemia, hydronephrosis, fistulization, and sepsis, among others.^{4,22}

Both computed tomography (CT) and magnetic resonance imaging (MRI) can be used for the detection of desmoid tumors.⁸ However, the confirmation diagnosis is established by histology and by immunohistochemistry.^{23,24} CT has been considered as the gold standard among imaging methods in the assessment of response to treatment. For tumors of small size (<2 cm) or for the follow-up of young patients with an interest in avoiding the radiation effect, MRI may replace CT as a follow-up method, and may also be used to better translate the tumor aggressiveness, by demonstrating the degree of cellularity and vascularization.²²

There is still no protocol for the treatment of these tumors, due to their prevalence and lack of knowledge of their etiology and biology.^{4,25} For the most part, the desmoid tumors grow slowly; but there are situations in which such tumors grow rapidly, being refractory to any treatment.²⁶ In addition, although they do not metastasize, their malignant potential comes mainly from their infiltrative power and relapsing nature.

Although surgery has been the main therapeutic option with curative potential, its use is controversial, since it represents one of the risk factors for the onset and recurrence of these tumors, since the recurrence rate is very high, even in those resections with free margins.¹⁰ Thus, given the lack of an ideal treatment, the therapeutic decision becomes a true clinical challenge, often requiring a multidisciplinary approach.

Currently, the proposed therapies can be divided into four different groups: pharmacological treatment, radiotherapy, chemotherapy, and surgery.²²

One of the possibilities of medical treatment is the use of non-steroidal anti-inflammatory drugs (NSAIDs), since several studies have shown an efficacy rate close to 50% in reducing desmoid tumors.^{1,8} Currently, sulindac and celecoxib are the pharmacological agents used. Studies suggest that the first choice for medical treatment should be one of the NSAIDs and, in the case of failure, the option would be a combination of NSAIDs with hormonal treatment.^{1,8,27}

In fact, hormonal agents are another proposed therapy for these tumors, considering that the higher incidence in females, the association with oral contraceptive use, and the higher growth of tumors in pregnant women seem to speak in favor of the role of estrogens. In their appearance and growth.^{28–31} In addition, the fact that this type of fibromatosis is more common in women of childbearing age, regressing with menopause or after oophorectomy, serves to confirm this relationship.^{29,31}

Tamoxifen and toremifene are the antiestrogen agents that have been more widely used.^{1,27,29} According to Bocale et al.,²⁹ desmoid tumors frequently respond to endocrine therapy; moreover, the fact of not obtaining a response with the use

of one of these agents does not imply failure with the others. According to the available data, the efficacy of tamoxifen is the same as for toremifene; However, in some cases, this latter agent appears to be effective as second line therapy, after the occurrence of resistance to tamoxifen. The study also shows that antiestrogen therapy works on both FAP-associated tumors and on sporadic tumors and, similarly, on primary or recurrent tumors.²⁹

Clinically, this hormone therapy does not appear to have relevant side effects, including in men; thus, this option can be used. In women with long-term treatment, frequent changes in their menstrual cycle are observed; in such cases, endovaginal ultrasound is recommended.²⁹

This and other studies also emphasize the fact that tamoxifen and other antiestrogen agents produce a response, even in estrogen receptor-free desmoid tumors.^{29,30,32}

Thus, it is proposed that, in recurrent desmoid tumors, preference should be given to tamoxifen therapy, rather than radiotherapy or surgical re-exploration. Especially in young women, tamoxifen should be considered as the initial choice because this agent contributes to a greater possibility of preserving their fertility.³⁰

All in all, the medical treatment encompasses the use of NSAIDs alone or in combination with hormonal agents, as well as the monotherapy with these latter agents.

Some studies have compared treatments for desmoid tumors (associated with FAP, or sporadic ones) and have reached to a significantly higher percentage of total or partial remission with the exclusive use of hormonal agents compared to their association with NSAIDs. It appears that the NSAID + anti-estrogen combination did not add any benefit to the treatment, although there have been other reports of successful cases with the use of NSAID as monotherapy.²⁹ This allows us to conclude that there are still uncertainties regarding the biological and therapeutic behavior of these tumors.

Currently, combined therapies are used mainly in cases of inoperable tumors and also in situations of post-surgical recurrences and in the perioperative period.³³ However, this may be a valid option for intra-abdominal tumors, which would allow avoiding surgical trauma.

Another alternative therapy to surgery is radiation therapy. The study by Nuytens et al., involving cases treated only with surgery, with surgery associated with radiotherapy, and only with radiotherapy, demonstrated a control rate of 61%, 78%, and 75%, respectively.³⁴

In addition, Turina et al.³⁵ suggest a good control of large unresectable desmoid tumors with radiotherapy/brachytherapy. Brachytherapy is another proposed option; for its use, the tumors must be of an adequate size, in order to be correctly exposed to the applicators.³⁵

Although there is some controversy, there is evidence that radiotherapy can model fibrosis, with increasing evidence favoring a decrease in the percentage of local recurrence with the use of this option, both before and after surgery.^{1,24}

Studies also confirm the important role that radiotherapy can play in the treatment of unresectable tumors with extra-abdominal location and in the abdominal wall, as well as in the post-surgical treatment of cases with positive margins.⁸ But intra-abdominal tumors appear to have lower radiosensitivity,

and this makes radiotherapy rarely used in tumors with this location; besides, is also the risk of a radiation enteritis.¹

Another therapeutic option is chemotherapy. Low doses of doxorubicin in combination with dacarbazine, as well as the combination of methotrexate + vinblastine, also at low doses, have demonstrated efficacy in the treatment of tumors with progressive growth and no response to medical therapy.^{8,27,36}

One of the examples is described in the study by Toiyama et al.,³⁷ which shows the efficacy of a low-dose combination regimen of methotrexate and vinblastine in a 26-year-old patient with a mesenteric desmoid tumor. The patient was treated with the above-mentioned regimen twice a week for 12 months, and the authors noted a decrease in tumor size with subsequent regression and with no significant side effects.³⁷

Therefore, chemotherapy may be considered as a therapeutic option in tumors that show a progression after other therapies. Regarding the possible therapeutic regimens, the combinations doxorubicin + dacarbazine and methotrexate + vinblastine have been used more often; but other effective combinations, such as cyclophosphamide + doxorubicin, or even the combination of doxorubicin with the monoclonal antibody imatinib, have been described.³⁵ It seems that the latter agent may also play an important role in the treatment of these tumors.³⁸

Finally, with respect to surgery: until now, this is the therapeutic standard, although much of the literature does not recommend the surgical solution as the first line of treatment, especially in patients with intra-abdominal tumors.^{2,5} For tumors with this location, the low rate of complete resection and, consequently, the high percentage of recurrences and morbidity, make surgery an option that is increasingly relegated to the end of the line of treatments. Due to the potential morbidity and mortality, for example, hemorrhage, short bowel syndrome, or even postoperative death, studies suggest that surgery should only be considered in patients with desmoid tumors resistant to medical treatment or in palliative situations, in order to control the symptoms caused by their progression, such as intestinal occlusion, ischemia and enteric fistulization, and hydronephrosis, among others.^{4,39} On the other hand, in tumors of the abdominal wall or with an extra-abdominal location, surgery may be an appropriate treatment.⁴⁰

Thus, intra-abdominal desmoid tumors should be approached according to a step-up strategy, that is, with the progression of the aggressiveness of the treatment in function of the evolution of the disease.²² According to Latchford et al.,¹ the treatment of intra-abdominal tumors should be started with sulindac (150 mg); if this treatment is not effective, an anti-hormonal agent should be combined: toremifene (180 mg) or tamoxifen (120 mg). Having tumor progression, chemotherapy should be the next choice (low dose of vinblastine + methotrexate). Therefore, surgery should be reserved for severe complications.¹

Discussion

Desmoid tumors may arise sporadically or as an extra-intestinal manifestation of FAP. In sporadic cases, there are somatic mutations in the beta-catenin gene, with its

overexpression in the nuclei; on the other hand, in cases of FAP, a germline mutation is present in the desmoid region of the APC gene.⁴¹

This is a group of heterogeneous tumors, ranging from small mesenteric plaques to desmoid tumors that occupy the entire abdominal cavity, and may still present themselves with a little aggressive character or, on the contrary, with great local aggressiveness and a rapid infiltrative growth.

Histologically, the tumor is composed mainly of highly differentiated fibroblasts with an elongated nucleus; consequently, they rarely metastasize.³³ In patients with FAP, this type of tumor tends to arise mainly in the mesentery of the small intestine, followed, in order of prevalence, by the abdominal wall and finally, the extremities and the trunk. These latter regions are rare locations, in a context of FAP.¹⁰

Clinically, these tumors represent the most relevant extra-colonic manifestation of FAP, given the associated morbidity and mortality (second cause of death, shortly after CRC). Etiologically, we do not yet have a theory to explain the origin of these tumors; however, it has been shown that mutations in the APC gene predispose to the development of fibromatosis (genetic factor), as well as to hormonal and physical factors.⁴² Regarding the latter, it is verified that, after the surgical intervention, a disproportionate inflammatory response to the trauma is noted, consequently with an accumulation of fibroblasts.³³ There is evidence implicating surgical trauma as one of the factors capable of leading to the development of this type of tumor, and there is no correspondence with a specific type of surgery. The frequency of desmoid tumors in patients undergoing proctocolectomy procedures is similar to that in patients treated by partial colectomy or by colectomy with ileorectal anastomosis.¹²

In fact, in patients with FAP treated with prophylactic colectomy, the mortality comes mainly from the desmoid tumors. During the first 5 years after surgery, one in six patients develops a desmoid tumor, usually with an intra-abdominal location.

In this sense, Vitellaro et al.⁴³ investigated whether laparoscopic surgery was associated with a lower tumor risk when compared to open surgery. With the two study groups showing similar characteristics before surgery, in a 5-year follow-up period, the authors observed a lower incidence of desmoid tumors in the group undergoing laparoscopic surgery. However, given the reduced size of this series and the limited follow-up period, this study points only to the possibility that laparoscopic surgery reduced the risk of occurrence of a desmoid tumor after prophylactic colectomy in patients with FAP.⁴³

Another study also shows that in cases of prophylactic surgery with an ileorectal anastomosis, the laparoscopic approach results in fewer complications and faster recovery.⁴⁴

Thus, it is concluded that laparoscopic surgery may reduce the risk of these tumors; however, further studies are needed, so that this type of surgery may be the recommended procedure.

Regarding the genetic factor, it has already been shown that mutations in the APC gene are apparently the single most important risk factor for the onset of the desmoid tumor in patients with FAP.¹² According to Speake et al.⁴⁵ 85% of the mutations in the APC gene are located between codons 1250

and 1464, and correspondence was found between the mutation site and FAP severity and frequency of desmoid tumors, which agrees with findings in other studies. In situations of an attenuated FAP, mainly associated with mutations at the 3' end, a greater tendency is observed for desmoid tumors. Considering this inverse relationship, the study concludes that, in patients with mutations in this location, abdominal surgery represents a great risk for the development of desmoid tumors, proposing that, in cases of attenuated FAP, the best prophylactic strategy would be an endoscopic surveillance of polyps. In cases of patients with this mutation, but who show signs of progression of the polyps, even after an attempt of endoscopic control, or in the face of the presence of a carcinoma, surgery becomes essential.⁴⁵ However, it is advisable to adopt chemoprophylaxis (with sulindac or tamoxifen), in order to try to control the risk of developing a desmoid tumor, thus improving the post-surgical prognosis.⁴⁶

Despite advances in genetic knowledge and surgical techniques, the type and timing of a prophylactic surgery remain uncertain. On the one hand, the sooner the surgery is performed, the greater the chances of CRC prevention; on the other hand, some authors have suggested that, in young women, prophylactic colectomy should be considered later, since these patients are at a higher risk for the development of desmoid tumors if the surgery is performed at an earlier age.^{43,47,48}

Moreover, it has been demonstrated that, in comparison to male patients, women are at increased risk of developing tumors after surgery – a fact which proves that in an estrogenic environment, surgical trauma is a predisposing factor for the onset of these tumors in females.^{10,12} In fact, the development of desmoid tumors before the surgery is more frequent in male patients. This finding suggests that, in males, the site of the mutation in APC gene is the factor with the greatest influence on the appearance of the tumor, with a lower correlation with surgical trauma.¹² The study also shows that in the female group with FAP the desmoid tumors were more frequent, but that the male patients, when affected, tended to present tumors with more aggressive characteristics, of greater dimensions and with more frequency of location in the abdominal wall, compared with the female group.¹²

Therefore, there are significant gender differences in the manifestation of desmoid tumors. Female patients are at higher risk of tumor occurrence, regardless of the site of the mutation, while in the male gender the site of the mutation seems to exert a greater influence. The reasons for these differences may be explained by the different impact of the risk factors: surgical trauma, hormonal influence, and location of the mutation.

Considering all these points, and despite the prognostic uncertainty and the lack of knowledge regarding which treatment is most effective, it is possible to propose a therapeutic approach for desmoid tumors. According to the literature, this approach should be progressive in the case of intra-abdominal tumors, and preferably the initial approach will be through medical treatment. Therefore, the treatment should begin with the administration of sulindac and, if this medication is not sufficient, an anti-hormonal agent (tamoxifen or toremifene) will be added. In cases where there is still

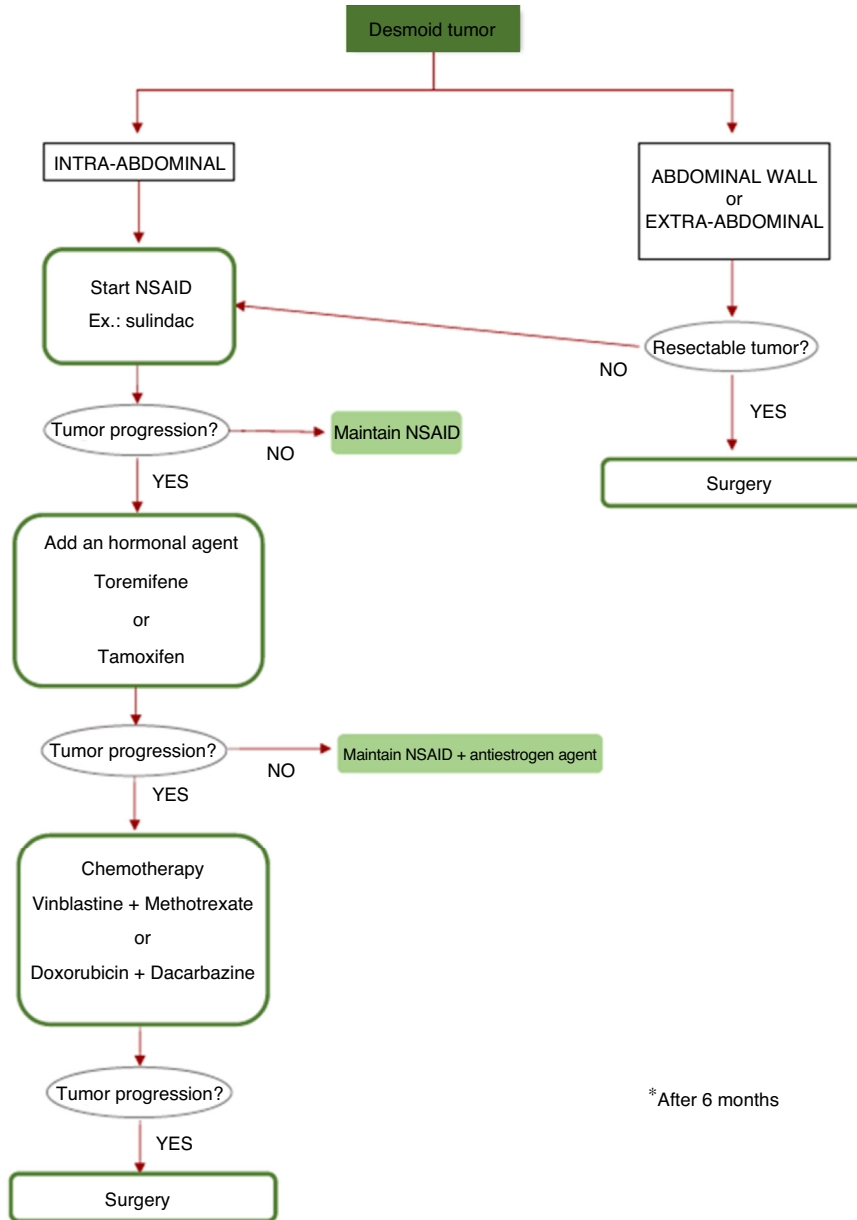


Fig. 1 – Therapeutic approach.

tumor progression, chemotherapy should be started. Thereby, surgery will be the last option (Fig. 1).

Conclusion

FAP-associated desmoid tumors arise after a prophylactic colectomy and affect mainly female patients. However, when these tumors arise in men, they tend to be more severe, not having a direct relation to the surgical intervention.

Mutations at the 3' end of the APC gene, and especially mutations beyond codon 1444, are phenotypically correlated with less polyposis (attenuated FAP), but also with a higher risk of developing the tumor. Since the surgical aggression inherent to a procedure of prophylactic colectomy is an

important risk factor for the development of this type of tumor, it is questioned whether the endoscopic surveillance of polyps is an adequate measure as a prophylactic strategy for colic carcinoma. In cases in which such a measure is not possible, the laparoscopic approach seems to present better preventive results.

The lack of randomized prospective studies and the small size of the series published do not allow the establishment of a universal therapeutic protocol for desmoid tumors; however, it is possible to propose a step-up medical approach, which has been shown to be valid in the treatment of FAP-associated intra-abdominal desmoid tumors. Medical treatment should be the first line of approach, and surgery should be reserved for situations of medical therapy failure or of complications.

Conflicts of interest

The authors declare no conflicts of interest.

REFERENCES

- Latchford AR, Sturt NJ, Neale K, Rogers PA, Phillips RK. A 10-year review of surgery for desmoid disease associated with familial adenomatous polyposis. *Br J Surg*. 2006;93:1258–64.
- Righetti AE, Jacomini C, Parra RS, Almeida AL, Rocha JJ, Feres O. Familial adenomatous polyposis and desmoid tumors. *Clinics*. 2011;66:1839–42.
- Seow-Choen F. The management of desmoids in patients with familial adenomatous polyposis (FAP). *Acta Chir Iugosl*. 2008;55:83–7.
- Tanaka K, Toiyama Y, Okugawa Y, Hiro J, Kawamoto A, Inoue Y, et al. Cytoreductive strategy for multiple intra-abdominal and abdominal wall desmoid tumors in familial adenomatous polyposis: report of three cases. *Clin J Gastroenterol*. 2012;5:361–6.
- Ferenc T, Sygut J, Kopczyński J, Mayer M, Latos-Bielenska A, Dziki A, et al. Aggressive fibromatosis (desmoid tumors): definition, occurrence, pathology, diagnostic problems, clinical behavior, genetic background. *Pol J Pathol*. 2006;57:5–15.
- Colombo C, Foo WC, Whiting D, Young ED, Lusby K, Pollock RE, et al. FAP-related desmoid tumors: a series of 44 patients evaluated in a cancer referral center. *Histol Histopathol*. 2012;27:641–9.
- Fiore M, Rimareix F, Mariani L, Domont J, Collini P, Le Péchoux C, et al. Desmoid-type fibromatosis: a front-line conservative approach to select patients for surgical treatment. *Ann Surg Oncol*. 2009;16:2587–93.
- Pikaar A, Nortier JW, Griffioen G, Vasen HF. Desmoid tumors in patients with familial adenomatous polyposis. *Ned Tijdschr Geneesk*. 2002;146:1355–9.
- Leal RF, Silva PV, Arizonzo Mde L, Fagundes JJ, Amstalden EM, Coy CS. Desmoid tumor in patients with familial adenomatous polyposis. *Arq Gastroenterol*. 2010;47:373–8.
- Schiessling S, Kihm M, Ganschow P, Kadmon G, Buchler MW, Kadmon M. Desmoid tumour biology in patients with familial adenomatous polyposis coli. *Br J Surg*. 2013;100:694–703.
- Fallen T, Wilson M, Morlan B, Lindor NM. Desmoid tumors – a characterization of patients seen at Mayo Clinic 1976–1999. *Fam Cancer*. 2006;5:191–4.
- Bertario L, Russo A, Sala P, Eboli M, Giarola M, D’Amico F, et al. Genotype and phenotype factors as determinants of desmoid tumors in patients with familial adenomatous polyposis. *Int J Cancer*. 2001;95:102–7.
- Friedl W, Caspari R, Sengteller M, Uhlhaas S, Lamberti C, Jungck M, et al. Can APC mutation analysis contribute to therapeutic decisions in familial adenomatous polyposis? Experience from 680 FAP families. *Gut*. 2001;48:515–21.
- Sinha A, Tekkis PP, Gibbons DC, Phillips RK, Clark SK. Risk factors predicting desmoid occurrence in patients with familial adenomatous polyposis: a meta-analysis. *Colorectal Dis*. 2011;13:1222–9.
- Lefevre JH, Parc Y, Kerneis S, Goasguen N, Benis M, Parc R, et al. Risk factors for development of desmoid tumours in familial adenomatous polyposis. *Br J Surg*. 2008;95:1136–9.
- Church J, Xhaja X, LaGuardia L, O’Malley M, Burke C, Kalady M. Desmoids and genotype in familial adenomatous polyposis. *Dis Colon Rectum*. 2015;58:444–8.
- Nieuwenhuis MH, Lefevre JH, Bulow S, Jarvinen H, Bertario L, Kerneis S, et al. Family history, surgery, and APC mutation are risk factors for desmoid tumors in familial adenomatous polyposis: an international cohort study. *Dis Colon Rectum*. 2011;54:1229–34.
- Sturt NJ, Gallagher MC, Bassett P, Philp CR, Neale KF, Tomlinson IP, et al. Evidence for genetic predisposition to desmoid tumours in familial adenomatous polyposis independent of the germline APC mutation. *Gut*. 2004;53:1832–6.
- Fearnhead NS, Britton MP, Bodmer WF. The ABC of APC. *Hum Mol Genet*. 2001;10:721–33.
- Couture J, Mitri A, Lagace R, Smits R, Berk T, Bouchard HL, et al. A germline mutation at the extreme 3’ end of the APC gene results in a severe desmoid phenotype and is associated with overexpression of beta-catenin in the desmoid tumor. *Clin Genet*. 2000;57:205–12.
- Groen EJ, Roos A, Muntinghe FL, Enting RH, de Vries J, Kleibeuker JH, et al. Extra-intestinal manifestations of familial adenomatous polyposis. *Ann Surg Oncol*. 2008;15:2439–50.
- Martins S, Leite J, Oliveira A, Sá A, Castro-Sousa F. Tratamento dos tumores desmóides intra-abdominais associados à Polipose Adenomatosa Familiar. *Rev Port Cir*. 2015;32:17–25.
- Vida Perez L, Martinez Rivas F. Intraabdominal desmoid tumors. *Med Clin*. 2013;141:314–9.
- Palacios-Zertuche JT, Cardona-Huerta S, Juarez-Garcia ML, Valdes-Flores E, Munoz-Maldonado GE. Case report: rapidly growing abdominal wall giant desmoid tumour during pregnancy. *Cir Cir*. 2016, <http://dx.doi.org/10.1016/j.circir.2016.04.004>.
- Wong SL. Diagnosis and management of desmoid tumors and fibrosarcoma. *J Surg Oncol*. 2008;97:554–8.
- Sakorafas GH, Nissotakis C, Peros G. Abdominal desmoid tumors. *Surg Oncol*. 2007;16:131–42.
- Basdanis G, Papadopoulos VN, Panidis S, Tzeveleki I, Karamanlis E, Mekras A, et al. Desmoid tumor of mesentery in familial adenomatous polyposis: a case report. *Tech Coloproctol*. 2010;14:S61–2.
- Church J, Lynch C, Neary P, LA Guardia L, Elayi E. A desmoid tumor staging system separates patients with intraabdominal, familial adenomatous polyposis-associated desmoid disease by behavior and prognosis. *Dis Colon Rectum*. 2008;51:897–901.
- Bocale D, Rotelli MT, Cavallini A, Altomare DF. Anti-oestrogen therapy in the treatment of desmoid tumours: a systematic review. *Colorectal Dis*. 2011;13:e388–95.
- Ohashi T, Shigematsu N, Kameyama K, Kubo A. Tamoxifen for recurrent desmoid tumor of the chest wall. *Int J Clin Oncol*. 2006;11:150–2.
- Jenayah AA, Bettaieb H, Saoudi S, Gharsa A, Sfar E, Boudaya F, et al. Desmoid tumors: clinical features and treatment options: a case report and a review of literature. *Pan Afr Med J*. 2015;21:93.
- Chao AS, Lai CH, Hsueh S, Chen CS, Yang YC, Soong YK. Successful treatment of recurrent pelvic desmoid tumour with tamoxifen: case report. *Hum Reprod*. 2000;15:311–3.
- Nagano S, Passos R, Santana M, Guedes V. Tumor desmoide – Uma revisão de literatura. *Rev Pat Tocantins*. 2015;2:2–7.
- Nuyttens JJ, Rust PF, Thomas CR, Turrisi AT. Surgery versus radiation therapy for patients with aggressive fibromatosis or desmoid tumors. *Cancer*. 2000;88:1517–23.
- Turina M, Pavlik CM, Heinemann K, Behrensmeier F, Simmen HP. Recurrent desmoids determine outcome in patients with Gardner syndrome: a cohort study of three generations of an APC mutation-positive family across 30 years. *Int J Colorectal Dis*. 2013;28:865–72.
- Okuno SH, Edmonson JH. Combination chemotherapy for desmoid tumors. *Cancer*. 2003;97:1134–5.
- Toiyama Y, Konishi N, Inoue Y, Yoshiyama S, Araki T, Miki C, et al. Successful treatment of ileal pouch desmoids using multimodal chemotherapy with low-dose vinblastine and

- methotrexate in a patient with familial adenomatous polyposis. *Clin J Gastroenterol*. 2009;2:170–4.
38. Chugh R, Wathen JK, Patel SR, Maki RG, Meyers PA, Schuetze SM, et al. Efficacy of imatinib in aggressive fibromatosis: results of a phase II multicenter Sarcoma Alliance for Research through Collaboration (SARC) trial. *Clin Cancer Res*. 2010;16:4884–91.
39. Nieuwenhuis MH, Mathus-Vliegen EM, Baeten CG, Nagengast FM, van der Bijl J, van Dalsen AD, et al. Evaluation of management of desmoid tumours associated with familial adenomatous polyposis in Dutch patients. *Br J Cancer*. 2011;104:37–42.
40. Jung WB, Kim CW, Kim JC. Clinical characteristics adequate treatment of familial adenomatous polyposis combined with desmoid tumors. *Cancer Res Treat*. 2014;46:366–73.
41. Fisher C, Thway K. Aggressive fibromatosis. *Pathology*. 2014;46:135–40.
42. Okuno S. The enigma of desmoid tumors. *Curr Treat Options Oncol*. 2006;7:438–43.
43. Vitellaro M, Sala P, Signoroni S, Radice P, Fortuzzi S, Civelli EM, et al. Risk of desmoid tumours after open and laparoscopic colectomy in patients with familial adenomatous polyposis. *Br J Surg*. 2014;101:558–65.
44. McNicol FJ, Kennedy RH, Phillips RK, Clark SK. Laparoscopic total colectomy and ileorectal anastomosis (IRA), supported by an enhanced recovery programme in cases of familial adenomatous polyposis. *Colorectal Dis*. 2012;14:458–62.
45. Speake D, Evans DG, Lalloo F, Scott NA, Hill J. Desmoid tumours in patients with familial adenomatous polyposis and desmoid region adenomatous polyposis coli mutations. *Br J Surg*. 2007;94:1009–13.
46. Sturt NJ, Phillips RK, Clark SK. High-dose tamoxifen and sulindac as first-line treatment for desmoid tumors. *Cancer*. 2004;101:652.
47. Mendenhall WM, Zlotecki RA, Morris CG, Hochwald SN, Scarborough MT. Aggressive fibromatosis. *Am J Clin Oncol*. 2005;28:211–5.
48. Durno C, Monga N, Bapat B, Berk T, Cohen Z, Gallinger S. Does early colectomy increase desmoid risk in familial adenomatous polyposis. *Clin Gastroenterol Hepatol*. 2007;5:1190–4.