



Case Report

Perianal leiomyoma[☆]



**Bruna Fernandes dos Santos^{a,*}, Lucas Rodrigues Boarini^a, Pietro Dadalto Oliveira^a,
Fernanda Belotti Formiga^a, Galdino José Sitonio Formiga^a,
Anderson da Costa Lino Costa^{a,b}**

^a Hospital Heliópolis, Serviço de Coloproctologia, São Paulo, SP, Brazil

^b Hospital Heliópolis, Serviço de Anatomia Patológica, São Paulo, SP, Brazil

ARTICLE INFO

Article history:

Received 18 September 2016

Accepted 27 March 2017

Available online 10 May 2017

Keywords:

Gastrointestinal neoplasia
Gastrointestinal stromal tumors
Leiomyoma
Anal canal

ABSTRACT

Leiomyomas are smooth muscle tumors and may occur in places where these fibers are present, while the anorectal location is rare. They are commonly incidental imaging findings and in most cases, patients are asymptomatic. The therapeutic recommendation is tumor resection and postoperative follow-up. Case report: a 38-year-old Black woman had, one year ago, a swelling in perianal right region, which showed slow and progressive growth. She denied bowel habit alterations, local pain, hematochezia, or tenesmus. Proctologic examination showed a fibroelastic, regular, mobile, painless nodule measuring 10 cm at its largest diameter in the right perianal region, next to the anal verge. The soft tissue ultrasound image identified a solid, hypoechoic, and discreetly vascularized nodule in the perianal, superficial right gluteal region that did not reach the adjacent muscles. A complete resection of perineal tumor was carried out in the ventral position. Histological and immunohistochemical analyses disclosed a leiomyoma with a positive finding for actin smooth muscle and negative for desmin. She is currently asymptomatic and undergoing outpatient follow-up.

© 2017 Sociedade Brasileira de Coloproctologia. Published by Elsevier Editora Ltda. This is an open access article under the CC BY-NC-ND license (<http://creativecommons.org/licenses/by-nc-nd/4.0/>).

Leiomioma de localização perianal

RESUMO

Os leiomiomas são tumores da musculatura lisa podendo ocorrer nos locais onde essas fibras estão presentes, sendo rara a localização anorretal. Na maioria dos casos os pacientes são assintomáticos, sendo comumente achados de exame de imagem. A recomendação terapêutica é a ressecção tumoral e o seguimento pós-operatório. Relato do caso: mulher, 38 anos, negra. Há um ano, apresentou abaulamento em região perianal direita, de crescimento lento e progressivo. Negava alteração do hábito intestinal, dor local, hematoquezia, puxo ou

Palavras-chave:

Neoplasias gastrointestinais
Tumores do estroma
gastrointestinal
Leiomioma
Canal anal

[☆] Study carried out at Hospital Heliópolis, Serviço de Coloproctologia, São Paulo, SP, Brazil.

* Corresponding author.

E-mail: bruhbb@hotmail.com (B.F. Santos).

<http://dx.doi.org/10.1016/j.jcol.2017.03.003>

2237-9363/© 2017 Sociedade Brasileira de Coloproctologia. Published by Elsevier Editora Ltda. This is an open access article under the CC BY-NC-ND license (<http://creativecommons.org/licenses/by-nc-nd/4.0/>).

tenesmo. Ao exame proctológico, apresentava nodulação fibroelástica, regular, móvel, indolor, com 10 cm de diâmetro em região perianal à direita, próxima à borda anal. Realizou ultrassonografia de partes moles que identificou imagem nodular, sólida, hipocogênica e discreta vascularização em parte superficial perianal e glútea direita, não envolvendo musculatura adjacente. Foi submetida à ressecção completa do tumor via perineal, em posição ventral. O laudo histológico e imuno-histoquímico revelou leiomioma, com achado positivo para actina de músculo liso e negativo para desmina. Atualmente está assintomática, em seguimento ambulatorial.

© 2017 Sociedade Brasileira de Coloproctologia. Publicado por Elsevier Editora Ltda. Este é um artigo Open Access sob uma licença CC BY-NC-ND (<http://creativecommons.org/licenses/by-nc-nd/4.0/>).

Introduction

Leiomyomas are tumors that originate from the smooth muscle and may occur at the sites where these fibers are present.¹ In the digestive tract, the most common presentation is in the stomach, followed by the small intestine, being unusually found in the anorectal region, where they represent less than 0.1% of the tumors of the rectum, with a rare presentation in soft parts, mainly in the perianal topography.²⁻⁴

In the literature, the perianal leiomyoma finding is rare: isolated cases have been described, and the most common presentation is a painless tumor in this location.²

To illustrate such condition, the authors report a well-documented case and discuss clinical aspects together with literature data.

Case report

A 38-year-old Black female presented with a swelling in the right perianal region, of slow and progressive growth since a year before. She denied changes in the intestinal habits, local pain, hematochezia, feeling of incomplete defecation or tenesmus. At the proctological examination, she had a fibroelastic, regular, mobile, painless nodule with 10 cm in diameter in the right perianal region, near the anal verge. She was submitted to a soft tissue ultrasonography, which identified a nodular, solid, hypoechogenic and discretely vascularized image in the superficial perianal and right gluteal area, not reaching the adjacent musculature.

In the ventral position, she underwent local anesthesia with sedation and complete resection of perianal tumor (Figs. 1 and 2). The histological and immunohistochemical report disclosed a leiomyoma, with a positive finding for actin and negative for desmin (Fig. 3).

Discussion

First described by Virchow in 1854, and histologically confirmed by Malassez, in 1872, leiomyomas are benign tumors of mesenchymal origin and can develop where the smooth muscle is present.^{3,5} They are more common in the female genital tract and skin. In the anorectal region, they represent only 3% of all leiomyomas of the gastrointestinal tract and less than 0.1% of rectum tumors, rarely found in soft tissues, mainly in

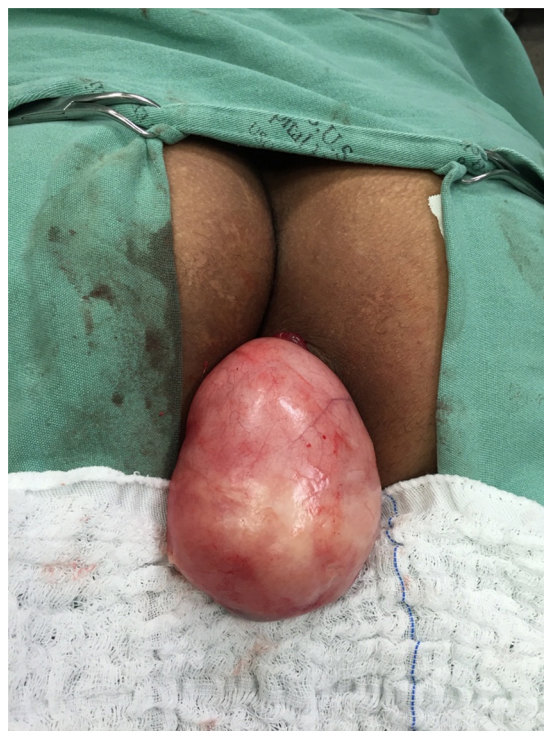

Fig. 1 – Patient in the ventral position with tumor extrusion from the perianal region on the right, near the anal verge.

the perianal area, where the incidence is 3.8% of all benign tumors of soft tissues.^{6,7}

Historically, gastrointestinal mesenchymal tumors were called benign (leiomyoma) or malignant (leiomyosarcoma). Recently, gastrointestinal stromal tumors (GIST) have been considered the best terminology. They are differentiated by immunohistochemical staining, in which a leiomyoma exhibits positivity for smooth muscle actin and negativity for CD117 and CD34 (c-Kit). Desmin may be absent or be expressed later.^{5,8} Histological patterns are similar to those of the leiomyosarcoma, but these have a higher degree of cellular atypia with local pleomorphism and increased mitotic activity. There are no well-established criteria to determine malignancy in these tumors, with some characteristics suggesting a malignant behavior: tumor size (>5 cm), histological appearance (necrosis, ulceration, or cells with atypia) and

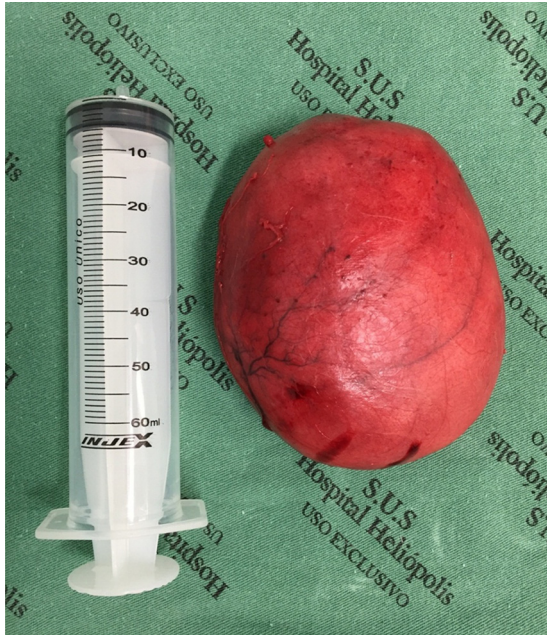

Fig. 2 – Surgical specimen after tumor resection.

increased number of mitoses (>2 mitoses per field, with a 10× increase).^{3,9}

The literature has scarce reports of perianal leiomyomas: isolated cases are described, and there is no specific symptom, but when present, the most common presentation is a painless perianal tumor. Other clinical manifestations include: local pain associated or not with defecation, foreign body sensation, altered intestinal habits and rectal bleeding, which vary according to the size, location and direction of tumor growth.^{3,10}

They are classified into two main variants: superficial, represented mainly by angioleiomyoma of the female genital tract; and deep, initially described by Kilpatrick et al. and Billings et al. in 1994 and 2001, respectively. It is subdivided into somatic, which affects both genders and extremities (mainly the thigh) and retroperitoneal, which occurs

preferentially in women during the menopause period, in a pelvic retroperitoneal location.^{4,5}

Preoperative diagnosis is difficult because most patients are asymptomatic, being commonly identified during endoscopic and imaging examinations. Biopsy is often not informative, because it does not involve the entire tumor, impairing the full evaluation of the histological characteristics.^{8,11} Every perianal tumor needs a definitive diagnosis, given the importance of a differential diagnosis with malignant tumors of the rectum, anal and perianal canal, such as: leiomyosarcoma, GISTs, liposarcomas, fibrosarcomas and carcinoids. Therefore, a proctological examination should be performed, and complementary examinations, such as perianal ultrasonography of soft or endoanal tissues, computed tomography, magnetic resonance imaging and colonoscopy may be used.^{8,10,12}

The treatment of the perianal leiomyoma consists in the complete surgical resection, ensuring tumor-free margins, with the excisional biopsy being diagnostic and therapeutic, since the histological analysis is necessary for its confirmation. Anterior resection or abdominoperineal amputation should be performed in cases where local resection is impossible due to tumor size or sphincter muscle infiltration.^{3,4} The recurrence rate is low when complete local excision is performed, but the extended postoperative follow-up with clinical and complementary examinations is important to confirm the absence of the disease or to detect any recurrences and/or malignant transformation.^{3,5,10}

The patient showed swelling in the right perianal region, painless, with no other associated symptoms, similar to most of the presentations described by other authors.^{2,3,8,10} After proctological examination and soft tissue perianal ultrasonography, she was submitted to complete tumor resection and postoperative follow-up, as recommended in the literature.

Final considerations

All perianal lesions need a definitive diagnosis. Excisional biopsy is the gold standard for the circumscribed tumor lesions and the finding of a leiomyoma is rare in this topography.

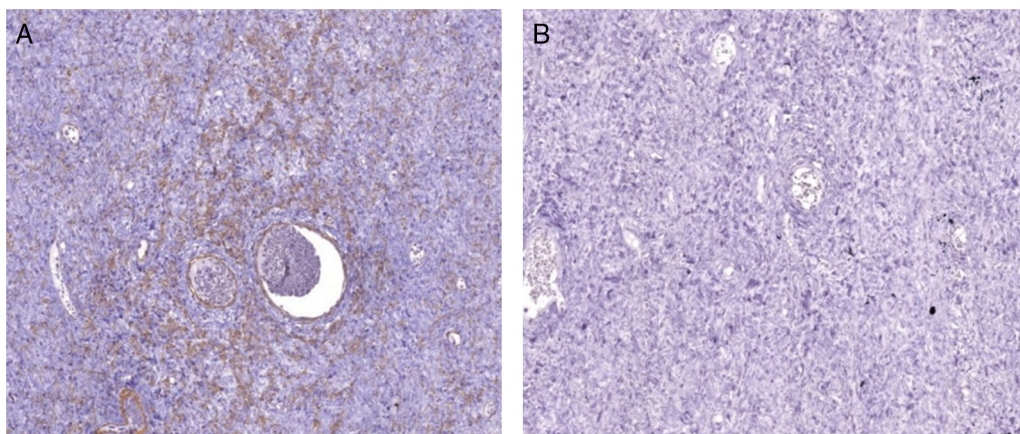


Fig. 3 – Immunohistochemical analysis showing mesenchymal neoplasm with fibrillar pattern positive for smooth muscle actin (A) and negative for desmin (B).

Conflicts of interest

The authors declare no conflicts of interest.

REFERENCES

1. Salame G, Sherer DM, Zinn HL, Abulafia O. Large extraluminal leiomyoma of the rectum in a patient presenting with decreasing stool caliber. *J Ultrasound Med*. 2011;30:1437-43.
2. Bronx-Jiménez A, Díaz-Gómez D, Martínez-García P, Parra-Membrives P. Leiomioma de localización perineal. *Cir Esp*. 2007;82:51-7.
3. Silva RDP, Saad-Hossne R, Ferraz RA, Matsushita MM, Falzoni R, Teixeira FV. Treatment of rectal leiomyoma by endoscopic resection. *J Coloproctol*. 2011;31:382-6.
4. García-Santos EP, Ruescas-García FJ, Estaire-Gómez M, Martín-Fernández J, González-López L. Anorectal leiomyoma: a case report and literature review. *Ver Gastroenterol Mex*. 2014;79:58-66.
5. Dasari BVM, Khosraviani K, Irwin ST, Scott M. Perianal leiomyoma involving the anal sphincter. *Ulster Med J*. 2007;76:173-4.
6. De Palma GD, Rega M, Masone S, Siciliano S, Persico M, Salvatori F, et al. Lower gastrointestinal bleeding secondary to a rectal leiomyoma. *World J Gastroenterol*. 2009;15:1769-70.
7. Brito LGO, Motoki LF, Magnani PS, Sabino-de-Freitas MM, Landell GAM, Quintana SM. Giant perineal leiomyoma incidentally manifested at a recente episiotomy site: case report. *J Minimally Invasive Gynecol*. 2011;18:267-9.
8. Campos FG, Leite AF, Araújo SEA, Atuí FC, Seid V, Habr-Gama A, et al. Anorectal leiomyomas: report of two cases with different anatomical patterns and literature review. *Rev Hosp Clin Fac Med S Paulo*. 2004;59:296-301.
9. Saunders RN, Pattenden C, Agarawal PK. Heavy rectal bleeding secondary to the passage of a rectal leiomyoma per anus. *Ann R Coll Surg Engl*. 2004;2004.
10. Kock KS. Leiomioma retal: relato de caso e revisão de literatura. *Ver bras Coloproct*. 2004;24:170-3.
11. Matsuhashi N, Takahashi T, Ichikawa K, Tanahashi T, Sasaki Y, Tanaka Y, et al. Transvaginal resection of a rectal leiomyoma: a case report. *Oncol Lett*. 2015;10:3785-8.
12. Gómez JA, Obrero AM, Cecília DM, Mendoza YR, Sánchez AA, de la Rúa JR, et al. Real anal leiomyoma: a case report. *J Gastrointest Canc*. 2011;42:54-6.