



## Original Article

# Mechanical technology effect in the treatment of anorectocele using transanal repair of rectocele and full rectal mucosectomy with one circular stapler procedure



Carlos Sardiñas<sup>a,\*</sup>, Dilia Díaz Arreaza<sup>b</sup>, Héctor Osorio<sup>c</sup>

<sup>a</sup> Hospital Universitario de Caracas, Unidad de Coloproctología, Laboratorio de Fisiología Anorrectal, Caracas, Venezuela

<sup>b</sup> Universidad Central de Venezuela, Instituto Anatomopatológico "Dr. José Antonio O'Daly", Caracas, Venezuela

<sup>c</sup> Instituto Venezolano de Investigaciones Científicas (IVIC), Caracas, Venezuela

### ARTICLE INFO

#### Article history:

Received 25 September 2016

Accepted 21 December 2016

Available online 2 February 2017

#### Keywords:

Treatment  
Anorectocele  
TRREMS  
Staplers  
Comparison

### ABSTRACT

**Objective:** Transanal repair of rectocele and full rectal mucosectomy with one circular stapler is a procedure designed for the treatment of Obstructive Defecation Syndrome by doctor Fco. Sergio Regadas in 2005. We compare the use of multiple instruments and their mechanical technology effect in the treatment of anorectocele.

**Patients and methods:** Female patients complaining about sensation of incomplete evacuation, ages between 40 and 55. The evaluation was made with the function of evacuation protocol: colonic transit time, colon radiology, ecodefecography, anorectal manometry and psychological test. The technique used was transanal repair of rectocele and full rectal mucosectomy with one circular stapler, using staplers CPH-34, CPH-34HV and EEA-3135-HEM, with measurement of the rectal wall resected: vertical length in centimetres, horizontal length in centimetres, weight in grams and volume in cubic centimetres; afterwards histological study of the tissue thickness, and applied the ANOVA and SPSS 12 tests for the statistical analysis.

**Results:** The results obtained by comparing the resections made with the CPH-34, the CPH-34HV and the EEA-3135-HEM in respect of vertical length, horizontal length, weight and volume, were found to have no significant differences; neither in the histological study of the tissue thickness in respect of characteristics and structure.

**Conclusion:** The effect of mechanical technology in the treatment of anorectocele with transanal repair of rectocele and full rectal mucosectomy with one circular stapler procedure using the CPH-34, the CPH-34HV and the EEA-3135-HEM, does not show any difference. Leaving the application of each to the operator competencies.

© 2017 Sociedade Brasileira de Coloproctologia. Published by Elsevier Editora Ltda. This is an open access article under the CC BY-NC-ND license (<http://creativecommons.org/licenses/by-nc-nd/4.0/>).

\* Corresponding author.

E-mail: [carlooseduardosardinas@gmail.com](mailto:carlooseduardosardinas@gmail.com) (C. Sardiñas).

<http://dx.doi.org/10.1016/j.jcol.2016.12.003>

2237-9363/© 2017 Sociedade Brasileira de Coloproctologia. Published by Elsevier Editora Ltda. This is an open access article under the CC BY-NC-ND license (<http://creativecommons.org/licenses/by-nc-nd/4.0/>).

## Efeito mecânico da tecnologia no tratamento da anorretocele com o uso do procedimento TRREMS

### R E S U M O

#### Palavras-chave:

Tratamento  
Anorretocele  
TRREMS  
Grampos  
Comparação

**Objetivo:** TRREMS (*Transanal Repair of Rectocele and full rectal Mucosectomy with one circular Stapler*, Reparo transanal de retocele e mucosectomia retal total com um grampo circular) é um procedimento que visa o tratamento da Síndrome da Defecação Obstrutiva pelo Dr. Francisco Sergio Regadas em 2005. Comparamos o uso de diversos instrumentos e o efeito mecânico da tecnologia no tratamento da anorretocele.

**Pacientes e métodos:** Pacientes do gênero feminino com queixa de sensação de evacuação incompleta (SEI), com idades entre 40 e 55 anos. A avaliação foi efetuada com o protocolo de função de evacuação: tempo de trânsito colônico, radiologia do cólon, ecodefecografia, manometria anorretal e teste psicológico. A técnica empregada foi TRREMS, com o uso de grampeadores CPH-34, CPH-34HV e EEA-3135-HEM, com medição da parede retal ressecada: comprimento vertical em centímetros, comprimento horizontal em centímetros, peso em gramas e volume em centímetros cúbicos; subsequentemente, foi realizado estudo histológico da espessura do tecido, com aplicação de ANOVA e do programa SPSS 12 para a análise estatística.

**Resultados:** Observamos que os resultados obtidos com a comparação das ressecções realizadas com CPH-34, CPH-34HV e EEA-3135-HEM com relação ao comprimento vertical, comprimento horizontal, peso e volume, bem como os resultados do estudo histológico da espessura do tecido com relação às características e estrutura, não apresentavam diferenças significativas.

© 2017 Sociedade Brasileira de Coloproctologia. Publicado por Elsevier Editora Ltda. Este é um artigo Open Access sob uma licença CC BY-NC-ND (<http://creativecommons.org/licenses/by-nc-nd/4.0/>).

## Introduction

Anatomical structures are a conjunction of relations, between each other, of an organ parts from human body. The distribution and order of organ parts provide the support structure that helps to transmit all the efforts and loads resulting of their existence and use.

Describing the anatomical structures that contribute in the regulatory mechanisms of continence and defecation can be done by explaining that the sigmoid colon has a propulsive function, the rectum acts as a container of faecal material and the anus is an organ with flow resistance and, at the same time, sensory and discriminative capacities.

The staggered arrangement of the three organs that play related functions is typical of our body. The arrangement of the terminal bowel elements ensures the continence, periodical and voluntary, also selective, with the ability to discriminate solid, liquid and gaseous contents. So, the anal continence depends on a barrier effect, which develops in the anorectal and anal junction. In the anus, this barrier effect is produced by the combination of forces that are due to the anatomical configuration of the pelvic floor and the muscle action; this complex mechanism is activated in response to sensory information obtained from this zone.

The pelvic floor and anal canal structures form an anatomic region traditionally poorly known. There are research papers, in the last years, in which new morphostructural approaches of the anal sphincter mechanism are dumped. In 2006 Regadas et al.,<sup>1</sup> showed discrepancies in the definition of the anal

canal, as well as new data in their extension and structural elements, what they call anorectocele and what provides modifications to the anatomic, the surgical and the functional canal, considering the idea of anorectocele being part of the morphostructural and functional alterations.

The difficulty of defining a concept is generally in proportion to the number of variables that can influence it. In the case of obstructive defecation syndrome (ODS), which could arise from the anorectocele, it is especially difficult because of the impossibility of all components involved in the absence of an effective defecation clumping. Therefore we believe that the factors involved in defecation could be divided into three types: structural factors, muscle factors and sensory factors.

On the basis of considering that the anorectocele is a morphostructural alteration that comprises the evacuation, the surgical correction would be the solution to the difficulties. There are a lot of papers that provide evidences, where the surgical correction of the rectovaginal septum alterations significantly improves the patients with obstructive defecation syndrome (ODS), but it takes multiple techniques and mechanical technologies to cut and staple the affected tissues, and there is the proposal of Leal and Regadas in 2010,<sup>2</sup> that to optimize the surgical technique staplers should be modified or using just one.

The purpose of this paper was to use the technique created by Regadas in 2004,<sup>3</sup> known as Transanal Repair of Rectocele and Rectal Mucosectomy with one Circular Stapler (TRREMS) to compare the effect of various mechanical technologies for cut and staple in the surgical treatment of anorectocele.

**Patients and methods**

In this experimental study were included 21 female patients with incomplete evacuation sensation, ages between 40 and 55. The patients were evaluated with the Evacuation Function Protocol used in the Coloproctology Unit of I. A. Hospital Universitario de Caracas,<sup>4</sup> in which studies were practiced to patients as: colonic transit time, colon radiology, ecodefecography, anorectal manometry and psychological test.<sup>5</sup> This allowed to determine the presence of an obstructive defecation syndrome (ODS) related to the presence of anorectocele. The experimenter introduced as control three female groups with ODS and anorectocele, the assignment was random. The technique used for their treatment was TRREMS,<sup>3</sup> in which the surgeon coloproctologist applied alternating staplers, CPH-34, CPH-34HV (Frankenman International Ltd.) and EEA-3135-HEM (Covidean USA). The hypothesis is that staplers have different capacities of resection as they are applied for the anorectocele treatment in TRREMS. The effect of mechanical technology is evaluated with subsequent measurement of the rectal wall resection. The samples where fixed with formalin 10% and placed on a cork to prevent deformation. During the macroscopic study were obtained the horizontal length in centimetres, the vertical length in centimetres, the weight in grams and the volume in cubic centimetres, making cuts of the wall. They were processed with routine techniques to obtain the histological slides stained with hematoxylin-eosin. They were analyzed with an Olympus CX31 microscope to determine the thickness in millimetres of each rectal wall layer. After two months exploring the patients reports we verify their clinical improvement and degree of satisfaction. Was employed for the statistical analysis the ANOVA and SPSS 21.

**Table 1 – Horizontal length descriptive statistics.**

Groups	N	Minimum	Maximum	Average	D.T.
CPH34	7	8	9.7	9.243	0.588
CPH 34HV	7	6	11.5	8.786	1.729
EEA HEM 3335	7	8	10	8.714	0.756

**Table 2 – Vertical length descriptive statistics (cm).**

Groups	Total	Minimum	Maximum	Average	D.T.
CPH34	7	3.5	4.7	4.04	0.4
CPH 34HV	7	3	4.5	3.79	0.4
EEA HEM 3335	7	2.5	4.7	3.56	0.8

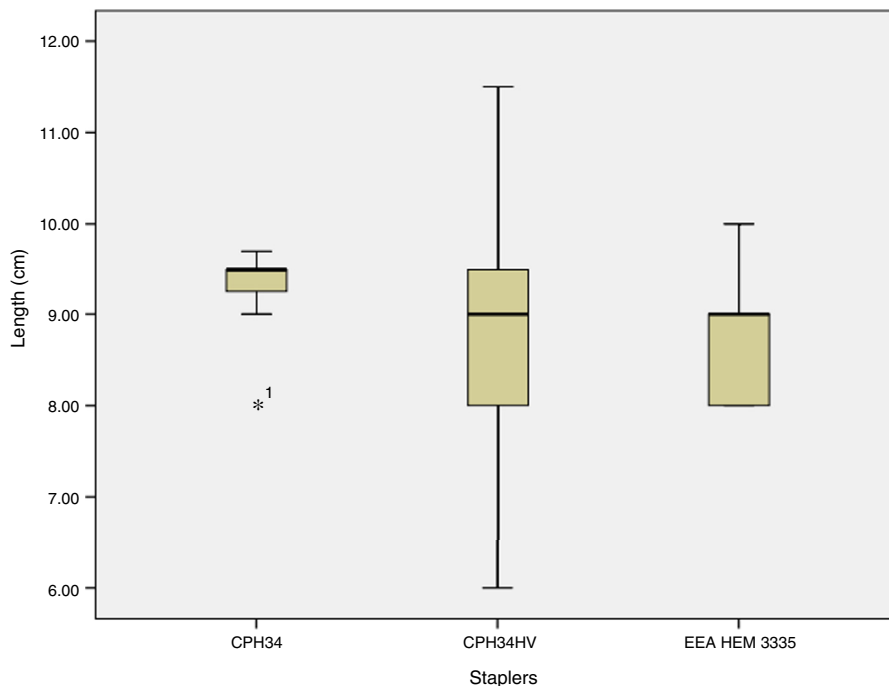
**Results**

**Horizontal length (cm)**

By comparing the staplers CPH-34, CPH-34HV (Frankenman International Ltd.) and EEA-3135-HEM (Covidean USA) with the resected tissue horizontal length in centimetres, the results did not show statistically significant differences ( $F_{2,18} = 0.442$ ;  $p > 0.05$ ) (Table 1 and Fig. 1).

**Vertical length or height (cm)**

By comparing the staplers CPH-34, CPH-34HV (Frankenman International Ltd.) and EEA-3135-HEM (Covidean USA) with the resected tissue vertical length or height in centimetres, the results did not show statistically significant differences ( $F_{2,18} = 1.408$ ;  $p > 0.05$ ) (Table 2 and Fig. 2).



**Fig. 1 – Horizontal length descriptive statistics (cm).**

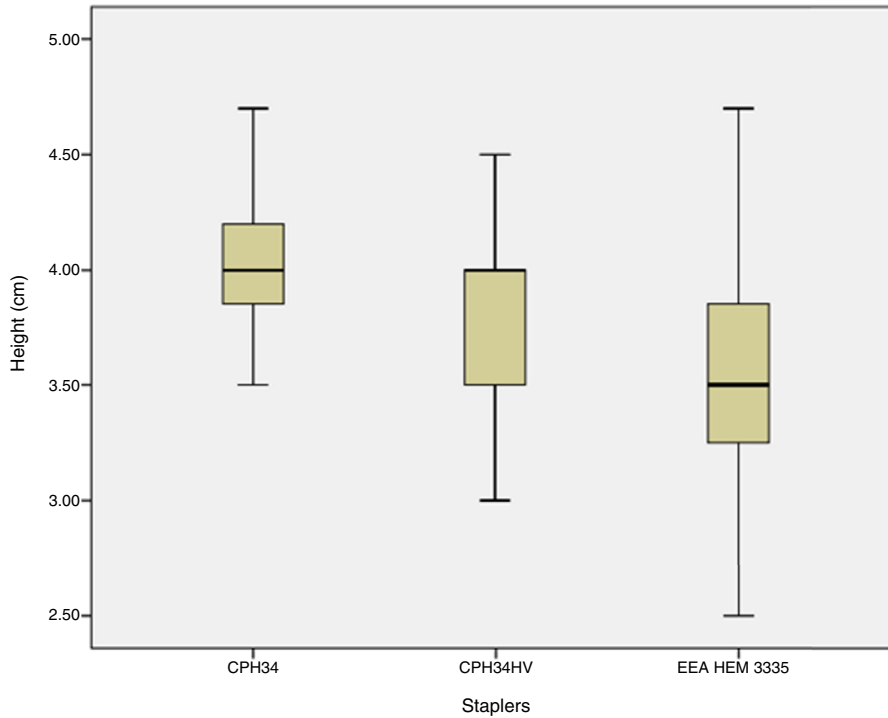


Fig. 2 – Horizontal length or height descriptive statistics.

Table 3 – Weight descriptive statistics (g).

Groups	Total	Minimum	Maximum	Average	D.T.
CPH34	7	6	13	9.57	2.3
CPH 34HV	7	7	11	9.43	1.5
EEA HEM 3335	7	7	11	7.96	1.5

Weight (g)

By comparing the staplers CPH-34, CPH-34HV (Frankenman International Ltd.) and EEA-3135-HEM (Covidean USA) with the resected tissue weight in grams, the results did not show statistically significant differences ( $F_{2,18} = 2.046$ ;  $p > 0.05$ ) (Table 3 and Fig. 3).

Volume (cc)

By comparing the staplers CPH-34, CPH-34HV (Frankenman International Ltd.) and EEA-3135-HEM (Covidean USA) with the resected tissue volume in cubic centimetres, the results did not show statistically significant differences ( $F_{2,18} = 3.327$ ;  $p > 0.05$ ) (Table 4 and Fig. 4).

Table 4 – Volume descriptive statistics (cc).

Groups	Total	Minimum	Maximum	Average	D.T.
CPH34	7	6	13	9.57	2.34
CPH 34HV	7	7	11	9.43	1.51
EEA HEM 3335	7	6	10	7.57	1.37

Table 5 – Thickness descriptive statistics (mm).

Groups	Total	Minimum	Maximum	Average	D.T.
CPH34	7	7.2	13.6	9.67	2.2
CPH 34HV	7	7.8	9	8.26	0.5
EEA HEM 3335	7	7.8	10.9	8.76	1.1

Thickness (mm)

By comparing the staplers CPH-34, CPH-34HV (Frankenman International Ltd.) and EEA-3135-HEM (Covidean USA) with the resected tissue thickness in millimetres, the results did not show statistically significant differences ( $F_{2,18} = 2.031$ ;  $p > 0.05$ ) (Table 5 and Fig. 5).

Exploration of patients report

The improvement levels two months after the treatment were marked in eleven patients and complete in seven patients.

The satisfaction degree two months after the treatment was somewhat satisfied in four patients and very satisfied in seventeen patients.

Discussion

Boccasanta established in 2004,<sup>6</sup> that it has been introduced, since 1998, the circular staplers for transanal haemorrhoids or mucosal prolapses treatment, opening a new horizon for the obstructive evacuation treatment. Boccasanta proposes to replace existing surgical treatment as correction of rectocele

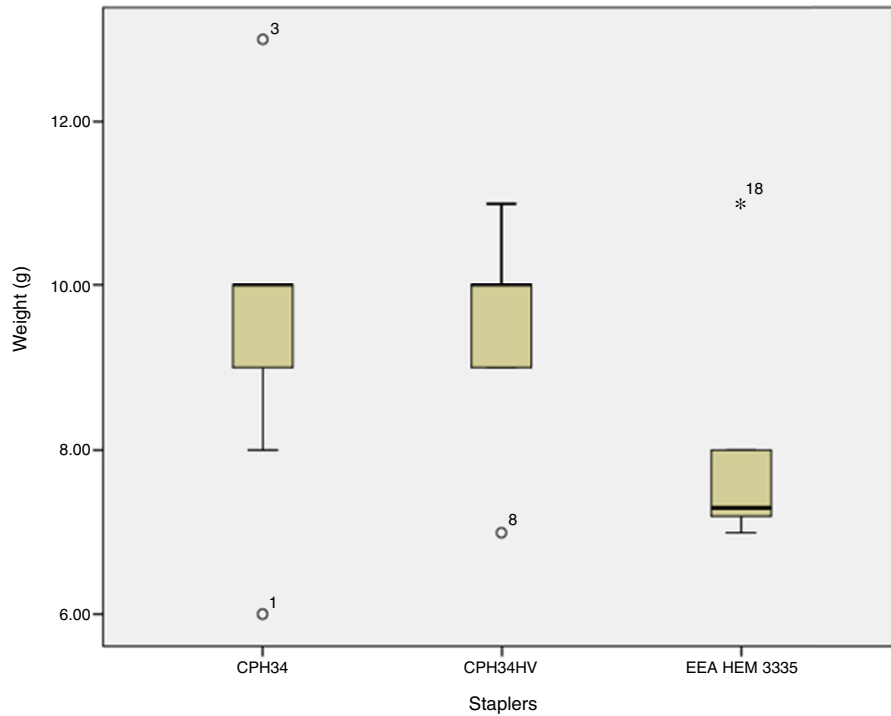


Fig. 3 – Weight descriptive statistics (g).

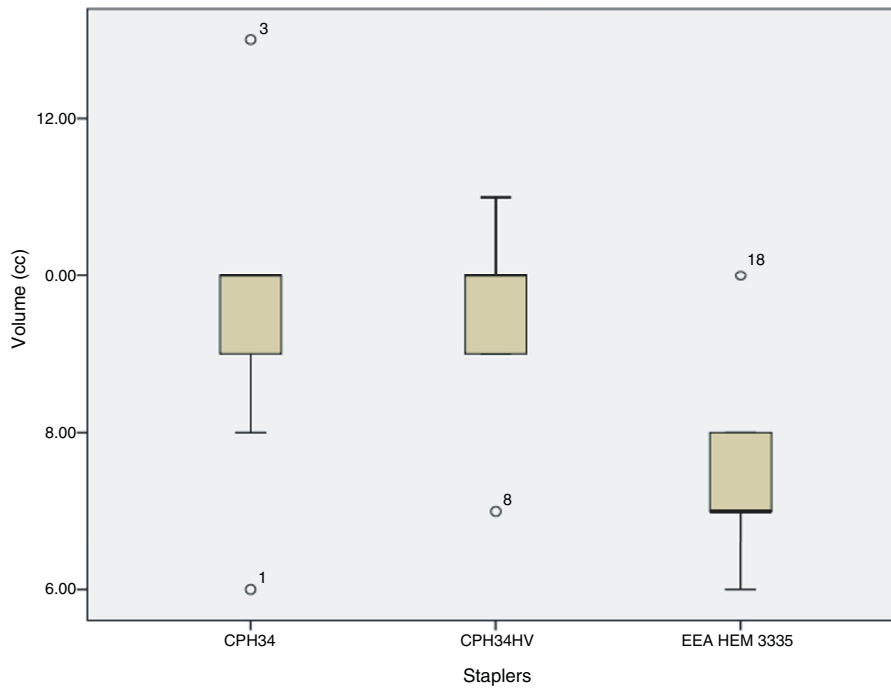
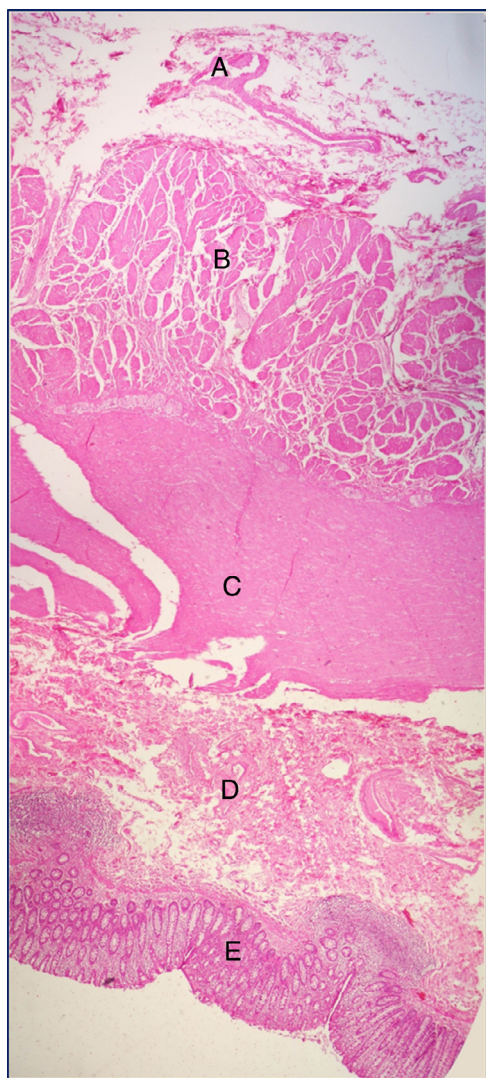


Fig. 4 – Volume descriptive statistics (cc).

with vaginal or perineal levartoplasty, Delorme’s transrectal excision, laparotomy o laparoscopy with resections or re-topexy by two procedures with transanal stapled (STAPL) and perineal levartoplasty with double transanal stapled for rectal resection (STARR), they could be effective alternatives to conventional surgeries in the obstructive evacuation treatment.

In both, STAPL and STARR, was employed the PPH-01 (Ethicon endosurgery USA), making reference to the mechanical technology effect, obtaining that histological examination of resected tissues found rectal smooth muscle fibres in 64% of the groups, without any other findings, causing doubts in 26% of them.



**Fig. 5 - Thickness descriptive statistics (mm).**

Boccasanta published in august 2004<sup>7</sup> a second paper with STARR in the obstructive evacuation treatment. Using the PPH-01 (Ethicon endosurgery USA), in this opportunity offering data about the mechanical technology effect of stapled, determining an anterior segment of tissue with an horizontal length of  $6.2 \pm 1.6$  cm and a width of  $5.7 \pm 1.2$  cm. For the posterior segment a horizontal length of  $4.8 \pm 1.4$  cm and a width of  $4.8 \pm 1.4$  cm. He reports the finding of smooth muscle fibres in 100% of the patients. Thus the first values of the technology effects in tissues are set. We obtained values for horizontal length from 6 to 11.5 cm as shown in Table 1 and Fig. 1, vertical length or height from 2.5 to 4.7 cm as shown in Table 2 and Fig. 2. However there is no significant evidence comparing the staplers CPH-34, CPH-34HV (Frankenman International Ltd.) and EEA-3135-HEM (Covidean USA).

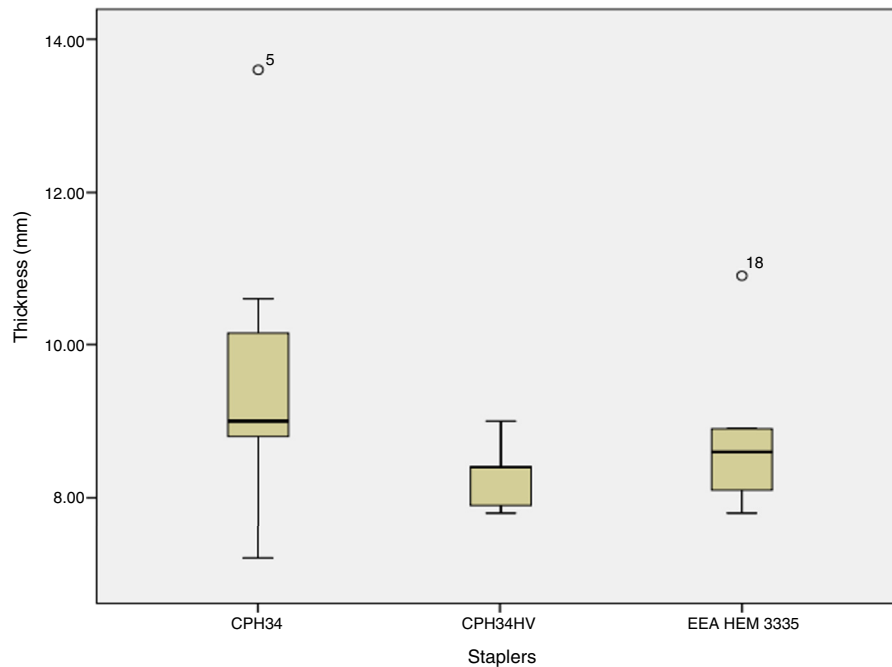
In November 2004, Regadas<sup>3</sup> published a new technique for the rectocele treatment, using a transanal stapler, labelling it "transanal repair of rectocele and full rectal mucosectomy with one circular stapler" (TRREMS), being considered by the author as a new technique in the existing spectrum of the already known. For the TRREMS execution in eight patients

they used two types of staplers, the EEA-34-stapler (Tyco healthcare USA) in seven patients and the PPH-03 33 mm (Ethicon endosurgery USA) in one. The mechanical technology effect results are published, reporting one mucosal band with a thickness of 5.2 cm, average from 4.5 to 6.5 cm, nevertheless they do not discriminate between staplers in the results. The histologic evaluation reports finding rectal smooth muscle fibres in every patient. In the results discussion Regadas emphasizes the need for stapled suture being located between the normal anterior wall of the rectus and the anal canal, 0.5 cm above the pectineal line. This way the anorectovaginal septum will be resected and reinforced, and will be promoted the scarring of healthy tissue. Kleeman in 2005<sup>8</sup> published a review and upgrade of rectoceles and anatomy of the vaginal posterior wall, where they could get the structure of the multiple layers and established that the thickness in anorectoceles could reach 16.6 mm. In Fig. 6 could be appreciate the width reached by the staplers CPH-34, CPH-34HV (Frankenman International Ltd.) and EEA-3135-HEM (Covidean USA), from de rectal mucosa until the adventicia, the thickness values range from 7.2 to 13.6 mm, without significant differences comparing the staplers as shown in Table 5 and Fig. 5.

In 2005, Regadas<sup>9</sup> published a multicentre experience, where it is presented the evaluation of the use of new rectal mucosectomy equipment with stapled. In this occasion the stapler used is the circular EEA-34-mm (Tyco healthcare USA). The mechanical technology effects where the cleavage of a 4.7 cm mucosal band without any histological study of the samples. In this paper they comment the existence of two different types of staplers, as the PPH-01 and the PPH-03 (Ethicon endosurgery USA) and the circular EEA-34-mm (Tyco healthcare USA), they have been used for the mucosal band resections; linking the mucosal prolapse, not to the technical principles of the surgical procedure, but the staplers being use until then. Regadas considers that the ideal resection, because of the size and shape provided by staplers, should be a 5 cm wide mucosal band, but the mechanical technology capacity just allows an average of 4.5 cm wide, supporting his claim in the Latin-American multicentre work in 2003, headed by Habr-Gama<sup>10</sup> where they published the first experiences of the stapled haemorrhoidectomy. The mucosal bands, as termed by Regadas, did not exceed 4.7 cm as shown in Table 2 and Fig. 2. Regardless of the stapler used for the technique.

In 2008, Lehur<sup>11</sup> published a multicentre paper where they apply STARR for the obstructive evacuation treatment, using PPH-01 (Ethicon endosurgery USA), reporting the doughnuts resection, understood as circumferential tissue, these where subjected to histological studies. They do not report dimensions or histological characteristics of the doughnuts, so that there is no evidence of the mechanical technology effect, reported by other authors with the use of the PPH-01 (Ethicon endosurgery USA), which could mean that the resection proportions would not be relevant in the technologic effect of stapled. It seems to be demonstrated by results not showing any statistically significant differences in tables and figures.

Renzi,<sup>12</sup> in 2008, published a multicentre study where was used a new stapler for the STARR in the obstructive evacuation treatment. This stapler is the CCS-30 contour transtar (Ethicon endosurgery USA), reporting the mechanical technology effect in the obtainment of a mucosal band of  $7.8 \pm 2.8$  cm



**Fig. 6 – Anorectoceles horizontal section. Hematoxylin eosin stained. Resected tissue shows rectal wall components. Adventitia (A), outer muscle layer (B), inner muscle layer (C), submucosa (D) and rectal mucosa (E).**

and  $10.1 \pm 2.2$  cm long, there being no report of the tissue histologic analysis. One important element of the paper is the comment where is compared the CCS-30 contour transtar (Ethicon endosurgery USA) with the PPH-01 (Ethicon endosurgery USA). It is affirmed that the major capacity of the CCS-30 contour transtar (Ethicon endosurgery USA) is the resection of a greater tissue volume. This parameter, the volume, is referred for the first time in the literature reviewed, so is added a new dimension to the mechanical technology effect, that has been described in the resected samples as width and length of the mucosa, and at this moment was considered of 5 cm. However, Renzi does not report values of the mechanical technology effect with the exception that this is greater than the previous obtained with other technologies. Table 4 and Fig. 4 allow to demonstrate volumes varying between 6 and  $13 \text{ cm}^3$ , but again no significant differences between staplers CPH-34, CPH-34HV (Frankenman International Ltd.) and EEA-3135-HEM (Covidean USA).

Lenisa<sup>13</sup> in 2008, published a multicentre prospective paper of the results applying STARR technique with the stapler CCS-30 contour transtar (Ethicon endosurgery USA) for the obstructive evacuation treatment. It establishes the limitations that the PPH-01 (Ethicon endosurgery USA) has for the rectal wall resection, as well as being a blind procedure after the insertion of the transanal stapler. One of the new elements that Lenisa introduces in the study is the resected tissue weight value, as a measure of the mechanical technology effect, besides of the height and the histologic evaluation, already established by other authors, trying to show the thickness of the rectal wall that has been resected, as well as the presence or absence of peritoneum. The results obtained in the evaluation of the specimens were an average width of 8.1 cm and a length of 4.8 cm, an average weight of 30 g. It was

also established the total resection of the rectal wall reaching to the perirectal adipose tissue in all the cases. Lenisa concludes that STARR using the new instrument is much more effective, as the elimination of the whole rectal wall thickness is obtained, it duplicates the average of the tissue resected size and weight comparing it with the weight average accomplished with a PPH-01 (Ethicon endosurgery USA) that had been 15 g. The tissue weight in the resections was between 6 and 13 g, but again no significant differences between staplers CPH-34, CPH-34HV (Frankenman International Ltd.) and EEA-3135-HEM (Covidean USA) as shown in Table 3 and Fig. 3.

Reboa<sup>14</sup> in 2009 publishes an analysis of the STARR results in the treatment of obstructive evacuation, considered as a modern alternative in the transanal treatment techniques. Reboa employs the PPH-01 (Ethicon endosurgery USA), presenting as elements for technique evaluation the mechanical technology effects in the resected mucosal specimens, being necessary to remember that in STARR technique are obtained two segments, anterior and posterior. The average values that were reached were vertical of  $4.3 \pm 1.1$  cm for the anterior segment and  $3.6 \pm 1.2$  cm for the posterior segment, horizontal of  $5.8 \pm 1.4$  cm for the anterior segment and  $4.5 \pm 1.3$  cm for the posterior segment. Reboa does not consider the parameters of weight or volume, neither the histologic evaluation of the thickness. From the analysis of the multiple authors until now, the most important variables are the horizontal and vertical lengths, this is not being shown in our tables and figures, as there are no results with statistically significant differences.

In 2009, Isbert<sup>15</sup> presents a comparative study between STARR and TRANSTAR for the obstructive evacuation treatment. In their study is expressed that surgical techniques promoted in that moment looked for the distal rectus resection and the anatomic abnormalities that could be

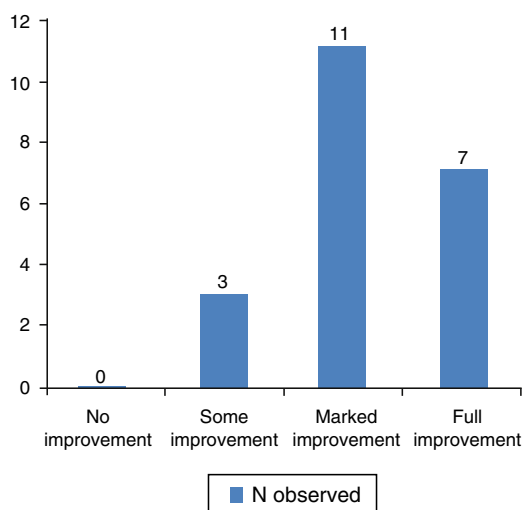


Fig. 7 – Improvement levels.

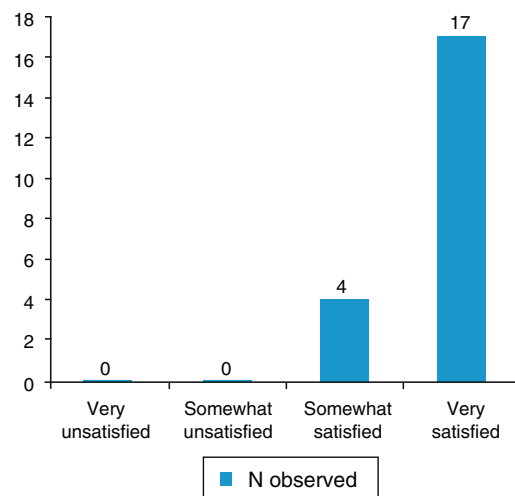


Fig. 8 – Degree of satisfaction.

associated, even when it have not been proved, an extensive suppression of the rectus could improve the evacuation function. Isbert compares the PPH-01 (Ethicon endosurgery USA) with the CCS-30 contour transtar (Ethicon endosurgery USA) allowing us to rescue the mechanical technology effects values of both machines, with the resected tissue volume, being  $46 \pm 10.68 \text{ cm}^3$  for the CCS-30 contour transtar (Ethicon endosurgery USA) and  $27 \pm 4.86 \text{ cm}^3$  for the PPH-01 (Ethicon endosurgery USA). Regarding the width of the tissue bands resected it showed an average of 4.5 cm and 3.5 cm respectively. Isbert sustains that the CCS-30 contour transtar (Ethicon endosurgery USA) has a greater capacity than the PPH-01 (Ethicon endosurgery USA), as the last one shows limitations for the resection of rectal tissue due to the restrictions in accommodating to the tissue appropriate volume in the stapled cylinder. However it establishes that besides the acceptance that obtaining the complete tissue prolapsed would improve the function, it is not demonstrated by the study when the results of both staplers are compared after 12 months of following. Isbert considerations are very interesting, in our study we reached important levels of improvement and satisfaction, shown in Figs. 7 and 8, but this was obtained in a greater following time than Isbert's.

Wadhawan<sup>16</sup> in 2010 shows an study where is tried to established if the CCS-30 contour transtar (Ethicon endosurgery USA) increases the results because of its better mechanical technology effect, compared to the PPH-01 (Ethicon endosurgery USA), since this last one presents limitations in the tissue resections as said by Isbert. The capacities of both staplers were reached with the measure of the extended tissue on a table and fixed with tweezers, without stretching it, the measure of the specimen was made in the central portion with values of 4.2 cm for the PPH-01 (Ethicon endosurgery USA), and 5.3 cm for the CCS-30 contour transtar (Ethicon endosurgery USA), the circumference measures were taken as equal. On the other hand it establishes that even if there is no significant difference in the rectal wall resection capacity it cannot be established the improvement. One critique to the method for obtaining the measures of the

mechanical process is the tissues elasticity, being recommended, as a more suitable variable, the tissue weight, as previously proposed by Lenisa in 2008, even though the accuracy could be compromised. That is why it is recommended to individualize the technique for each patient. The data obtained has demonstrated that there is no significant difference in the mechanical technology effects where it is valued the mucosal resection measures: horizontal and vertical lengths in centimetres, weight in grams and volume in cubic centimetres, accompanied by the histologic study of the tissue thickness in millimetres of all the staplers in all the groups, also during a period of time the patients were followed for reporting improvement and satisfaction.<sup>17</sup> It is mandatory the individualization of each patient, coinciding with Wadhawan, applying something similar to the Evacuation Function Protocol and recording the colonic transit time, radiology of the colon, ecodecography, anorectal manometry and psychological test.<sup>4</sup>

Leal,<sup>2</sup> in 2010 presented the results of evaluating the TRREMS technique for the obstructive evacuation treatment, developed by Regadas<sup>3</sup> in Brazil in 2005 for the treatment of rectocele and mucosal prolapse with one circular stapler. Leal<sup>2</sup> with the collaboration of Regadas uses the stapler 34-mm EEA circular stapler (Covidean USA) for TRREMS obtaining the resection of the anorectal junction anterior wall, mucosa and submucosa in the whole circumference, this mechanical technique effect is demonstrated by the reduction of the rectocele size, with average values, obtained by ecodefecography, resting between 19.2 mm and 6.6 mm and with effort between 34.8 mm and 10.9 mm, after treatment. There are no other parameters in the paper of effort measure, but there is the proposal that for optimizing the surgical technique it should be modified the staplers or use a single one. They have presented the results of the analysis of three staplers designed with the purpose of making transanal resections with diverse therapeutic indications, in this case, anorectocele with TRREMS technique. The staplers were CPH-34, CPH-34HV (Frankenman International Ltd.) and EEA-3135-HEM (Covidean USA) an alleged evolution of design of the PPH-01 (Ethicon endosurgery USA) but it was not possible to demonstrate it, as the analysis



is statistically not significant on the previous values published by the reviewed literature.

Cruz<sup>18</sup> in 2011, published a multicentre investigation where is evaluated the TRREMS technique. In this opportunity they use two staplers, the 34-mm EEA and the 31-EEA circumferential stapler (Covidian USA) in order to remove circumferentially the anorectal mucosa and to strengthen the anorectal anterior wall junction, but with one of the staplers. There is no assessment of the stapler's effects except the mention about the 10.6% of patients having a residual anorectocoele grade I. It is mentioned that TRREMS technique made with one stapler produced a rectocele suppression followed by a complete mucosectomy and anopexy, where additionally it rectifies the rectovaginal wall and it strengthen the fibrous tissue produced in the healing process.

All this leads us to conclude that in the presence of obstructive defecation syndrome (ODS), the selection criteria for patients are essential,<sup>4</sup> so that, with a technique<sup>3</sup> and a stapler applied by a coloproctologist<sup>19</sup> important improvement levels and satisfaction degrees will be obtained.<sup>4,17</sup>

### Conflicts of interest

The authors declare no conflicts of interest.

### REFERENCES

- Regadas FS, Murad-Regadas SM, Wexner SD, Rodrigues LV, Souza MH, Silva FR, et al. Anorectal three-dimensional endosonography and anal manometry in assessing anterior rectocele in women: a new pathogenesis concept and the basic surgical principle. *Colorectal Dis.* 2007;9:80-5.
- Leal VM, Regadas FSP, Murad Regadas SM, Veras LR. Clinical and functional evaluation of patients with rectocele and mucosal prolapse treated with transanal repair of rectocele and rectal mucosectomy with a single circular stapler (TRREMS). *Tech Coloproctol.* 2010;14:329-35.
- Regadas FS, Regadas SM, Rodrigues LV, Misici R, Silva FR, Regadas Filho FS. Transanal repair of rectocele and full rectal mucosectomy with one circular stapler: a novel surgical technique. *Tech Coloproctol.* 2005;9:63-6.
- Vargas E, Pérez L, Melo I, Bravo P, Sardiñas C. Cura de rectocele por vía transanal. Experiencia de la Unidad de Coloproctología del Hospital Universitario de Caracas. *Rev Venez Cir.* 2009;62:103-6.
- Pescatori M, Spyrou M, Pulvirenti d'Urso A. A prospective evaluation of occult disorders in obstructed defecation using the "iceberg diagram". *Colorectal Dis.* 2007;9:452-6.
- Boccasanta P, Venturi M, Salamina G, Cesana BM, Bernasconi F, Roviario G. New trends in surgical treatment of outlet obstruction: clinical and functional results of two novel transanal stapled techniques from a randomized controlled trial. *Int J Colorectal Dis.* 2004;19:359-69.
- Boccasanta P, Venturi M, Stuto A, Bottini C, Caviglia A, Carriero A, et al. Stapled transanal rectal resection for outlet obstruction: a prospective, multicenter trial. *Dis Colon Rectum.* 2004;47:1285-96.
- Kleeman SD, Westermann C, Karram MM. Rectoceles and anatomy of posterior vaginal wall: revisited. *Am J Obstet Gynecol.* 2005;193:2050-5.
- Regadas FS, Regadas SM, Rodrigues LV, Misici R, Tramuja I, Barreto JB, et al. New devices for stapled rectal mucosectomy: a multicenter experience. *Tech Coloproctol.* 2005;9:243-6.
- Habr-Gama A, e Sous AH Jr, Roveló JM, Souza JV, Benício F, Regadas FS, et al. Stapled hemorrhoidectomy: initial experience of a Latin American group. *J Gastrointest Surg.* 2003;7:809-13.
- Lehur PA, Stuto A, Fantoli M, Villani RD, Queraltó M, Lazorthes F, et al. Outcomes of stapled transanal rectal resection vs. biofeedback for the treatment of outlet obstruction associated with rectal intussusception and rectocele: a multicenter, randomized controlled trial. *Dis Colon Rectum.* 2008;51:1611-8.
- Renzi A, Talento P, Giardiello C, Angelone G, Izzo D, Di Sarno G. Stapled transanal rectal resection (STARR) by a new dedicated device for the surgical treatment of obstructed defecation syndrome caused by rectal intussusception and rectocele: early results of multicenter prospective study. *Int J Colorectal Dis.* 2008;23:999-1005.
- Lenisa L, Schwandner O, Stuto A, Jayne D, Pigot F, Tuech JJ, et al. STARR with Contour® Transtar™: prospective multicenter European study. *Colorectal Dis.* 2009;11:821-7.
- Reboa G, Gipponi M, Ligorio M, Marino P, Lantieri F. The impact of stapled transanal rectal resection on anorectal function in patients with obstructed defecation syndrome. *Dis Colon Rectum.* 2009;52:1598-604.
- Isbert C, Reibetanz J, Jayne DG, Kim M, Germer CT, Boenicke L. Comparative study of Contour Trastar an STARR procedure for the treatment of obstructed defaecation syndrome (ODS) feasibility, morbidity and early functional results. *Colorectal Dis.* 2010;12:901-8.
- Wadhawan H, Shorthouse AJ, Brown SR. Surgery for obstructed defaecation: does the use of the Contour device (Trans-STARR) improve results? *Colorectal Dis.* 2009;12:885-90.
- Murthy VK, Orkin BA, Smith LE, Glassman LM. Excellent outcome using selective criteria for rectocele repair. *Dis Colon Rectum.* 1996;39:374-8.
- Cruz JV, Regadas FSP, Murad-Regadas SM, Rodrigues LV, Benicio F, Leal R, et al. TRREMS procedure (Transanal Repair of Rectocele and rectal Mucosectomy with one circular Stapler). A prospective multicenter trial. *Arq Gastroenterol.* 2011;48:3-7.
- De Miguel M, Ortiz H, Yáñez MC, Marzo J, Armendáriz P, Artieda C. El cirujano colorrectal como factor pronóstico de resultados. *ANALES Sis San Navarra.* 2001;24:87-91.