



## Original Article

# Sphincteroplasty and perineoplasty with skin advancement flap in management of traumatic cloacal defect



Fakhrolsadat Anaraki<sup>a</sup>, Omid Etemad<sup>b,\*</sup>

<sup>a</sup> Shahid Beheshti University of Medical Sciences, Colorectal Division of Surgery Ward, Taleghani Hospital, Tehran, Iran

<sup>b</sup> Shahid Beheshti University of Medical Sciences, Surgery Ward, Taleghani Hospital, Tehran, Iran

### ARTICLE INFO

#### Article history:

Received 6 August 2016

Accepted 31 August 2016

Available online 28 September 2016

#### Keywords:

Traumatic cloaca defect

Sphincteroplasty

Perineal reconstruction

Skin advancement flap

### ABSTRACT

**Background:** Traumatic cloacal defect (TCD) is the condition that occurs in 0.3% of women who have experienced the third/fourth-degree perineal laceration during traumatic Natural Vaginal Delivery (NVD). This condition has many undesirable effects in their lives. Surgery is the best way to repair this deformity and will improve the quality of life in these patients.

**Design:** In this study, we prospectively studied 19 patients who were referred to the hospital with symptoms of TCD within years 2011 and 2015 with the mean of 2.6-yrs follow-up. They all underwent sphincteroplasty and perineoplasty with skin advancement flap.

**Results:** Of all 19 patients, incontinence to solid faeces in 16 patients (84%), incontinence to liquid stool in 15 patients (78%) and incontinence to flatus in 4 patients (21%) were completely resolved. The FI score was decreased from the mean of 12.7 to 2.6. Sexual function was significantly improved in all of them and dyspareunia was completely disappeared in 9 patients (50%). The quality of life score was increased from the mean of 45 to 95. Post-operation complications were occurred in 3 of patients (wound infection in 2-cases and recto-vaginal fistula in another).

**Conclusion:** Our findings show that sphincteroplasty and perineoplasty with skin advancement flap is an effective surgical technique to repair the perineal body due to its benefits and few complications. In this study, there was significant improvement in quality of life of almost all patients after this reconstructive surgery. Consulting with a colorectal surgeon is recommended for these cases.

© 2016 Sociedade Brasileira de Coloproctologia. Published by Elsevier Editora Ltda. This is an open access article under the CC BY-NC-ND license (<http://creativecommons.org/licenses/by-nc-nd/4.0/>).

\* Corresponding author.

E-mail: [rasaeti@yahoo.com](mailto:rasaeti@yahoo.com) (O. Etemad).

<http://dx.doi.org/10.1016/j.jcol.2016.08.002>

2237-9363/© 2016 Sociedade Brasileira de Coloproctologia. Published by Elsevier Editora Ltda. This is an open access article under the CC BY-NC-ND license (<http://creativecommons.org/licenses/by-nc-nd/4.0/>).

## Esfincteroplastia e perineoplastia com retalho cutâneo de avanço no tratamento de defeito cloacal traumático

### R E S U M O

#### Palavras-chave:

Defeito cloacal traumático  
Esfincteroplastia  
Reconstrução perineal  
Retalho cutâneo de avanço

**Experiência:** Defeito cloacal traumático (RCT) é a condição que ocorre em 0,3% das mulheres que sofreram laceração perineal de terceiro/quarto grau durante um parto vaginal natural (PNV) traumático. Essa condição causa muitos efeitos indesejáveis em suas vidas. A cirurgia é a melhor forma de reparar essa deformidade, e melhorará a qualidade de vida nessas pacientes.

**Modelo:** Nesse estudo, estudamos prospectivamente 19 pacientes que foram encaminhadas ao hospital com sintomas de RCT entre 2011 e 2015, com uma média de 2,6 anos de seguimento. Todas foram submetidas a uma esfincteroplastia e perineoplastia, com retalho cutâneo de avanço.

**Resultados:** Da totalidade de 19 pacientes, a incontinência para fezes sólidas em 16 pacientes (84%), a incontinência para fezes líquidas em 15 pacientes (78%) e a incontinência para flatos em quatro pacientes (21%) foram completamente resolvidas. Ocorreu redução no escore FI, de uma média de 12,7 para 2,6. A função sexual melhorou significativamente em todas as pacientes, e a dispareunia desapareceu completamente em nove pacientes (50%). O escore para qualidade de vida melhorou, da média de 45 para 95. Ocorreram complicações pós-operatórias em três pacientes (infecção da ferida em dois casos e fistula retovaginal no caso restante).

**Conclusão:** Nossos achados demonstram que a esfincteroplastia e a perineoplastia com retalho cutâneo de avanço é técnica cirúrgica efetiva para o reparo do corpo perineal, graças a seus benefícios e às poucas complicações. Nesse estudo, foi observada melhora siga na qualidade de vida de praticamente todas as pacientes em seguida a essa cirurgia reconstrutiva. Para tais casos, é recomendável uma consulta com um cirurgião colorretal.

© 2016 Sociedade Brasileira de Coloproctologia. Publicado por Elsevier Editora Ltda. Este é um artigo Open Access sob uma licença CC BY-NC-ND (<http://creativecommons.org/licenses/by-nc-nd/4.0/>).

## Background

Cloacal deformity is the condition that occurs in 0.3% of the patients with the third or fourth-degree laceration during (NVD).<sup>1-4</sup> This injury is characterized by disruption of the perineal body and distal portion of recto-vaginal septum.<sup>1</sup>

Patients with cloacal deformity invariably suffer from severe incontinence to flatus, liquid and solid stool and severe urinary and vaginal infections.<sup>5</sup> Difficulties during sexual function such as dyspareunia in these patients are also annoying.<sup>1-5</sup> These problems may lead to psychological and physical disorders such as social isolation and sexual dysfunction which could decrease the quality of life.<sup>1-5</sup> For patients with history of TCD and successful surgical repair, Caesarean section seems reasonable for the next delivery.<sup>5</sup>

To diagnose this deformity we should have a careful obstetric history and detailed physical examination of perineal area.<sup>1</sup> Diminution or absence of perineal body and the anovaginal/rectovaginal septum in women with history of traumatic NVD are the evidences of cloacal deformity.

There are also additional diagnostic tests including endoanal ultrasound, manometry and pudendal nerve stimulation.<sup>6</sup>

Several surgical techniques are available to treat TCD and reconstruct perineal body. In this study, we will study the conditions of 19 patients who were underwent sphincteroplasty

and perineoplasty with skin advancement flap to repair the perineal body between 2011 and 2015 at the follow-up plan between 3-months and 4-yrs with the mean of 2.6-yrs.

## Objective

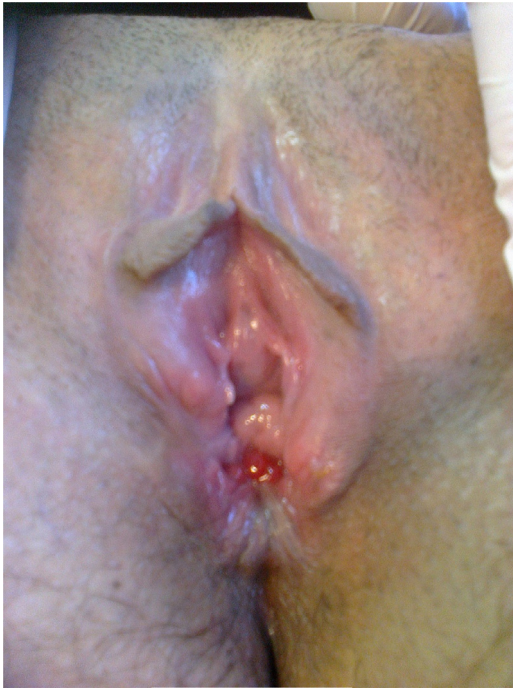The sphincteroplasty and perineoplasty with skin advancement flap were performed for all patients. All data are gathered for mean 2.6-yrs of follow-up. The data related to incontinence score and quality of life were collected by using Wextner Faecal Incontinence Score (FI Score) and Quality of Life (QoL) form which are available in Appendix 1 and 2, respectively.

Other data including pre- and post-operation dyspareunia, sexual function satisfaction, satisfaction of the results of surgery, and also post-operation complications were collected through interviews with each patient.

Fig. 1 shows TCD in one of the patients.

## Design

All patients were given full bowel preparation the day before surgery and antibiotic was administered preoperatively. Under general anaesthesia and lithotomy position, urinary catheter was placed (Fig. 2A). The next steps are as follows:



**Fig. 1 – Traumatic cloaca defect in one of the patients.**

- Identifying the skin flap with approximate length of 8–10 cm (Fig. 2B).
- Separation of ano-rectum from the vagina by dissecting the recto-vaginal septum (Fig. 3A).
- Performance of sphincteroplasty in order to overlapping the internal and external sphincter (Fig. 3B).
- Reconstruction of perineal body by approximating the bulbocavernosus, external sphincter and transverse perineal muscles.
- Reconstruction of perineal skin with advancement flaps (Fig. 4).

Overlapping sphincteroplasty was performed by using 2/0 vicryl separated sutures. Perineal body was reconstructed by approximating bulbocavernosus, transverse perineal and external sphincter muscles. Finally skin reconstruction was done with advancement flap and hemovac drain was placed under the flap. The patient left NPO for three days and loperamide was administered for them and the wound was dressed daily. The drain was removed after 3–4 days.

### Outcome measures

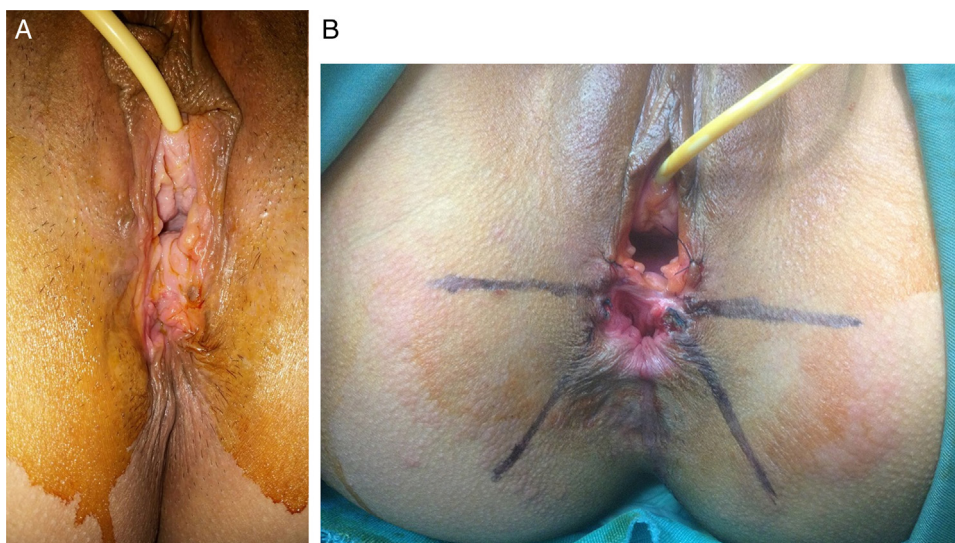
We considered the number of NVDs, BMI, age and the interval between the traumatic NVD and reconstructive operation. This information is tabulated in Table 1.

Also as you can find from Table 2, we collected the data of all 19 patients including the Faecal Incontinence (FI) score (according to the Wexner FI score in Appendix 1), Quality of Life (QoL form in Appendix 2), dyspareunia, life satisfaction in pre- and post-operation, post-op complications such as wound infection, recto-vaginal fistula and flap necrosis and satisfaction by the results of the surgery. For easy analyzing, we allocated a number to each patient.

### Results

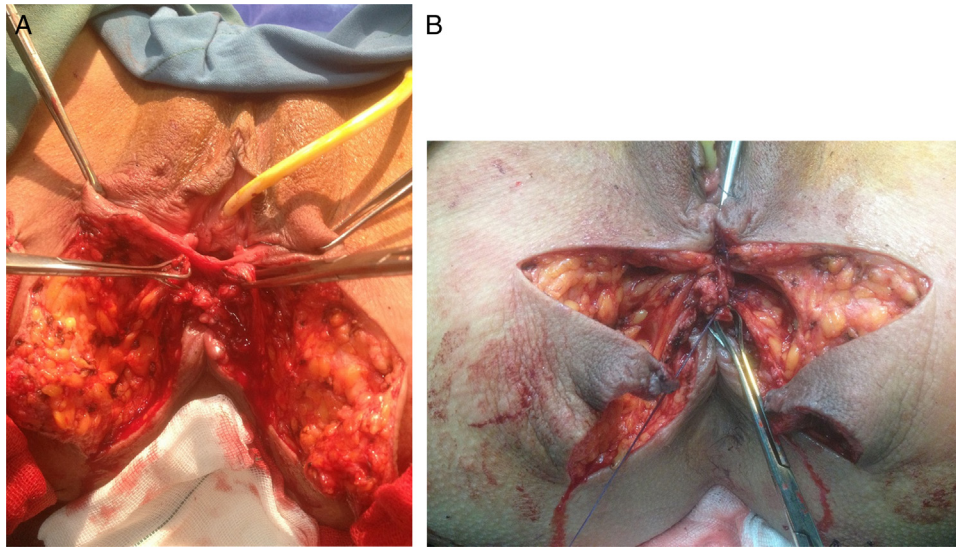
According to Table 1, the mean age of patients at the time of surgery was 35-yrs-old and the mean interval years between the traumatic NVD and the reconstructive surgery was 5.9-yrs. The mean BMI of the patients at the time of surgery was 26.63.

As it can be found from Table 2, of 19 patients who suffered from faecal incontinence, 3 of them (15%) were completely cured with the post-op score of 0/20, and there is a significant improvement in others. Incontinence to the solid stool was treated in 16 patients (84%) and 4 patients (21%) still suffered from incontinence to the liquid stool. The incontinence to the gas was completely cured in 3 patients (15%). Consequently the faecal incontinence score was significantly decreased in

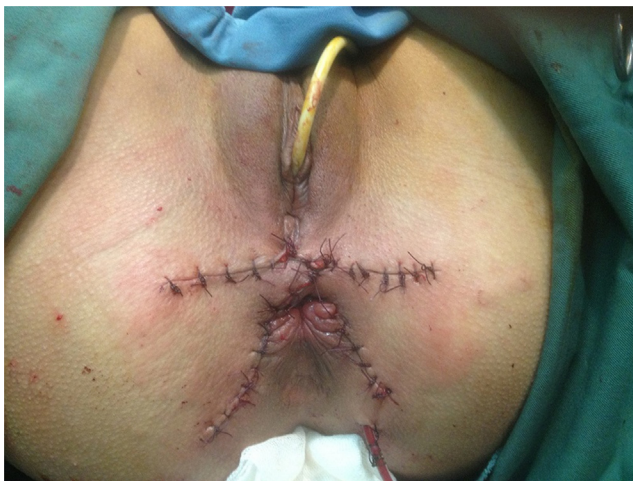

**Fig. 2 – (A) Placing the urinary catheter; (B) identifying the skin-flap.**





**Fig. 3 – (A) Separation of ano-rectum from the vagina by dissecting the recto-vaginal septum; (B) performance of sphincteroplasty in order to overlapping the internal and external sphincter.**

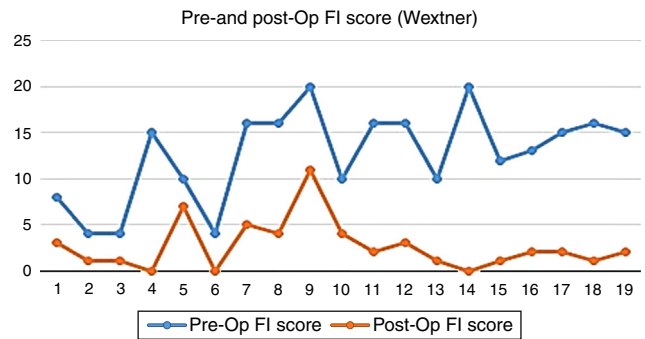


**Fig. 4 – Reconstruction of perineal skin with advancement flaps.**

all patients. The mean FI score was decreased from 12.7/20 to 2.6/20 (Fig. 5).

Of 18 patients who had sexual function after surgery, sexual function dissatisfaction in all of the patients was completely resolved (Fig. 6A).

Of 18 patients who had sexual function, the dyspareunia was cured in 9 patients. The score of this parameter was decreased from the mean of 5 to less than 1 (Fig. 6B).



**Fig. 5 – Comparison of pre- and post-op faecal incontinence score.**

The quality of life had a significant improvement and was increased from the mean of 45/119 to 95/119 (Fig. 7).

17 patients (89.47%) were satisfied and 2 patients (10.52%) were relatively satisfied from the results of surgery (Fig. 8).

As it can be found from Fig. 9, recto/vaginal fistula was occurred in one patient (5%) and wound infection in 2 patients (10%) which all of them were managed conservatively. There was no complication reported in the others.

Also we have investigated if there are any significant differences between the pre/post op values of the given variables by using SPSS ver. 20.

**Table 1 – Patients data.**

Patients	1	2	3	4	5	6	7	8	9	10	11	12	13	14	15	16	17	18	19
Age	25	29	33	30	71	58	20	37	32	39	42	33	41	27	27	30	33	38	32
BMI	25	23	29	27	30	20	25	31	23	27	26	28	30	34	26	30	22	27	25
Interval (-yrs)	4	2	4	1.5	20	10	8	5	2	1	20	3	10	4	1	10	3	3	2
Number of NVDs	3	2	1	1	5	10	1	2	1	4	2	3	5	2	1	1	1	3	2

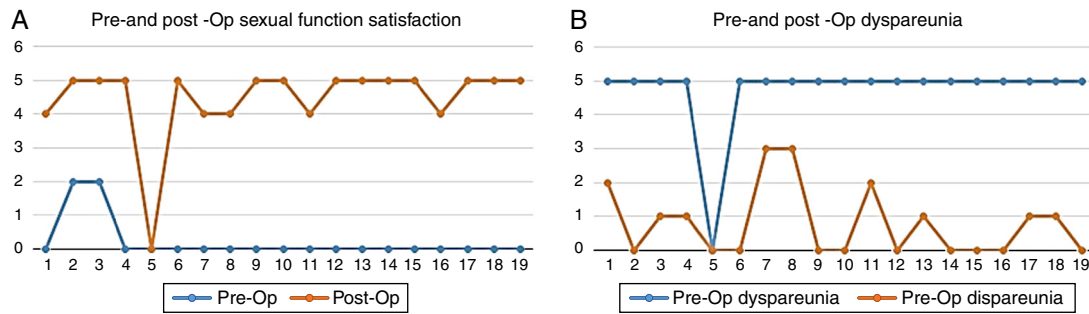


Fig. 6 – Changes in pre-op and post-op sexual function satisfaction (A) and dyspareunia (B).

Table 2 – Data of pre- and post-op.

Patients	Pre-op FI	Post-op FI	Pre-op dyspareunia	Post-op dyspareunia	Pre-op sexual function satisfaction	Post-op sexual function satisfaction	Pre-op QoL	Post-op QoL	Complication	Satisfaction
1	8/20	3/20	5/5	2/5	0/5	4/5	48/119	100/119	Wound infection	Yes
2	4/20	1/20	5/5	0/5	2/5	5/5	81/119	116/119	-	Yes
3	4/20	1/20	5/5	1/5	2/5	5/5	87/119	100/119	-	Yes
4 <sup>a</sup>	15/20	0/20	5/5	1/5	0/5	5/5	34/119	98/119	-	Yes
5	10/20	7/20	-	-	-	-	37/119	79/119	-	Relatively
6	4/20	0/20	5/5	0/5	0/5	5/5	82/119	102/119	Wound infection	Yes
7	16/20	5/20	5/5	3/5	0/5	4/5	36/119	87/119	-	Relatively
8	16/20	4/20	5/5	3/5	0/5	4/5	36/119	72/119	-	Yes
9	20/20	11/20	5/5	0/5	0/5	5/5	34/119	60/119	-	Yes
10	10/20	4/20	5/5	0/5	0/5	5/5	36/119	72/119	-	Yes
11	16/20	2/20	5/5	2/5	0/5	4/5	38/119	99/119	-	Yes
12	16/20	3/20	5/5	0/5	0/5	5/5	38/119	85/119	-	Yes
13	10/20	1/20	5/5	1/5	0/5	5/5	43/119	98/119	-	Yes
14	20/20	0/20	5/5	0/5	0/5	5/5	38/119	108/119	R. V. F. <sup>b</sup>	Yes
15	12/20	1/20	5/5	0/5	0/5	5/5	45/119	98/15	-	Yes
16	13/20	2/20	5/5	0/5	0/5	4/5	47/119	106/119	-	Yes
17	15/20	2/20	5/5	1/5	0/5	5/5	43/119	95/119	-	Yes
18	16/20	1/20	5/5	1/5	0/5	5/5	49/119	98/119	-	Yes
19	15/20	2/20	5/5	0/5	0/5	5/5	38/119	105/119	-	Yes

<sup>a</sup> The patient whose husband is dead and did not have sexual activity.  
<sup>b</sup> Recto-Vaginal Fistula.

By assuming that the acceptable of the (sig.) *p*-value is *p* < 0.05, the results show a significant difference between pre- and post op FI score, pre- and post op dyspareunia, pre- and post op sexual function satisfaction, and pre- and post op quality of life. *p*-value range of each parameter is tabulated in Table 3.

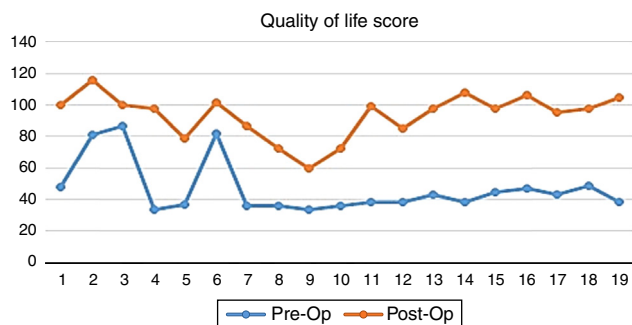


Fig. 7 – Post-surgical improvement of quality of life.

### Discussion

TCD is a rare complication of traumatic NVD which may lead to faecal incontinence, stress, social isolation and

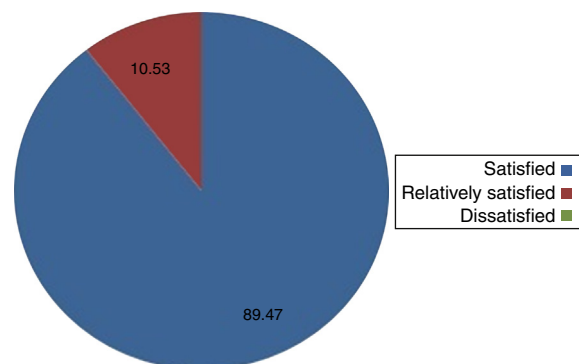
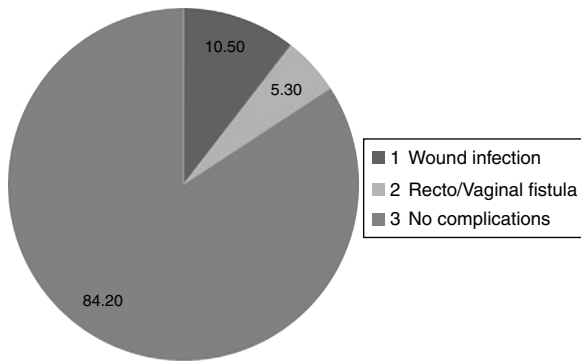


Fig. 8 – Post-surgical Satisfaction from the results of surgery.



**Fig. 9 – Post-op complications.**

physiological damages in a patient. Repair and reconstruction of perineal body and deformed organs for these patients is efficient. The vital part of such these procedures is precision while dissecting and dividing the ano-vaginal/recto-vaginal septum. There are several surgical techniques to treat the TCD and almost all of them have a significant impact to improve the physical and physiological conditions of the patients.

There are several articles in which the deformity of cloaca has been treated by using different techniques of reconstructive surgery.<sup>3,7–9</sup> In order to analyze the outcomes of the other surgeons with ours, we have compared our main variables with the others as follows.

#### Pre/post op FI score

In this study, faeces, liquid stool and gas incontinency was resolved in 84%, 78% and 15% of the patients, respectively. Also the mean FI score was decreased from 12.7 to 2.6.

In the Spanos's study on 4 patients, the mean FI score was decreased from 18 to 1.<sup>5</sup> In the Hollingshead's study on 29 patients, incontinence to faeces, liquid stool and gas was resolved in 100%, 50% and 40% of the patients, respectively.<sup>2</sup>

#### Pre/post op dyspareunia

In our study, from all 18 patients who had sexual function after the surgery, dyspareunia was completely resolved in 9 of them (50%). This parameter was decreased from the mean of 5 to 0.8 after the repair surgery.

In Spanos's study on 4 patients, one patient suffered from dyspareunia after the repair surgery.<sup>5</sup> In Venkatesh's study on 44 patients, 27% of them still suffered from dyspareunia.<sup>4</sup> In Abcarian's study on 43 patients, dyspareunia was resolved

in 15% of them.<sup>1</sup> In Hollinshead's study on 29 patients, dyspareunia was resolved in 9 patients.<sup>2</sup> In Valente's study, this parameter was resolved in all 4 patients who were underwent the study.<sup>8</sup>

#### Pre/post op sexual function satisfaction

In our study, the sexual function satisfaction was improved from the mean score of 0.2 to 4.7.

Hollingshead reported the improvement of sexual function satisfaction score in 9 patients from 29 patients in his study.<sup>2</sup> Spanos reported the improvement of sexual function satisfaction in all 4 patients of his study.<sup>5</sup>

#### Pre/post op quality of life

In our study, the quality of life score was increased from the mean of 45 to 95.

In Valenete's study on 4 patients, the quality of life in all patients was significantly improved.<sup>8</sup> In Altomar's study on one patient with 20-yrns follow-up plan, there was reported a significant improvement in quality of life.<sup>10</sup>

#### Post-op complications

We reported complications in 3 patients include wound infection in two patients (10%) and recto/vaginal fistula in one patient (5%). All 3 patients were cured by conservative treatment.

In Harjeet's study, wound infection was reported in all 4 patients.<sup>7</sup> In Kaiser's study on 12 patients, there was reported the recto/vaginal fistula in 5 patients.<sup>3</sup> In Spanos's study on 4 patients, there was no complication reported.<sup>5</sup> Hollingshead reported the recto/vaginal fistula in 3 patients (10%) and wound infection in 4 patients (14%) of all 29 patients.<sup>2</sup>

#### Conclusion

We have studied 19 patients who were referred to the hospital with symptoms of TCD between 2011 and 2015 at 3-months to 4-yrns with the mean of 2.6-yrns follow-up. They all underwent sphincteroplasty and perineoplasty with skin advancement flap. According to the significant improvements of FI score, dyspareunia, sexual function satisfaction and quality of life and also minimal complications in all patients of our study, this technique is recommended as an effective surgical method to treat the TCD in such patients. For patients with successful surgical repair of TCD, Caesarean section seems reasonable for the next delivery.

In such these cases, consulting with a colorectal surgeon may improve quality of life of the patients.

#### Conflicts of interest

The authors declare no conflicts of interest.

**Table 3 – p-Value of each variable.**

Variable	p-Value
Pre- and post-op FI	<0.05
Pre- and post-op QoL	<0.05
Pre- and post-op dyspareunia	<0.05
Pre- and post-op sexual function satisfaction	<0.05

---

## Acknowledgements

This article has been extracted from the thesis written by Dr. Omid Etemad in School of Medicine Shahid Beheshti University of Medical Sciences (Registration No.: 467).

---

## Appendix A. Supplementary data

Supplementary data associated with this article can be found, in the online version, at [doi:10.1016/j.jcol.2016.08.002](https://doi.org/10.1016/j.jcol.2016.08.002).

---

## REFERENCES

3. Kaiser AM. Cloaca-like deformity with fecal incontinence after severe obstetric injury-technique and functional outcome of ano-vaginal and perineal reconstruction with X-flaps and sphincteroplasty. *Colorectal Dis.* 2008;10:827-32.
4. Venkatesh KS, Ramanujam P. Surgical treatment of traumatic cloaca. *Dis Colon Rectum.* 1996;39:811-6.
5. Spanos CP, Mikos T, Kastanias E. Surgical treatment of traumatic cloaca. *Arch Gynecol Obstet.* 2012;286:815-8.
6. Kiff ES, Swash M. Slowed, "conduction in the pudendal nerves in idiopathic (neurogenic) fecal incontinence". *Br J Surg.* 1984;71:614-6.
7. Narula HS, Wadhawan H, Shorthouse AJ, Brown SR. Traumatic cloacal defect, the Warren flap revisited a description of the technique. *Polish Journal of Surgery.* 2010:687-93.
8. Valente MA, Khanduja KS. Layered surgical repair of traumatic cloacal deformities: technical details and functional outcomes. Springer; 2011. p. 153-6.
9. Draganic B, Solomon MJ. Island flap perineoplasty for coverage of perineal skin defects after repair of cloacal deformity. *ANZ J Surg.* 2001;71:487-90.
10. Altomare DF, Rinaldi M, Bucaria V, Marino F, Lobascio P, Sallustio PL. Overlapping sphincteroplasty and modified lotus petal flap for delayed repair of traumatic cloaca. *Tech Coloprocto.* 2007;11:268-70.

1. Abcarian H, Orsay CP, Pearl RK, Nelson Richard L, Briley Susan C. Traumatic cloaca. *Dis Colon Rectum.* 1989;32:783-7.
2. Hollingshead JRF, Warusavitarn J, Vaizey CJ, Northover JMA. Outcomes following repair of traumatic cloacal deformities. *Br J Surg.* 2009;96:1082-5.