



Original Article

Colonoscopy in the diagnosis of acute lower gastrointestinal bleeding



Igor Borba de Souza e Benevides^a, Carlos Henrique Marques dos Santos^{a,b,*}

^a Hospital Regional de Mato Grosso do Sul, Campo Grande, MS, Brazil

^b Sociedade Brasileira de Coloproctologia, Brazil

ARTICLE INFO

Article history:

Received 27 February 2016

Accepted 18 April 2016

Available online 9 September 2016

Keywords:

Colonoscopy

Lower gastrointestinal bleeding

ABSTRACT

Lower gastrointestinal bleeding is defined as a bleeding originated from a source distal to the Treitz ligament and the colonoscopy is well established as the diagnostic procedure of choice.

Objective: To evaluate the results of colonoscopies performed to diagnose the cause of acute lower gastrointestinal bleeding in a general hospital at Mato Grosso do Sul.

Material and methods: Colonoscopy procedures performed in the Endoscopy service of the Hospital Regional de Mato Grosso do Sul in those patients admitted due to an acute lower gastrointestinal bleeding from January 2014 to December 2015 were analyzed retrospectively. The studied variables were age, gender, diagnosis and localization of the lesion.

Results: The mean age was 66 years, and there was a little predominance of the male gender. Diverticular disease was the main cause of lower gastrointestinal bleeding in this study, followed by cancer, inflammatory gastrointestinal disease, polyps, and angiodysplasia.

Conclusion: The colonoscopy showed to be an effective diagnostic method in the case of acute lower gastrointestinal bleeding and a good therapeutic tool in the case of diverticular disease and angiodysplasia.

© 2016 Sociedade Brasileira de Coloproctologia. Published by Elsevier Editora Ltda. This is an open access article under the CC BY-NC-ND license (<http://creativecommons.org/licenses/by-nc-nd/4.0/>).

A colonoscopia no diagnóstico da hemorragia digestiva baixa aguda

RESUMO

Hemorragia digestiva baixa é definida como sangramento originado de uma fonte distal ao ligamento de Treitz e a colonoscopia esta bem estabelecida como o seu procedimento diagnóstico de escolha.

Palavras-chave:

Colonoscopia

Hemorragia digestiva baixa

* Corresponding author.

E-mail: chenriquems@yahoo.com.br (C.H. Santos).

<http://dx.doi.org/10.1016/j.jcol.2016.04.016>

2237-9363/© 2016 Sociedade Brasileira de Coloproctologia. Published by Elsevier Editora Ltda. This is an open access article under the CC BY-NC-ND license (<http://creativecommons.org/licenses/by-nc-nd/4.0/>).

Objetivo: Avaliar os resultados das colonoscopias realizadas para elucidação diagnóstica dos casos de Hemorragia digestiva baixa aguda em um Hospital Geral de Mato Grosso do Sul.

Materiais e métodos: Foram analisadas, de forma retrospectiva, as colonoscopias realizadas nos pacientes internados devido à hemorragia digestiva baixa aguda, no período de janeiro de 2014 a dezembro de 2015, no serviço de endoscopia digestiva do Hospital Regional de Mato Grosso do Sul. As variáveis estudadas foram a idade, sexo, diagnóstico e localização da lesão.

Resultados: A média de idade foi de 66 anos, com uma discreta predominância do sexo masculino. A doença diverticular foi a principal causa de hemorragia digestiva baixa nesse estudo, seguido de neoplasias, doença inflamatória intestinal, pólipos e angiodisplasia.

Conclusão: A colonoscopia mostrou-se como método efetivo no diagnóstico dos casos de Hemorragia digestiva baixa aguda e como uma boa ferramenta terapêutica também nos casos de angiodisplasia.

© 2016 Sociedade Brasileira de Coloproctologia. Publicado por Elsevier Editora Ltda. Este é um artigo Open Access sob uma licença CC BY-NC-ND (<http://creativecommons.org/licenses/by-nc-nd/4.0/>).

Introduction

Lower gastrointestinal bleeding is defined as a bleeding originated from a source distal to the ligament of Treitz. Despite the spontaneous cessation in 80% of cases of acute lower gastrointestinal bleeding, the identification of the bleeding source remains a challenging task and rebleeding can occur in up to 25% of cases.¹

Colonoscopy is defined as the diagnostic procedure of choice in the presence of acute lower gastrointestinal bleeding.^{2,3} Its diagnostic accuracy varies from 72% to 86%.⁴ Diverticular disease is the most common cause of lower intestinal bleeding, followed by polyps, malignancy, inflammatory bowel disease and angiodysplasia.⁵

A proper diagnosis of a clinical picture of acute lower gastrointestinal bleeding is of paramount importance, given its potential for rebleeding and, in addition, because this condition may be a manifestation of malignancy.

This study aimed to evaluate the results of colonoscopy procedures carried out in order to obtain a laboratory diagnosis of acute lower gastrointestinal bleeding in a general hospital of Mato Grosso do Sul.

Objective

To evaluate the results of colonoscopies performed to obtain a laboratory diagnosis of cases of acute lower gastrointestinal bleeding in a general hospital of Mato Grosso do Sul.

Materials and methods

Colonoscopies in patients hospitalized due to acute lower gastrointestinal bleeding were retrospectively evaluated from January 2014 to December 2015. Lower gastrointestinal bleeding was defined as the presence of intestinal bleeding, hematochezia, or melena when the occurrence of upper gastrointestinal bleeding was excluded by upper digestive endoscopy. The examinations were performed in the

Table 1 – The gender distribution of patients undergoing colonoscopy due to acute lower gastrointestinal bleeding.

Gender	Number of patients	%
Male	55	48.5
Female	52	41.5
Total	107	100

Endoscopy Service, Hospital Regional de Mato Grosso do Sul, and the data were collected from their electronic records.

The variables studied were:

1. Gender.
2. Age.
3. Diagnosis of injury.
4. The site of the lesion.

Patients with bleeding from orificial disease and those coming from the outpatient investigation were excluded.

Results

One hundred and seven patients were studied and with a slight predominance of males (Table 1). The mean age of patients was 66 years, ranging from 16 to 102 years. Of the total number of examinations performed, 21 (19.6%) were normal. At the time of the examination, 88.7% of patients no longer suffered an active bleeding.

The colonic disease most often found in this study was diverticular disease, accounting for 54.4% of cases, followed by neoplasias, inflammatory bowel disease, polyps and angiodysplasia (Fig. 1). As for gender distribution, we observed a higher frequency of inflammatory bowel disease as a cause of lower gastrointestinal bleeding in female patients (Fig. 2).

Diffuse diverticular disease was the condition most associated with lower gastrointestinal bleeding, followed by diverticulitis of the sigmoid colon (Fig. 3). Of the 31 patients with the diffuse diverticular disease, in 15 cases it was not possible to identify the precise focus of bleeding. Three patients

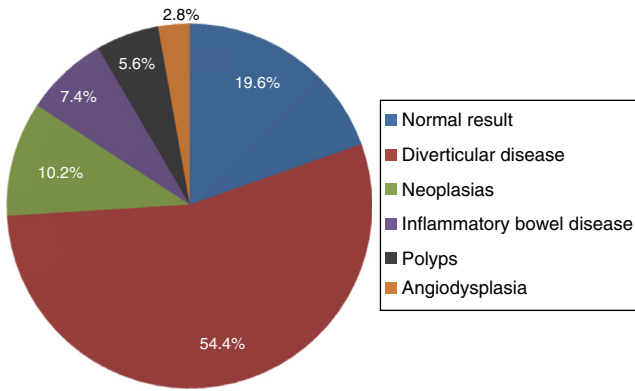


Fig. 1 – Main diagnoses found with colonoscopy.

had right colon bleeding, 1 in the transverse colon, and 3 in the sigmoid colon.

The neoplasias most often associated with bleeding were located in the rectum, followed by neoplasms (Fig. 4).

Inflammatory bowel diseases were more frequently found in women, especially diffuse colitis (71.4%). A man and two women had bleeding due to an unspecified proctitis.

Three patients had gastrointestinal bleeding due to angiodysplasia; two of these cases were located in the ascending colon and the third case was caused by rectal angiodysplasia.

Polyps were associated with six cases of bleeding, and three of them were located in the rectum, two in the sigmoid colon, and one in the ascending colon.

Discussion

Acute lower gastrointestinal bleeding is an emergency situation often found in emergency rooms. Taken into account that this bleeding affects a population with more advanced age, its consequences can be even more catastrophic.² With this in view, the definition of the bleeding site and its specific treatment are of paramount importance.⁵ Where available, colonoscopy should be used in these clinical pictures, considering its diagnostic accuracy and the possibility of its therapeutic use in particular circumstances.^{2,6}

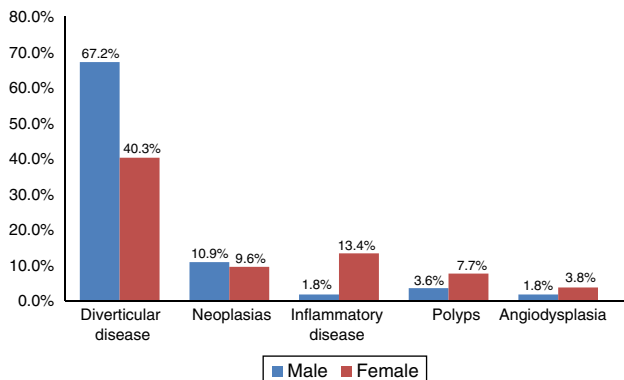


Fig. 2 – The gender distribution of diseases related to lower gastrointestinal bleeding.

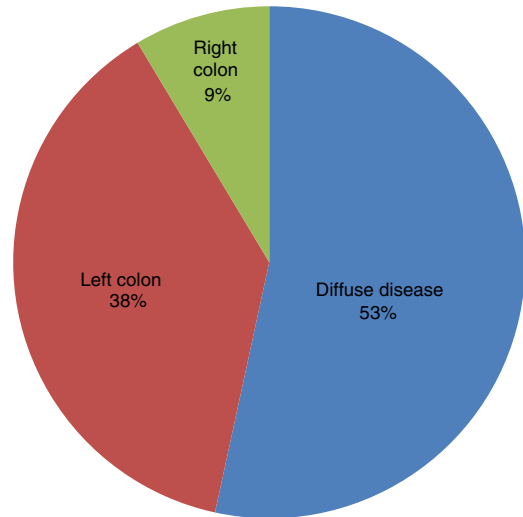


Fig. 3 – Distribution of sites of diverticular disease.

The colonoscopies were inconclusive in 19.6% of cases, a finding consistent with that found in the literature.⁴ Due to the limitations inherent to this method, a large area of the small intestine is not covered in the exam. In these cases and in cases where it was not possible to define the precise location of the lesion, one can make use of procedures such as scintigraphy and arteriography, for the definition of the bleeding site.⁶ Scintigraphy detects active bleeding with a volume from 0.1 to 0.5 mL/min and its main disadvantage is the inaccurate location of the focus of bleeding. On the other hand, arteriography is a more invasive method and requires a bleeding volume of 0.5 mL/min for its detection.⁶ Arteriography may also be used as a therapeutic tool. Embolization for hemorrhage due to a diverticular bleeding can reach a success rate of 85%.⁷ In the case of termination of the bleeding, enteroscopy and capsule endoscopy can be used to establish the diagnosis.⁶

In this study, diverticular disease presented itself as the most frequent cause of acute lower gastrointestinal bleeding.

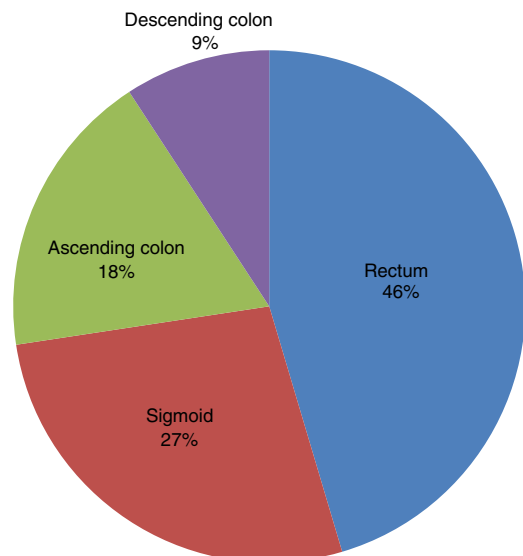


Fig. 4 – Distribution of sites of neoplasias.

This result is also supported in the literature. In a retrospective study by Gayler et al., in which 1112 patients with lower gastrointestinal bleeding were studied, diverticular disease was also presented as the most frequent cause, followed by cancer, when anorectal diseases are excluded.⁸

In up to 17% of cases, colorectal neoplasms may present as the cause of intestinal bleeding. However, it is more common that such conditions are presented in the form of occult bleeding in stool.⁹ Rectal cancer was more related to hemorrhagic episodes. In his study, Lopes noted that left colon cancer had a greater relationship with a picture of acute lower gastrointestinal hemorrhage. Classically, we found in the literature that right colon cancers are more closely related to occult bleeding in stool, while hematochezia is more related to left colon tumors, and generally these are chronic and slowly progressive bleedings. Bleedings of largest volumes are usually related to more advanced tumors.¹⁰

Inflammatory bowel disease was more common in women than in men, surpassing even cancer as a cause of bleeding; these data are similar to those of Bounds et al.² All cases of bleeding secondary to inflammatory bowel disease were classified as unspecified colitis or rectitis. This is probably due to the difficulty of the endoscopist in determining the etiology, without having access to more detailed information on the patient.¹¹

In this study, angiodysplasias and polyps were infrequent causes of lower intestinal bleeding. In 22.8% of cases, Lopes et al. attributed to colon and rectum polyps the cause of intestinal bleeding. On the other hand, these authors found that no cases of gastrointestinal bleeding were associated with angiodysplasia.¹² In more aged populations, angiodysplasias increase in frequency, and these conditions may be responsible for up to 30% of cases of hemorrhage diagnosed by endoscopy.¹³ The colonoscopy can also be used therapeutically in cases of angiodysplasia, through the use of argon plasma, sclerosing substances, or thermal contact probes.⁶ In the present study, all cases of angiodysplasia were treated successfully by endoscopy, with the use of argon plasma.

Conclusion

Colonoscopy has proven to be an effective method in the diagnosis of cases of acute lower gastrointestinal bleeding, being also a good therapeutic tool in cases of diverticular disease and angiodysplasia. Diverticular disease was the disease most often associated with these cases, followed by neoplasms.

The high frequency of neoplasms that manifest themselves through intestinal bleeding demonstrates the importance of colonoscopy in these cases.

Conflicts of interest

The authors declare no conflicts of interest.

REFERENCES

1. Edelman DA, Sugawa C. Lower gastrointestinal bleeding: a review. *Surg Endosc.* 2007;21:514-20.
2. Bounds BC, Kelsey PB. Lower gastrointestinal bleeding. *Gastrointest Endosc Clin N Am.* 2007;17:273-88.
3. Ferreira RPB, Eisig JN. Projeto Diretrizes Hemorragias digestivas. Federação Brasileira de Gastroenterologia; 2008.
4. Farrell JJ, Friedman LS. Review article: the management of lower gastrointestinal bleeding. *Aliment Pharmacol Ther.* 2005;21:1281-98.
5. Ornellas AT, Ornellas LC, Souza AFM, Gaburri PD. Hemorragia Digestiva Aguda Alta e Baixa. In: Dani R, editor. *Gastroenterologia Essencial.* 2 ed. Rio de Janeiro: Editora Guanabara Koogan S.A.; 2001. p. 3-14.
6. Cardoso Filho CAM, Marques OW Jr, Popoutchi P, Averbach M. Projeto Diretrizes: Hemorragia digestiva baixa. *Soc Bras Endosc Dig.* 2010.
7. Khanna A, Oqribene SJ, Koniaris LG. Embolization as first-line therapy for diverticulosis-related massive lower gastrointestinal bleeding: evidence from a meta-analysis. *J Gastrointest/Surg.* 2005;9:343-52.
8. Gayler C, Chino A, Lucas C, Tokioka S, Yamasaki T, Edelman DA, et al. Acute lower gastrointestinal bleeding in 1,112 patients admitted to an urban emergency medical center. *Surgery.* 2009;146:600-6.
9. Barnert J, Messmann H. Diagnosis and management of lower gastrointestinal bleeding. *Nat Rev Gastroenterol Hepatol.* 2009;6:637-46.
10. Longstreth GF. Epidemiology and outcome of patients hospitalized with acute lower gastrointestinal hemorrhage: a population-based study. *Am J Gastroenterol.* 1997;92:419-24.
11. Dos Santos CHM, Cury MS, Saad FT. Principais achados de colonoscopias realizadas em caráter de urgência e eletivas. *Rev Bras Coloproct.* 2009;29:83-7.
12. Lopes AD Jr, Ahuaji VM, Lourenção JL, Rodrigues AJ Jr, Birolini D. O papel da colonoscopia na hemorragia digestiva baixa aguda. *Rev Bras Coloproct.* 1998;18:164-7.
13. Cutait R, Averbach M, Corrêa PAFP. Endoscopia Digestiva Baixa. In: Coelho J, editor. *Aparelho Digestivo: clínica e cirúrgica.* 3 ed. São Paulo: Editora Atheneu; 2006. p. 174-91.