



Case Report

Inflammatory cloacogenic polyp: a rare kind of benign polyp to be cured with endoscopic and/or surgical removal



Şafak Meriç Özgenel*, Tuncer Temel, Evrim Yılmaz, Salih Tokmak, Ayşegül Özakyol

Eskişehir Osmangazi University, Faculty of Medicine, Department of Gastroenterology, Eskişehir, Turkey

ARTICLE INFO

Article history:

Received 11 January 2016

Accepted 13 April 2016

Available online 9 May 2016

Keywords:

Inflammation

Solitary rectal ulcer

Cloacogenic polyp

ABSTRACT

Background: Inflammatory cloacogenic polyp is a very rare kind of benign polyp which occurs in the anal transitional zone and lower rectum. These polyps arise in association with various conditions (e.g., internal hemorrhoids, diverticulosis, colorectal tumors, and Crohn's disease) in which mucosal injury is the underlying pathogenic mechanism.

Case report: A 24-year-old male patient applied to emergency department with bloody defecation for a month. A polyp that is 1.5 cm in size had been observed at rectum and anal verge junction during colonoscopy, pathological diagnosis was inflammatory cloacogenic polyp. Thereupon, colonoscopic polypectomy was performed as the malignant transformation possibility.

Conclusion: Polyps of the anorectal junction with inflammatory appearance might be inflammatory cloacogenic polyps with malignant transformation potential that must be treated by endoscopic removal or surgery and followed up routinely with colonoscopic surveillance.

© 2016 Sociedade Brasileira de Coloproctologia. Published by Elsevier Editora Ltda. This is an open access article under the CC BY-NC-ND license (<http://creativecommons.org/licenses/by-nc-nd/4.0/>).

Pólipo cloacogênico inflamatório: um raro tipo de pólipo benigno a ser curado por remoção endoscópica e/ou cirúrgica

RESUMO

Experiência: Pólipos cloacogênicos inflamatórios constituem um tipo muito raro de pólipo benigno, com ocorrência na zona de transição anal e reto baixo. Esses pólipos surgem em associação com diversos distúrbios (p. ex., hemorroidas internas, diverticulose, tumores colorretais, e doença de Crohn) nos quais a lesão à mucosa é o mecanismo patogênico subjacente.

Palavras-chave:

Inflamação

Úlcera retal solitária

Pólipo cloacogênico

* Corresponding author.

E-mail: mozgenel@ogu.edu.tr (Ş.M. Özgenel).

<http://dx.doi.org/10.1016/j.jcol.2016.04.005>

2237-9363/© 2016 Sociedade Brasileira de Coloproctologia. Published by Elsevier Editora Ltda. This is an open access article under the CC BY-NC-ND license (<http://creativecommons.org/licenses/by-nc-nd/4.0/>).

Relato de caso: Paciente, gênero masculino, 24 anos, compareceu ao serviço de emergência com defecação sanguinolenta com duração de um mês. Durante a colonoscopia, foi observado um pólipso medindo 1,5 cm de diâmetro no reto e na junção da borda anal; foi estabelecido um diagnóstico patológico de pólipso cloacogênico inflamatório. Subsequentemente, foi realizada polipectomia colonoscópica, diante do potencial de transformação maligna.

Conclusão: Pólipos da junção anorretal com aspecto inflamatório podem ser pólipos cloacogênicos inflamatórios com potencial para transformação maligna, devendo ser tratados por remoção endoscópica ou cirúrgica e monitorados periodicamente com vigilância colonoscópica.

© 2016 Sociedade Brasileira de Coloproctologia. Publicado por Elsevier Editora Ltda. Este é um artigo Open Access sob uma licença CC BY-NC-ND (<http://creativecommons.org/licenses/by-nc-nd/4.0/>).

Introduction

Inflammatory cloacogenic polyp (ICP) is a very rare kind of benign polyp to be cured with endoscopic and/or surgical removal that was first described in 1981 by Lobert et al.¹ These polyps arise in association with various conditions (e.g., internal hemorrhoids, diverticulosis, colorectal tumors, and Crohn's disease) in which mucosal injury is the underlying pathogenic mechanism.² ICPs occur in the anal transitional zone and lower rectum.³ Although ICPs are generally benign, occasional malignant transformation has been reported.⁴

We represent a case of cloacogenic polyp, an infrequently diagnosed type of polyp, which causes lower gastrointestinal bleeding.

Case report

A 24-year-old male patient applied to emergency department with bloody defecation for a month. On laboratory analyzes, biochemistry panel, complete blood count, sedimentation and C-reactive protein was normal. Either fecal culture or fecal analyses for parasites were negative. A polyp that is 1.5 cm in size had been observed at rectum and anal verge junction during colonoscopy which was performed to determine the reason of bloody defecation. (Fig. 1). In the pathological analyzes of the polyp, vessels were stained with CD34 and histiocytes were stained with CD68, fibromuscular fields in the lamina propria were stained with trichrome, no fungal spores or hyphae nutrients were seen with periodic acid schiff, there was no pathological feature with cyto-keratin immuno-histochemical staining. The defining pathological diagnosis was ICP; with ulcers, minimal architectural distortion, hyperplastic changes and regenerative atypia, fibromuscular hyperplasia in the lamina propria, and vessel rich colonic polypoid tissues (Figs. 2 and 3). Thereupon, colonoscopic polypectomy was performed as the malignant transformation possibility.

Discussion

ICPs of the anal transitional zone were first described in 1981 by Lobert PF and Appelman HD. Rectal bleeding is the most

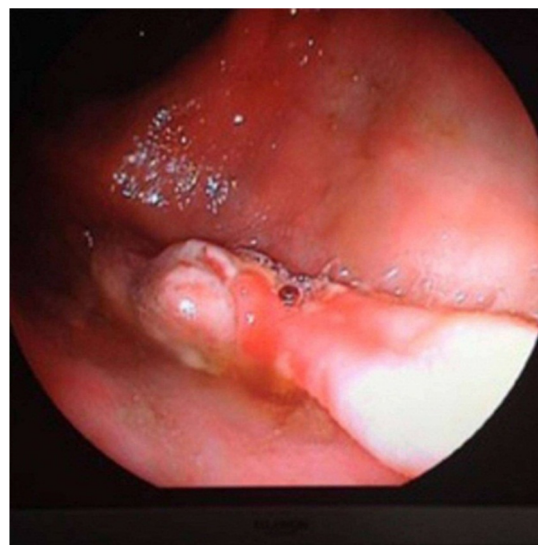


Fig. 1 – Colonoscopic appearance of the inflammatory cloacogenic polyp.

common presenting clinical symptom. The polyp is usually located on the anterior wall of the anal canal. Morphologically, it is characterized by a tubule-villous pattern of growth, superficial ulceration, displaced groups of crypts into sub-mucosa, and extension of chronically inflamed fibromuscular stroma into the lamina propria. Clinical and morphologic similarities with the solitary rectal ulcer syndrome suggests that prolapse of transitional zone mucosa may take an important part in the pathogenesis.¹ The most characteristic feature of solitary rectal ulcer is obliteration of the lamina propria of the mucous membrane in the region of the ulcer by fibroblasts and muscle fibers derived from the muscularis mucosae. The fibroblasts lay down collagen which is intimately mixed with the muscle fibers and together they stream toward the mucosal surface between the epithelial tubules. The muscularis mucosae is often thicker than normal and its fibers are splayed and in continuous with those in the lamina propria. The latter shows no significant increase in the numbers of inflammatory cells.⁵ ICP can be associated with conditions such as Crohn's disease, malabsorption syndromes, diverticulosis, hemorrhoids and adenocarcinoma. Abib et al.'s research

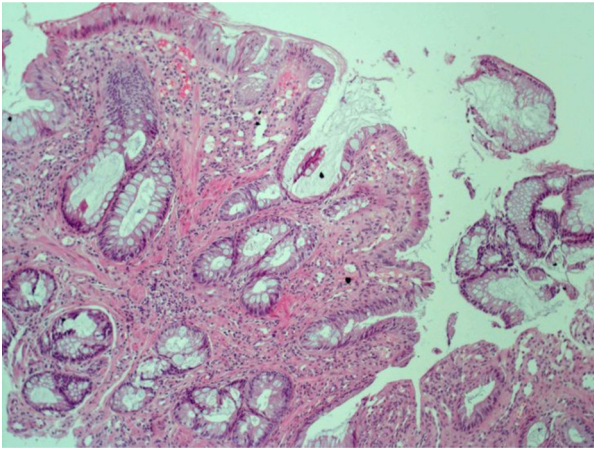


Fig. 2 – Elongated, irregular crypt structures, hyperplastic changes in the lamina propria fibromuscular hyperplasia and chronic inflammation (hematoxylin eosine × 100).

of 116 cases revealed that solitary rectal ulcers might also be found coexisting with polyps, ulcerative colitis, hemorrhoids and colonic malignancy.⁶

ICPs are more common in women usually occurring from childhood to the fourth–the sixth decade of life.^{7,8} Leading complaints are rectal bleeding, constipation and rectal tenesmus.⁸ Diagnosis is usually reached by endoscopy and biopsy. It is difficult to be differentiated from other benign and malignant lesions during endoscopy.⁴ These polyps are usually 1–5 cm in the anorectal region and often sessile, and rarely occurs with peduncle. They may be single or multiple and can be found simultaneous with hyperplastic or adenomatous polyps. Anatomic-pathologic properties are, eroded surface, reactive atypia and hyperplastic changes with irregular branching in glands and granulation tissue.^{8,9}

Transformation to squamous cell carcinoma for ICP's are mentioned. Dysplasia was detected in cases of Parfitt et al.⁴ and Hanson and Armstrong found anal intra epithelial neoplasia in his case.¹⁰ P53 and Ki67 immuno-histochemistry must be performed to interpret challenging cases by pathologists. He also simultaneously detected the presence of human papilloma virus (HPV). Therefore, HPV screening should be considered for the ICP background.

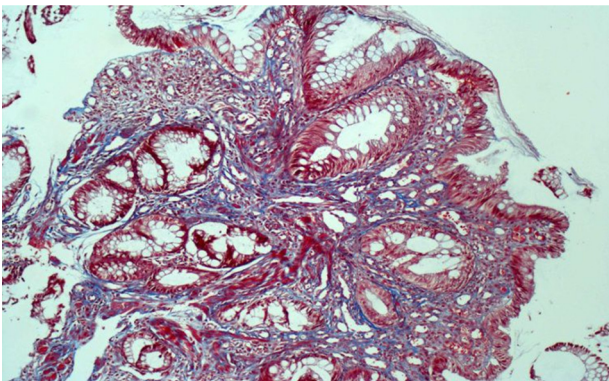


Fig. 3 – Increased collagen fibers and smooth muscle fibers in the lamina propria with trichrome (100×).

On differential diagnosis, inflammatory, ischemic or other types of polyps, inflammatory bowel disease, Cowden syndrome and malignancies must be considered.⁸

Endoscopic removal or surgical treatment is applied for treatment,² patients must take high fiber diet with colonoscopic surveillance after polypectomy or surgical resection because of the recurrence risk.³

In conclusion, it must be bear in mind that polyps of the anorectal junction with inflammatory appearance might be ICPs with malignant transformation potential that must be treated by endoscopic removal or surgery and followed up routinely with colonoscopic surveillance. Cases with ICPs must be investigated for underlying Crohn's disease, malabsorption syndromes, diverticulosis, hemorrhoids, adenocarcinoma and HPV infection. For pathological diagnosis of challenging cases immuno-histochemical staining could be beneficial.

Conflicts of interest

The authors declare no conflicts of interest.

Acknowledgements

The work conforms to the provisions of the Declaration of Helsinki and the written consent of the subject has been acknowledged.

REFERENCES

1. Lobert PF, Appelman HD. Inflammatory cloacogenic polyp: a unique inflammatory lesion of the anal transitional zone. *Am J Surg Pathol.* 1981;5:761–6.
2. Tendler DA, Aboudola S, Zacks JF, O'Brien MJ, Kelly CP. Prolapsing mucosal polyps: an unrecognized form of colonic polyps a clinic pathological study in 15 cases. *Am J Gastroenterol.* 2002;97:370–6.
3. Zaman S, Mistry P, Hendrickse C, Bowley DM. Cloacogenic polyps in an adolescent: a rare cause of rectal bleeding. *J Pediatr Surg.* 2013;48:E5–7.
4. Parfitt JR, Shepherd NA. Polypoid mucosal prolapsed complicating low rectal adenomas: beware the inflammatory cloacogenic polyp! *Histopathology.* 2008;53:91–6.
5. Madigan MR, Morson BC. Solitary ulcer of the rectum. *Gut.* 1969;10:871–81.
6. Abib S, Khawaja A, Bhimani SA, Ahmad Z, Hamid S, Jafri W. The clinical, endoscopic and histological spectrum of the solitary rectal ulcer syndrome: a single-center experience of 116 cases. *BMC Gastroenterol.* 2012;12:72.
7. Poon K, Mills S, Booth L, Murphy S. Inflammatory cloacogenic polyp: an unrecognized cause of hematochezia and tenesmus in childhood. *J Pediatr.* 1997;130:327–9.
8. López-Ramos CS, Rodríguez-Gómez S, Bailador-Andrés C, Baizán-García MJ. Inflammatory cloacogenic polyp: a rare cause of lower gastrointestinal bleeding. *Rev Esp Enferm Dig.* 2013;105:240–1.
9. Mathialagan R, Turner MJ, Gorard DA. Inflammatory cloacogenic polyp mimicking anorectal malignancy. *Eur J Gastroenterol Hepatol.* 2000;12:247–50.
10. Hanson IM, Armstrong GR. Anal intraepithelial neoplasia in an inflammatory cloacogenic polyp. *J Clin Pathol.* 1999;52:393–4.