



Case Report

Jejunal diverticulitis as a cause of acute abdomen[☆]



Cássio Alfred Brattig Cantão^a, Marley Ribeiro Feitosa^{a,*}, Maurício Godinho^b,
Sandro Scarpelini^b, Omar Féres^a, José Joaquim Ribeiro da Rocha^a

^a Division of Coloproctology, Department of Surgery and Anatomy, Faculdade de Medicina de Ribeirão Preto, Universidade de São Paulo (USP), Ribeirão Preto, SP, Brazil

^b Division of Emergency Surgery, Department of Surgery and Anatomy, Faculdade de Medicina de Ribeirão Preto, Universidade de São Paulo (USP), Ribeirão Preto, SP, Brazil

ARTICLE INFO

Article history:

Received 3 March 2015

Accepted 28 August 2015

Available online 21 December 2015

Keywords:

Jejunum

Diverticulum

Diverticulitis

Acute abdomen

ABSTRACT

Jejunoleal diverticulosis is an uncommon and underdiagnosed condition. Most patients are asymptomatic and require no specific treatment. A few patients, however, present life-threatening complications that may require surgical intervention. The purpose of this report is to illustrate a case of jejunoleal diverticulosis manifested as an acute abdomen.

© 2015 Sociedade Brasileira de Coloproctologia. Published by Elsevier Editora Ltda. All rights reserved.

Abdome agudo por diverticulite de jejuno

RESUMO

A doença diverticular do intestino delgado é uma entidade incomum e pouco diagnosticada. A maioria dos casos não apresenta sintomas e não necessita de tratamento específico. Alguns pacientes, no entanto, podem evoluir com complicações da doença e necessitar de tratamento cirúrgico. O objetivo deste relato é ilustrar um caso de diverticulose jejunal que evoluiu para um quadro de abdome agudo.

© 2015 Sociedade Brasileira de Coloproctologia. Publicado por Elsevier Editora Ltda. Todos os direitos reservados.

Palavras-chave:

Jejuno

Divertículo

Diverticulite

Abdome agudo

[☆] Study conducted at the Department of Surgery and Anatomy, Faculdade de Medicina de Ribeirão Preto, Universidade de São Paulo (USP), Ribeirão Preto, SP, Brazil.

* Corresponding author.

E-mail: marleyfeitosa@yahoo.com.br (M.R. Feitosa).

<http://dx.doi.org/10.1016/j.jcol.2015.08.007>

2237-9363/© 2015 Sociedade Brasileira de Coloproctologia. Published by Elsevier Editora Ltda. All rights reserved.

Introduction

Jejunioleal diverticulosis (JID) was first described by Soemmering and Baille in 1794.¹ The disease is characterized by false diverticula (herniation of the mucosa and serosa through the muscular wall) and occurs at the mesenteric attachment of the gut.² JID is an uncommon condition, affecting 0.02–4.6% of the population.^{3,4} The course is usually asymptomatic, but up to 40% of the patients may experience chronic pain or malabsorption.⁵ The aim of this report is to illustrate an acute complication of JID.

Case report

A 77-year-old man was admitted to the emergency department with a three-day history of a progressive abdominal pain, vomiting and fever. Physical exam revealed diffuse abdominal pain with rigidity, guarding and rebound tenderness in the right lower quadrant. The abdomen was also distended with decreased bowel sounds. The white blood cell count was normal. C-reactive protein was 19.64 mg/L. Abdominal plain radiograph revealed dilated small-bowel loops with air-fluid levels. CT scanning of the abdomen evidenced agglomerated jejunal loops with wall thickening in the iliac fossa (Fig. 1).

The patient underwent a therapeutic laparotomy that identified diverticular disease of the jejunum. The largest diverticulum measured 5 cm × 4 cm and was adhered to the ileum and cecum with remarkable inflammation. A 15 cm enterectomy with a manual end-to-end anastomosis was performed (Fig. 2). Histopathological study diagnosed an absceding diverticulitis in the surgical specimen.

The patient made a full recovery and was discharged on the fourth day after the surgery.

Discussion

Most patients with JID are asymptomatic. Forty percent, however, experience non-specific symptoms such as vague

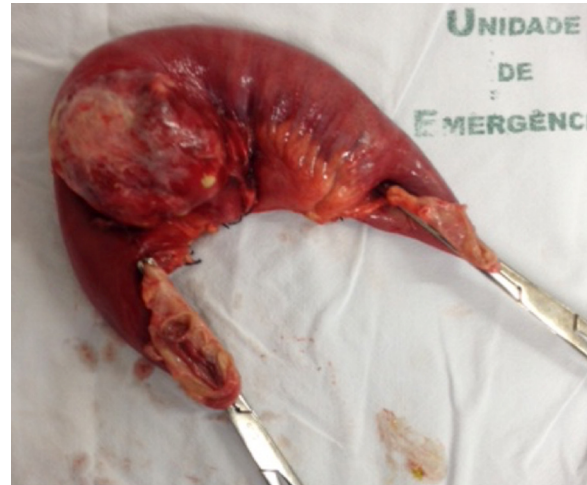

Fig. 2 – Resected segment of jejunum evidencing a large diverticulum with marked inflammation.

abdominal pain, nausea and occasional vomiting caused by an intestinal dyskinesia.⁶ In almost 70% of the cases, multiple diverticula are found. Some diverticula may reach more than 5 cm, although size does not correlate to symptoms.⁵ Duodenal diverticula are three times more common but jejunioleal disease is more likely to complicate. Complications, such as inflammation, bleeding and obstruction are found in 10% of the patients and are commonly misdiagnosed as appendicitis, cholecystitis, peptic ulcer or colonic diverticulitis.⁷

Due to its vague clinical repercussion and relatively inaccessible anatomic location, preoperative identification of JID is uncommon and challenging for clinicians and surgeons. In the context of complicated disease, usually manifested as an acute abdomen, the surgeon must be aware of this possibility to avoid misdiagnosis and treatment delay. Plain radiographs, ultrasound and CT scans of the abdomen may be useful to help the diagnosis of JID complicated with inflammation/perforation or obstruction.⁸⁻¹⁰ Endoscopy, gastrointestinal bleeding scintigraphy and arteriography may be

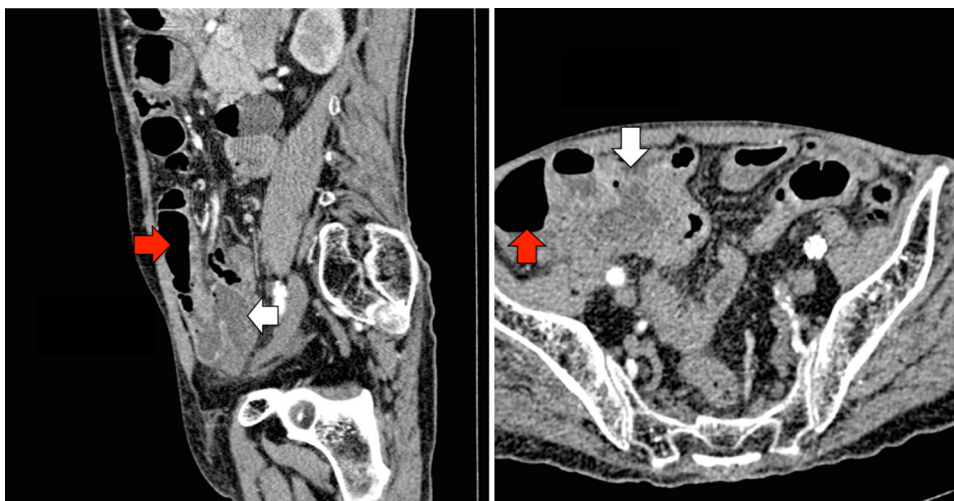


Fig. 1 – Computed tomography of the abdomen evidencing an agglomeration of small bowel loops (white arrows) with upstream dilation (red arrows).

of great value in the setting of a gastrointestinal hemorrhage. Surgery (laparoscopy/laparotomy) is the gold standard for definite diagnosis and treatment of complicate JID.^{11,12}

Asymptomatic patients require no specific intervention. Those with signs of intestinal dyskinesia should have their symptoms treated. Elective surgery should be reserved for patients with refractory symptoms but results are controversial. An enterectomy of the affected segment with primary end-to-end anastomosis is the standard treatment. Indications for urgent surgery are the same as in any other cause of acute abdomen and must not be neglected under the risk of higher mortality rates, that may reach 40% in some reports.¹³⁻¹⁵

Conclusion

Jejunioleal diverticulosis is an uncommon and potentially life-threatening condition. Symptoms of the disease are unspecific and related to intestinal dyskinesia but most patients have no gastrointestinal manifestations. Treatment is usually directed to relieve symptoms and surgery is best indicated to those patients with refractory symptoms or acute complications, such as inflammation with perforation, bleeding and obstruction.

Conflicts of interest

The authors declare no conflicts of interest.

REFERENCES

1. Soemmering ST, Baille M. Anatomie des krankhaften Baues von einigen der wichtigsten Theile in menschlichen Körper. Berlin: Vossische Buchhandlung; 1794. p. 1-97.
2. Fischer MH. False diverticula of the intestine. *J Exp Med.* 1901;5:333-52.
3. Rankin FW, Martin WJ. Diverticula of the small bowel. *Ann Surg.* 1934;100:1123-35.
4. Orr IM, Russel JYW. Diverticulosis of jejunum: a clinical entity. *Br J Surg.* 1951;39:139-47.
5. Tsiotos GG, Farnell MB, Ilstrup DM. Nonmeckelian jejunal or ileal diverticulosis: an analysis of 112 cases. *Surgery.* 1994;116:726-31.
6. Altemeier WA, Bryant LR, Wulsin JH. The surgical significance of jejunal diverticulosis. *Arch Surg.* 1963;86:732-44.
7. Meagher AP, Porter AJ, Rowland R, Ma G, Hoffmann DC. Jejunal diverticulosis. *Aust N Z J Surg.* 1993;63:360-6.
8. Hibbeln JF, Gorodetsky AA, Wilbur AC. Perforated jejunal diverticulum: CT diagnosis. *Abdom Imaging.* 1995;20:29-30.
9. Lieberman JM, Haaga JR. Computed tomography of diverticulitis. *J Comput Assist Tomogr.* 1983;7:431-3.
10. Govindan VK, Balashanmugam. Acute intestinal obstruction due to solitary jejunal diverticulum. *Indian J Gastroenterol.* 2002;21:204.
11. Longo WE, Vernava AM 3rd. Clinical implications of jejunioleal diverticular disease. *Dis Colon Rectum.* 1992;35:381-8.
12. Cross MJ, Snyder SK. Laparoscopic-directed small bowel resection for jejunal diverticulitis with perforation. *J Laparoendosc Surg.* 1993;3:47-9.
13. Koger KE, Shatney CH, Dirbas FM, McClenathan JH. Perforated jejunal diverticula. *Am Surg.* 1996;62:26-9.
14. Makris K, Tsiotos GG, Stafyla V, Sakorafas GH. Small intestinal nonmeckelian diverticulosis. *J Clin Gastroenterol.* 2009;43:201-7.
15. Patel VA, Jefferis H, Spiegelberg B, Iqbal Q, Prabhudesai A, Harris S. Jejunal diverticulosis is not always a silent spectator: a report of 4 cases and review of the literature. *World J Gastroenterol.* 2008;14:5916-9.