



Journal of Coloproctology

www.jcol.org.br



Original Article

The importance of three-dimensional anorectal ultrasound in the study of patients with anal pain



Doryane Maria dos Reis Lima^{a,b,*}, Univaldo Etsuo Sagae^{a,b}, Gustavo Kurachi^{a,b},
Salua Hamaoui^{a,b}, Tomaz Massayuki Tanaka^{a,b}, Mauro Willemann Bonatto^{a,b},
Ricardo Shigueo Tsuchiya^{a,b}, Carlos Alberto de Carvalho^{a,b}

^a Medical Course, Faculdade Assis Gurgacz (FAG), Cascavel, PR, Brazil

^b Gastroclínica Cascavel Ltda., Cascavel, PR, Brazil

ARTICLE INFO

Article history:

Received 14 May 2014

Accepted 12 September 2014

Available online 29 January 2015

Keywords:

Anal pain

Anorectal ultrasound

Intersphincteric sepsis

ABSTRACT

Objectives: Anal pain can be caused by various medical conditions; the exclusion of organic causes for proper treatment is important. Three-dimensional anorectal ultrasound can identify organic causes of anal pain. The objective of this study was to evaluate the importance of three-dimensional anorectal ultrasound in the detection of organic abnormalities in patients with anal pain.

Methods: Twenty-two patients (mean age: 49 years; 13 women) with chronic anal pain were enrolled to join a prospective study between June 2009 and June 2011. A complete proctology and colonoscopy examination was normal. Subsequently, the patients underwent three-dimensional anorectal ultrasound.

Results: Intersphincteric sepsis was found in 14 patients (63.6%). Two female patients (9.1%) had anal sphincter injury, one of them with the presence of a grade II rectocele. There was an increase in the thickness of the subepithelial tissue in three patients (13.6%). In one patient (4.6%), the presence of a hypoechoic circular retrorectal (presacral) cyst of the middle and lower rectum was observed. The three-dimensional anorectal ultrasound examination showed no abnormalities in two patients (9.1%).

Conclusion: The three-dimensional anorectal ultrasound is a simple, economical, fast and useful test for the study of anorectal diseases and should be included in the examination of patients with anal pain, to exclude organic causes.

© 2015 Sociedade Brasileira de Coloproctologia. Published by Elsevier Editora Ltda. All rights reserved.

* Corresponding author.

E-mail: doryane@gmail.com (D.M.d.R. Lima).

<http://dx.doi.org/10.1016/j.jcol.2014.09.002>

2237-9363/© 2015 Sociedade Brasileira de Coloproctologia. Published by Elsevier Editora Ltda. All rights reserved.

A importância da ultra-sonografia anorretal tridimensional no estudo de pacientes portadores de dor anal

R E S U M O

Palavras-chave:

Dor anal
Ultrasomendotorretal
Sepse interesfincteriana

Objetivos: A dor anal pode resultar várias condições clínicas e se faz necessário excluir causas orgânicas para o tratamento adequado. A ultra-sonografia anorretal tridimensional (3D-US) pode identificar causas orgânicas de dor anal. O objetivo deste estudo foi avaliar a importância da 3D-US para detectar anomalias orgânicas em pacientes com dor anal.

Métodos: Vinte e dois pacientes (média de idade: 49 anos; treze mulheres) com dor anal crônica foram incluídos em um estudo prospectivo entre junho de 2009 e junho de 2011. O exame proctológico completo e colonoscopia foram normais. Posteriormente, os pacientes foram submetidos à 3D-US.

Resultados: Sepse interesfincteriana foi evidenciada em quatorze pacientes (63,6%). Duas pacientes (9,1%) apresentaram lesão do esfíncter anal, sendo uma com presença de retocelce grau II. O aumento da espessura do tecido subepitelial apresentou-se em três pacientes (13,6%). Em um paciente (4,6%), foi evidenciada a presença de cisto retrorretal circular hipocóico no reto médio e inferior. O exame de US-3D não evidenciou anormalidades em dois indivíduos (9,1%).

Conclusão: A ultra-sonografia anorretal tridimensional é um exame simples, econômico, rápido e útil no estudo de doenças anorretais e deve ser incluído no estudo dos pacientes com dor anal para descartar causas orgânicas.

© 2015 Sociedade Brasileira de Coloproctologia. Publicado por Elsevier Editora Ltda.

Todos os direitos reservados.

Introduction

Chronic anal pain can be characterized as an often intense, poorly defined, not-irradiating and, in some cases, lancinating pain with at least three months duration. The prevalence of anorectal pain in American household heads was 6.6%, being more common in women¹ and accounts for 30–40% of visits for anal pain.²

This condition can result from a variety of causes and may be associated with proctologic, gynecological, genitourinary, traumatic, neurological or psychological changes.³ In most patients, a thorough clinical history characterizing the nature of anal pain and defining whether there is or not a relationship with straining, in association with a thorough physical exam, allows the physician to establish the diagnosis. Thus, the exclusion of organic causes of anorectal pain not identified after a thorough proctologic examination is needed. As an example, we can mention: deep perirectal postoperative sepsis,⁴ primary intersphincteric abscess,⁵ hidden sphincter injuries, and other organic diseases of surgical resolution. There are also cases of anorectal pain of functional etiology such as proctalgia fugax, elevator syndrome and unspecified chronic anorectal pain. An accurate diagnosis is needed for proper treatment.

Anorectal ultrasonography is an imaging diagnostic technique indicated in benign and malignant anorectal disorders.⁶ This technique constitutes an important ally in the detection of organic causes of anal pain with no changes in physical examination. More recently, due to the limitation for viewing images in the longitudinal plane, a transducer that allows the three-dimensional reconstruction of images which are two-dimensionally obtained was introduced.⁷

With this type of ultrasound, the physical examination has been enriched with accurate information on anal canal and rectum on several planes, and this technique can demonstrate the size and position of all anatomical structures.

Objective

The aim of this paper is to emphasize the importance of three-dimensional anorectal ultrasonography in patients with chronic anal pain without change in their physical examination.

Methodology

This is a prospective study conducted during the period from June 2009 to June 2011 in 22 patients with chronic anal pain suspected of having a functional diagnosis. The average age was 49 years, with 13 women (59.1%) and nine men (40.9%).

This study comprised patients with chronic anal pain lasting more than three months.¹ The pain was characterized by having duration from 15 s to 20 min and with no relation to straining. In addition, our patients did not require medication to minimize their symptoms and the pain was not disabling for their work.

All patients underwent a full proctologic and colonoscopy examination. On physical examination, no signs were detected and there were no clinical signs of perineal and/or anorectal sepsis, as well as any official disease that could suggest some etiology for the pain. In our study, all patients had a normal colonoscopy. Subsequently a 3D-US was obtained

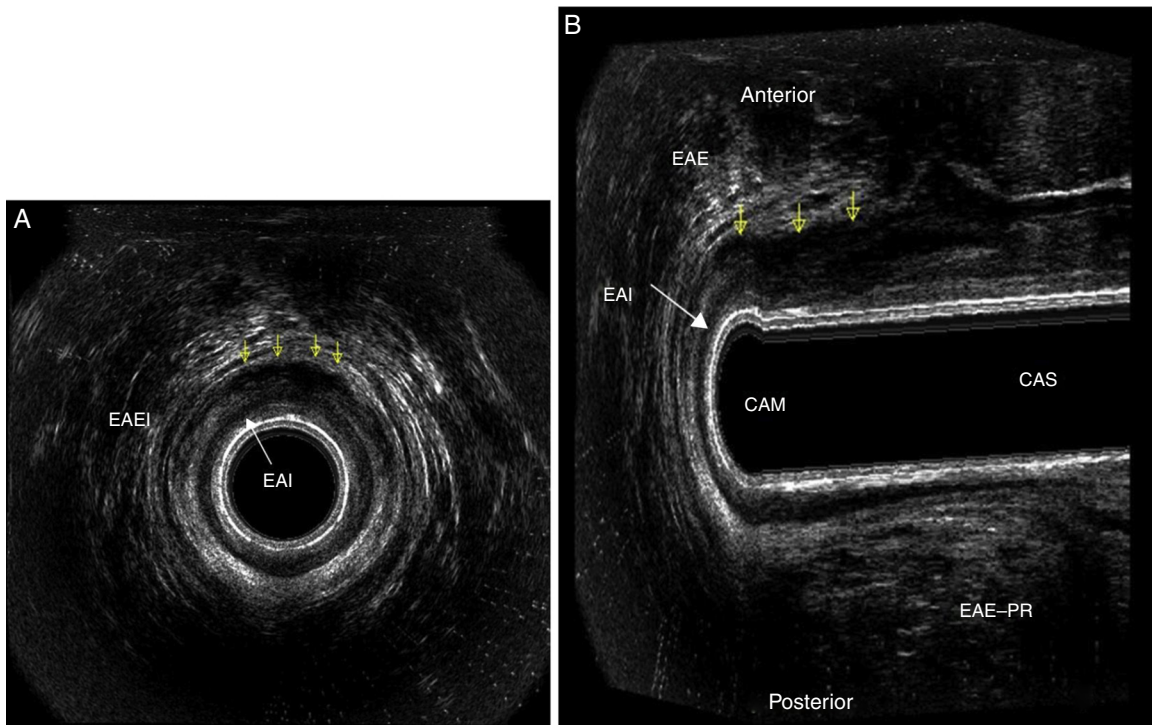


Fig. 1 – Presence of an intersphincteric inflammatory-infectious process (yellow arrows) in the middle anal canal (MAC). EAS, external anal sphincter; IAS, internal anal sphincter (white arrows); A, axial section; B, sagittal longitudinal plane.

from Coloproctological Service, at Gastroclínica de Cascavel Ltda., by a single examiner (DMRL).

The device used was type 2050 BK Medical® ultrasound with a full 360° field probe. After undergoing bowel preparation with a fleet enema 2 h before the test, the patients were examined in the left lateral position. Digital touch was performed and then the transducer was inserted and positioned into the anal canal. The images were acquired by two automatic

scans in men – corresponding to the anal canal and lower rectum, respectively – and three in women – corresponding to the anal canal, lower rectum and dynamic examination.⁸ The anal canal scanning was performed with the transducer at 6 cm from the anal margin; the dynamic examination was performed at 7 cm from the anal margin; and the lower rectum scanning was held at a point 10 cm from the anal margin. The cube-view 3D images were analyzed in the axial, transverse,

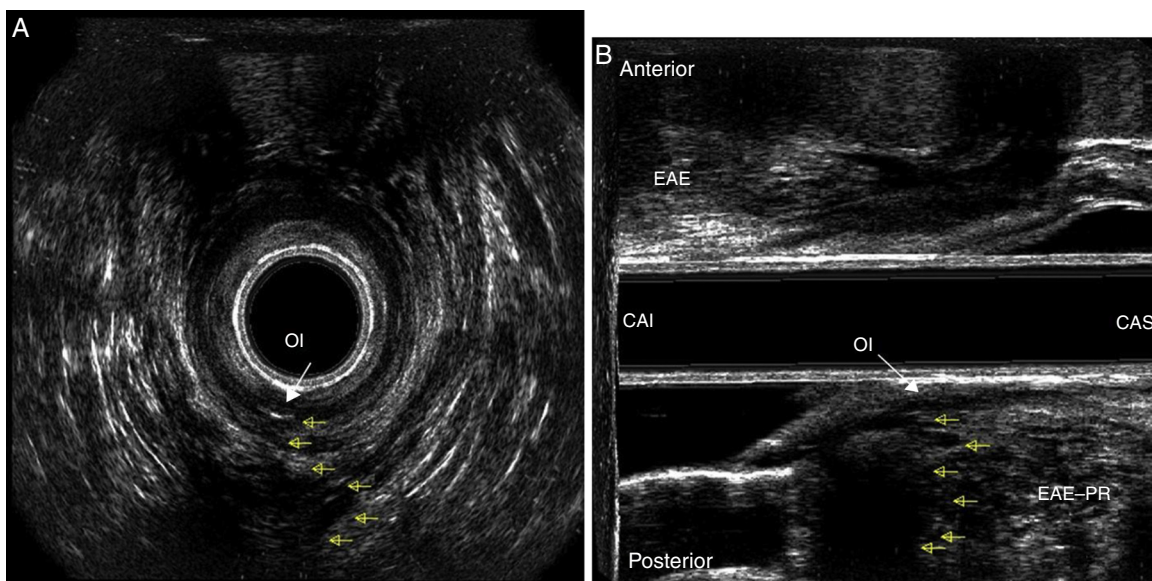


Fig. 2 – Presence of an internal fistulous opening at 6 o'clock position (white arrow) in the middle anal canal, suggesting the presence of an anal fistula (yellow arrows). A, axial section; B, sagittal section; EAS, external anal sphincter; PR, puborectalis.

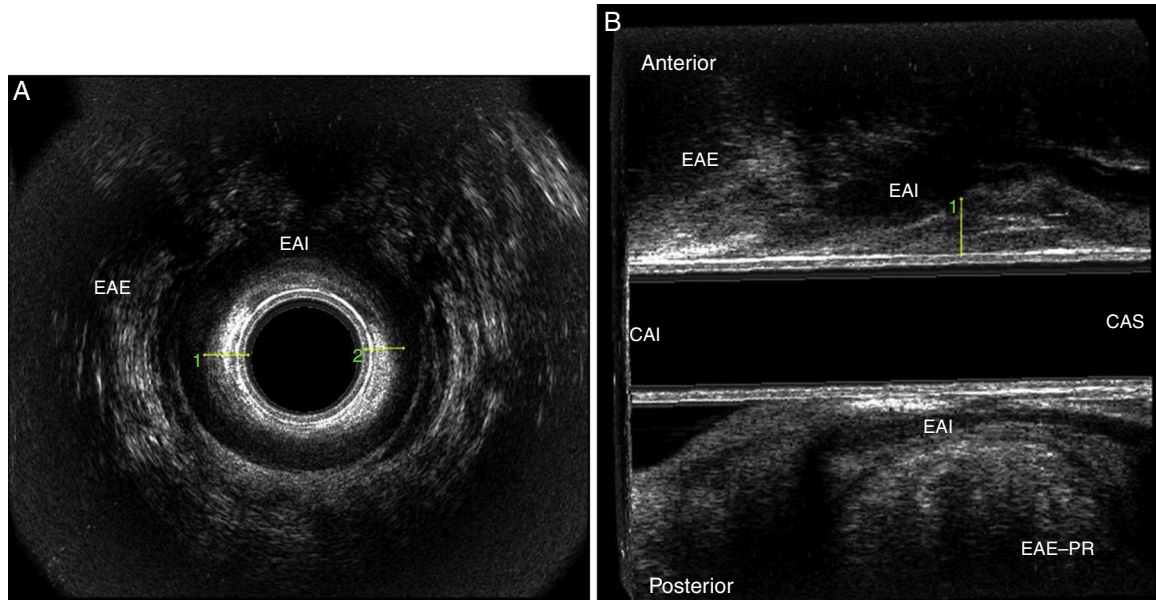


Fig. 3 – Increase in the thickness of the subepithelial tissue (mucosal prolapse) in middle (MAC) and upper (UAC) anal canal. A, axial section in MAC; B, sagittal section.

sagittal and diagonal planes. The sphincter integrity in the anal canal and walls of the rectum and perianorectal tissue was evaluated. The identification of a subepithelial tissue thickening with measurements exceeding 0.3 cm may correspond to a mucous-haemorrhoidal prolapse.⁹ This measure was obtained in the middle and upper parts of the anal canal, at the 9 and 6 o'clock positions.

The sonographic findings indicative of an intersphincteric inflammatory-infectious process were characterized by a hypoechoic, irregular, heterogeneous cavity, often with poor echoes inside, between the external and internal anal sphincters in the middle anal canal, between the internal anal sphincter and the puborectalis muscle in the upper anal canal, and in the ischiorectal fossa in the lower rectum.

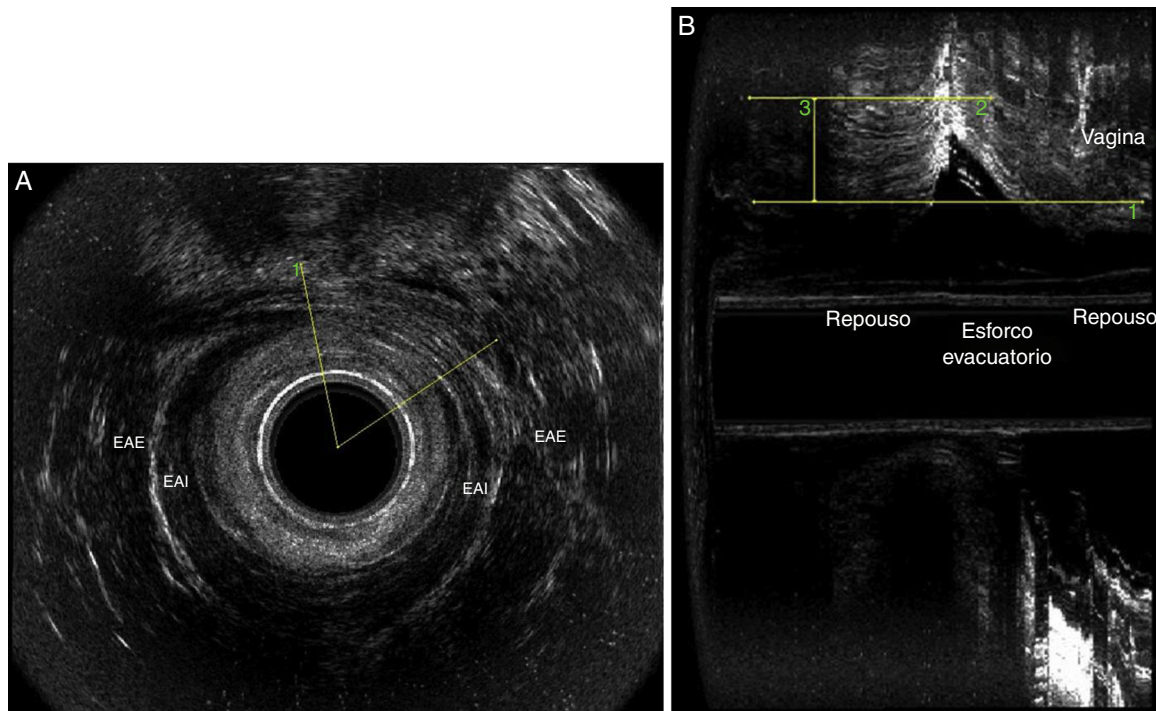


Fig. 4 – Female patient with an internal anal sphincter (IAS) injury and grade II rectocele by dynamic anorectal echodfecography. A, axial section: middle anal canal with an IAS injury angle (EAS: external anal sphincter); B, longitudinal section: partial injury of EAS in the lower anal canal-longitudinal length (1).

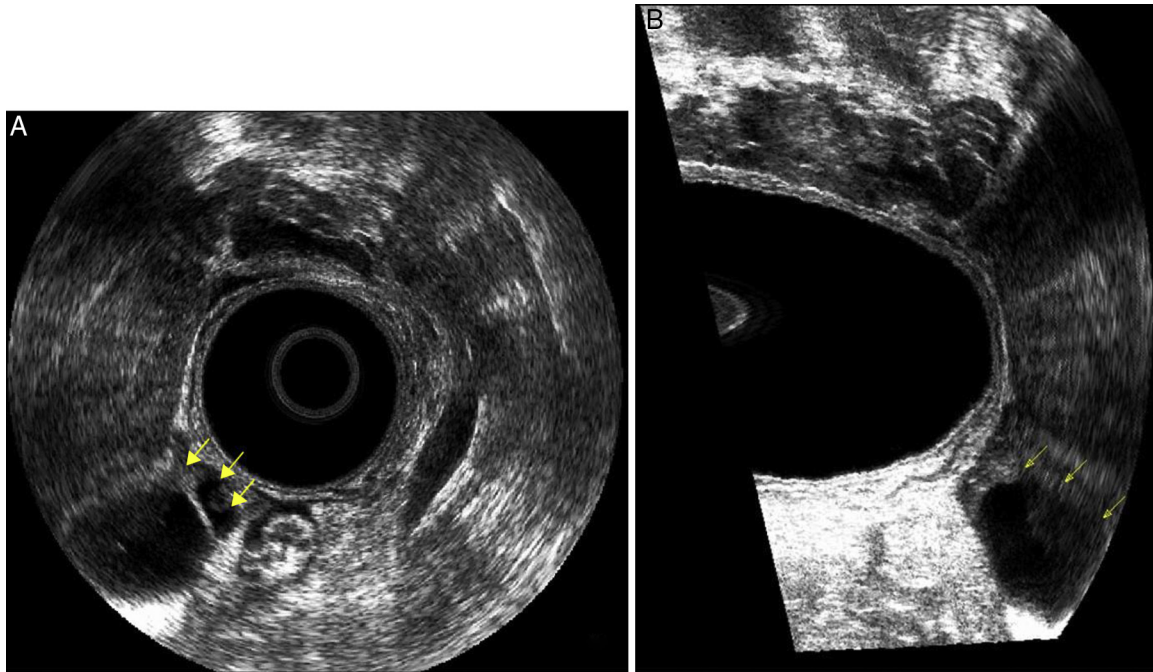


Fig. 5 – Presence of a hypoechoic circular image in middle and lower rectum – retrorectal (presacral) cyst: delimitation of the cyst (arrows). A, axial section; B, sagittal longitudinal plane.

The retrorectal cyst was characterized for being an irregular, hypoechoic, cystic image located posterior to the walls of the middle and lower rectum.¹⁰ The image obtained by dynamic echodefecography was considered as a rectocele when a difference in the posterior vaginal wall position at rest and during straining was noted.⁸ Sphincter injury was characterized as a hypoechoic interruption of muscle fibers of the internal anal sphincter and a hyperechoic interruption of external sphincter.¹¹

The following variables were assessed: age, gender, parity, and previous history of anorectal disease and/or surgery.

Patients with anal pain complaints and with proctologic or colonoscopic findings which would justify the pain, such as hemorrhoids, fissures, fistulae, hypertrophic papillae and inflammatory bowel disease, as well as patients with a history of previous orificial surgery and female patients with changes in gynecological examinations were excluded from the study.

Results

The results indicated an intersphincteric inflammatory-infectious process of the upper anal canal and lower rectum and in the middle anal canal in 14 patients (63.6%) (Fig. 1). In one patient, an internal fistula opening at 6 o'clock position in the middle anal canal was found, suggesting the presence of anal fistula (Fig. 2).

The thickness of the subepithelial tissue was higher than normal, suggesting a haemorrhoidal mucous prolapse in the middle and upper anal canal in three patients (13.6%) The thickness of the subepithelial tissue was higher than normal, suggesting the presence of a haemorrhoidal mucous prolapse in the middle and upper anal canal in three patients (13.6%)

(Fig. 3). Two female patients (9.1%) presented with an anal sphincter injury, one of them being in the internal anal sphincter in the presence of a grade II rectocele, and the other in the external anal sphincter in the distal and anterior parts of the middle anal canal not accompanied by a rectocele (Fig. 4).

In one patient (4.6%), the examination revealed the presence of a hypoechoic circular retrorectal cyst in the middle and lower rectum (Fig. 5). The 3D-US examination revealed no abnormalities in two subjects (9.1%).

Discussion

Ultrasonography has a well-defined role in the evaluation of benign and malignant anorectal diseases, because this procedure demonstrates precisely the anatomical structures that form the anal canal, rectum and peri-anorectal tissues. In this study, anorectal changes were identified in 91.9% of patients and a diagnosis of idiopathic proctalgia was established in 9.1%. In a study published in 2008, the authors identified the causes of pain in 82% of cases.¹² In 2010, another study identified specific organic causes of disease in 49% of cases.¹³

The difficulties in diagnosing intersphincteric sepsis are well documented, thanks to the absence of external clinical signs such as swelling, induration or perianal hyperemia.¹⁴ Thus, an early diagnosis and effective treatment offer better postoperative functional outcomes.¹⁵ In this study, intersphincteric sepsis was diagnosed in 14 patients (63.6%), and the path and internal fistulous orifice were evidenced in a patient.

Beer-Gabel et al.¹⁶ demonstrated that changes such as recto-anal intussusception, rectocele and enterocele may contribute to the perianal pain and to a painful defecation. In

this study, a rectocele was identified in a female patient during the dynamic echodefecography. Another change that was identified in relation to defecation was a subepithelial tissue thickening, suggesting mucous-haemorrhoidal prolapse in 13.6%, and this may be the cause of anal pain. In two female patients, the presence of an anal sphincter injury was evidenced.

Other causes of anal pain that should be considered, despite its low incidence, are perianal endometriosis and perineal or retrorectal tumors. In one patient, the presence of a retrorectal cyst of the middle and lower rectum was evidenced.

Most of the time, anal pain does not mean a lesion of malignant nature, however, it decreases the patient's quality of life if not diagnosed and without proper treatment. Ultrasound helps to demonstrate the whole anatomy of the anal canal, allowing a clear understanding of possible causes of anal pain, hence the usefulness of the test. Thus, functional causes are removed from anatomical causes, allowing the establishment of a specific therapy for each case.

Conclusion

The three-dimensional anorectal ultrasound is a simple, cost-effective, fast and useful method in the study of anorectal diseases and should be included in the study of patients with anal pain, with the aim to rule out organic causes.

Conflicts of interest

The authors declare no conflicts of interest.

REFERENCES

- Bharucha AE, Wald A, Enck P, Rao S. Functional anorectal disorders. *Gastroenterology*. 2006;130:1510-8.
- Swash M. Chronic perianal pain. In: Henry M, Swash M, editors. *Coloproctology and the pelvic floor*. London: Butterworths; 1985. p. 388-92.
- Cheung O, Wald A. Management of pelvic floor disorders. *Aliment Pharmacol Ther*. 2004;19:481-95 [Review].
- Abbasakoor F, Nelson M, Beynon J, Patel B, Carr ND. Anal endography in patients with anorectal symptoms after haemorrhoidectomy. *Br J Surg*. 1998;85:1522-4.
- Millan M, García-Granero E, Esclápez P, Flor-Lorente B, Espí A, Lledó S, et al. Management of intersphincteric abscesses. *Colorectal Dis*. 2006;8:777-80.
- Tarantino D, Bernstein MA. Endoanal ultrasound in the staging and management of squamous-cell carcinoma of the anal canal: potential implications of a new ultrasound staging system. *Dis Colon Rectum*. 2002;45:16-22.
- Kim JC, Cho YK, Kim SY, Park SK, Lee MG. Comparative study of three-dimensional and conventional endorectal ultrasonography used in rectal cancer staging. *Surg Endosc*. 2002;16:1280-5.
- Murad-Regadas SM, Regadas FSP, Rodrigues LV, Escalante RD, Silva FRS, Lima DMR, et al. Ecodéfecografía tridimensional dinámica. Nova técnica para avaliação da síndrome da defecação obstruída (SDO). *Rev Bras Coloproct*. 2006;26:168-77.
- Murad-Regadas SM, Regadas FSP. Ultra-sonografía anorretal bi e tridimensional. In: Murad-Regadas SM, Regadas FSP, editors. *Distúrbios Funcionais do Assoalho Pélvico - Atlas de Ultra-sonografía Anorretal Bi e Tridimensional*. Rio de Janeiro: Revinter; 2006. p. 51-78.
- Murad-Regadas SM, Regadas FSP. Miscelâneas. In: Murad-Regadas SM, Regadas FSP, editors. *Distúrbios funcionais do assoalho pélvico - Atlas de Ultra-sonografía Anorretal Bi e Tridimensional*. Rio de Janeiro: Revinter; 2006. p. 342-62.
- Santoro GA, Di Falco G. Basic anatomy. In: Santoro GA, Di Falco G, editors. *Atlas of endoanal and endorectal ultrasonography*. Milán: Springer; 2004. p. 25-42.
- Pascual I, García-Olmo D, Martínez-Puente C, Pascual-Montero JA. Ultrasound findings in spontaneous and postoperative anal pain. *Rev Esp Enferm Dig*. 2008;100:764-7.
- Vieira AM, Castro-Poças F, Lago P, Pimentel R, Pinto R, Saraiva MM, et al. The importance of ultrasound findings in the study of anal pain. *Ultrasound findings in the study of anal pain*. *Rev Esp Enferm Dig*. 2010;102:308-13.
- Onaca N, Hirshberg A, Adar R. Early reoperation for perirectal abscess - a preventable complication. *Dis Colon Rectum*. 2001;44:1469-73.
- García-Aguilar J, Belmonte C, Wong WD, Goldberg SM, Madoff RD. Anal fistula surgery. Factors associated with recurrence and incontinence. *Dis Colon Rectum*. 1996;39:723-9.
- Beer-Gabel M, Teshler M, Schechtman E, Zbar AP. Dynamic transperineal ultrasound vs. defecography in patients with evacuatory difficulty. *Int J Colorectal Dis*. 2004;19:60-7.