



# Journal of Coloproctology

www.jcol.org.br



## Case Report

# Appendicitis caused by ingestion of metal foreign body



José Inácio de Almeida Neto<sup>a,\*</sup>, Bruna Schawn Guerini<sup>b</sup>,  
Felipe Fernandes Nogueira de Almeida<sup>b</sup>

<sup>a</sup> General Surgery Service, Hospital de Clínicas Dr. Radamés Nardini, Mauá, SP, Brazil

<sup>b</sup> Hospital de Clínicas Dr. Radamés Nardini, Mauá, SP, Brazil

### ARTICLE INFO

#### Article history:

Received 13 December 2013

Accepted 11 August 2014

Available online 28 January 2015

#### Keywords:

Appendicitis

Foreign-body migration

Appendix

Laparotomy

### ABSTRACT

**Introduction:** The ingestion of foreign bodies is a frequent occurrence, especially among children. The majority of these objects travel safely through the gastrointestinal tract, without causing symptoms or leaving sequelae. Acute appendicitis is the emergency surgical pathology of greater prevalence. However, the impaction of a foreign body into the appendicular lumen as an etiologic agent of appendicitis is a very rare event.

**Case report:** We describe the case of a 21-year-old male patient with lower abdominal pain over approximately six days, in association with vomiting, fever and abdominal distension. After imaging studies, a radiopaque foreign body was identified in a pelvic topography, with distention and air-fluid levels in intestinal loops. Our patient was submitted to an open appendectomy, evidencing acute perforated appendicitis and the presence of two foreign bodies in its lumen. The patient progressed satisfactorily in the post-operative period, with use of broad-spectrum antibiotics.

**Discussion:** Foreign bodies impacted in the gastrointestinal tract are usually removed by endoscopic techniques. When these bodies cause infections, there should be a resolution, preferably by surgical laparoscopy, which will serve both for diagnostic as therapeutic purposes.

© 2015 Sociedade Brasileira de Coloproctologia. Published by Elsevier Editora Ltda. All rights reserved.

#### Palavras-chave:

Apêndice

Corpo estranho, migração

Apêndice

Laparotomia

## Apêndice provocada por ingestão de corpos estranhos metálicos

### RESUMO

**Introdução:** A ingestão de corpos estranhos é um acontecimento frequente, principalmente entre crianças. A maioria destes passa de forma inócua pelo trato gastrointestinal, sem causar sintomas ou deixar sequelas. Apêndice aguda é a patologia cirúrgica emergencial de maior prevalência.

\* Corresponding author.

E-mail: [jialmeidacirplast@gmail.com](mailto:jialmeidacirplast@gmail.com) (J.I. de Almeida Neto).

<http://dx.doi.org/10.1016/j.jcol.2014.08.014>

2237-9363/© 2015 Sociedade Brasileira de Coloproctologia. Published by Elsevier Editora Ltda. All rights reserved.

**Contudo:** a impactação de um corpo estranho no lúmen apendicular como agente etiológico de apendicite é um evento muito raro.

**Relato de caso:** Descrevemos o caso de um paciente masculino de 21 anos com quadro de dor abdominal baixa há aproximadamente 6 dias, associando-se a vômitos, febre e distensão abdominal. Após exames de imagem, identificou-se corpo estranho radiopaco em topografia pélvica, distensão e níveis hidroaéreos em alças intestinais. Foi submetido a apendicectomia laparotômica, evidenciando-se apendicite aguda perforada e presença de dois corpos estranhos em seu lúmen. Evoluiu de forma satisfatória no pós-operatório, tendo-se feito uso de antibióticos de largo espectro.

**Discussão:** Corpos estranhos impactados no trato gastrointestinal são usualmente retirados por técnicas endoscópicas. Quando provocam quadros infecciosos, deve-se proceder a uma resolução cirúrgica, preferencialmente por videolaparoscopia, a qual servirá tanto para fins diagnósticos quanto terapêuticos.

© 2015 Sociedade Brasileira de Coloproctologia. Publicado por Elsevier Editora Ltda. Todos os direitos reservados.

## Introduction

Appendectomy is the most common emergency surgical procedure worldwide.<sup>1</sup> However, these procedures remove up to 28.7% of normal appendices, even with the evolution of diagnostic methods. This percentage is even higher in young women.<sup>1,2</sup>

The ingestion of inedible and indigestible objects is very common, especially in younger age groups. In adults, this occurs accidentally, or in patients with mental retardation.<sup>3</sup>

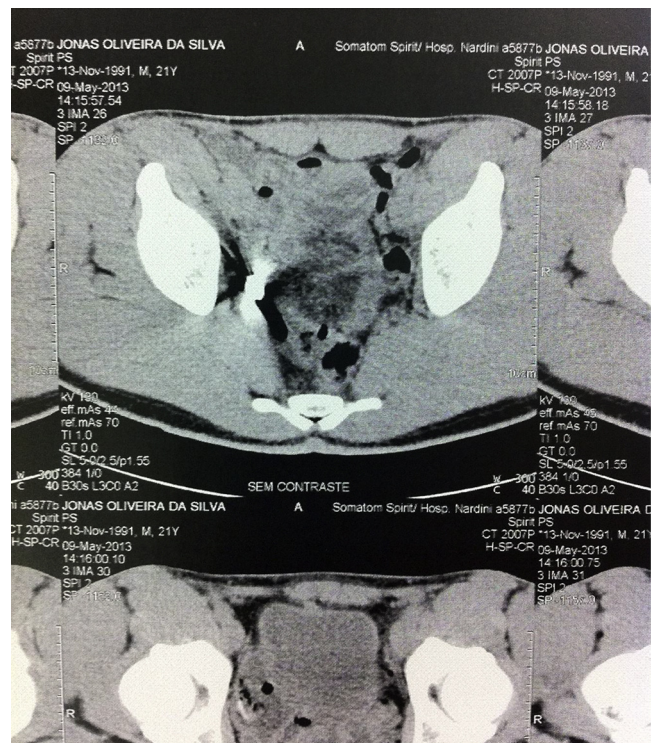
The presence of a foreign body in the appendix, acting as a cause of an inflammatory process, is a very rare event.<sup>4</sup>

We describe a case of acute appendicitis caused by ingestion of a metal object, which impacted into the appendiceal lumen, comparing the conduct taken with a review of the existing literature on the subject.

## Case report

A male patient, 21 years old, was admitted to the general surgery emergency department with a 24-h non-irradiating abdominal pain on the right iliac fossa (RIF), without aggravating or mitigating factors, and associated with vomiting episodes. The patient had no other complaints related to the gastrointestinal tract and with no history of comorbidities, surgery or allergies. The physical examination revealed pain on palpation of RIF, but without signs of peritoneal irritation; air-fluid sounds present, with no palpable masses. The patient had mild leukocytosis (12,600 leukocytes), without presence of rods. An abdominal ultrasound was performed, which identified two metallic foreign bodies located in the pelvis or right iliac fossa.

A CT scan of the pelvis confirmed the presence of radiopaque bodies; we could not determine whether they were located in the interior of the gastrointestinal tract or in the abdominal cavity (Fig. 1). The patient had his pain symptoms improved, with normal bowel movements during the first 48 h after admission, when fled the hospital after 72 h.

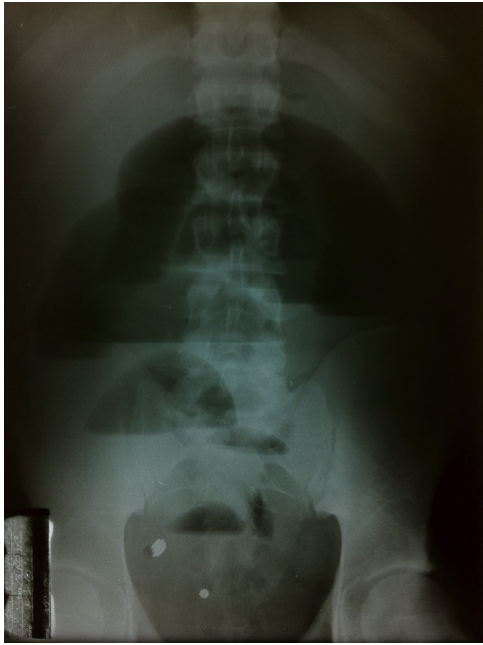


**Fig. 1 – Computed tomography.**

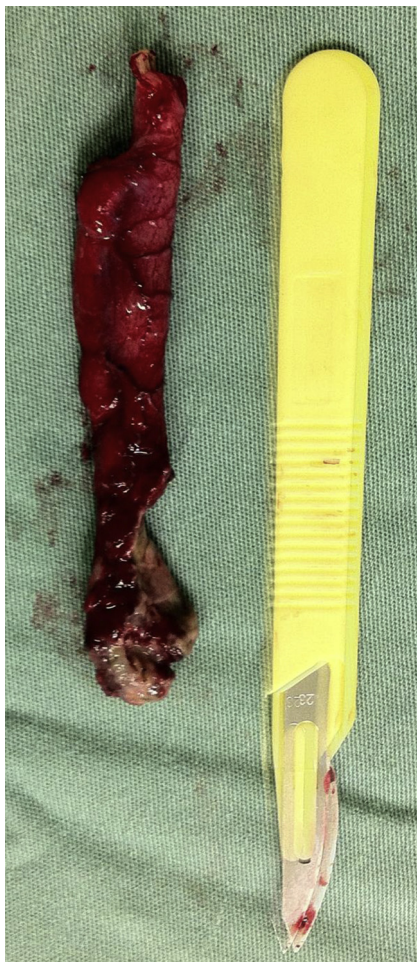The patient returned with worsening of pain symptoms after 48 h of evasion, now with the addition of bowel bloating and multiple emetic episodes, with peritoneal irritation on physical examination. A new radiography revealed again the pelvic foreign bodies, plus air-fluid levels in small intestine topography (Fig. 2).

Surgery was indicated and performed by an exploratory laparotomy, when an acute appendicitis was identified, with necrosis and perforation of the vermiform appendix and presence of two metal bodies into its lumen (Figs. 3 and 4); Thus, a conventional appendectomy was performed.

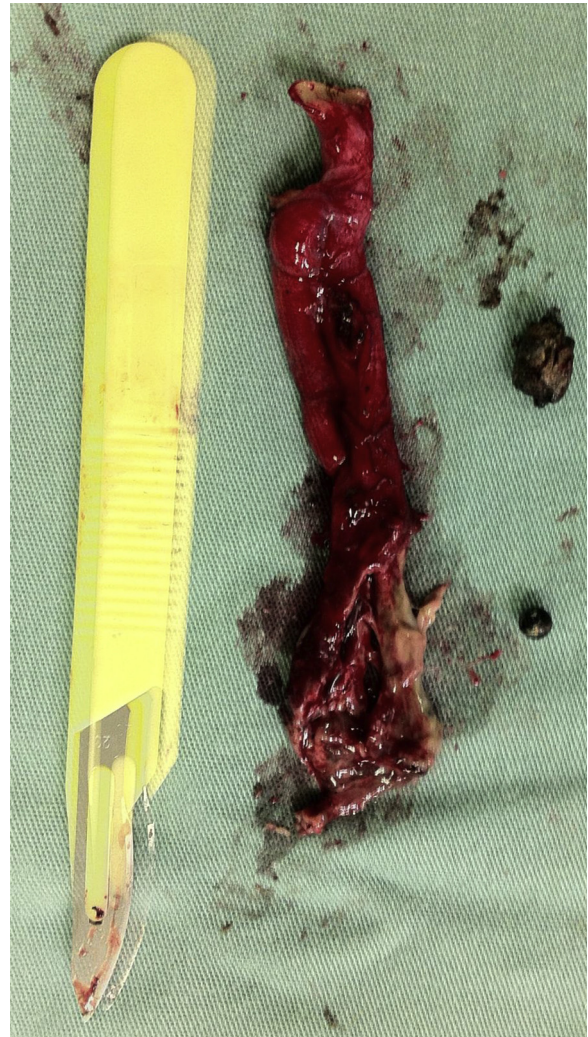The patient recovered uneventfully in the postoperative period, being treated with broad-spectrum antibiotics, and



**Fig. 2 – Radiography of the abdomen.**



**Fig. 3 – Vermiform appendix.**



**Fig. 4 – Appendix and foreign bodies.**

was discharged on the 5th postoperative day, with acceptance of a general diet and with normal bowel habits.

### Discussion

The ingestion of foreign bodies is a common phenomenon in clinical practice, especially among children and in adults with mental retardation;<sup>2</sup> in most cases, these are fragments of fish or poultry bone, dental prostheses or lead fragments (present in slaughtered poultry products). In general, their passage through the gastrointestinal tract is asymptomatic,<sup>5</sup> and the presence of complications such as intestinal perforation, abscess or bowel obstruction being a rare event.<sup>3,6</sup> The impaction of foreign bodies into the appendix is an exceptional event; acute appendicitis caused by a foreign body has a prevalence of 0.0005%,<sup>2,5</sup> and the latency time between the ingestion of the foreign body and the onset of symptoms could be measured in years.<sup>7</sup> In our case, the patient does not remember having taken any metal objects, while admitting the habit of putting them in the mouth. Generally, these are blunt objects, acting as appendicoliths.

There is still controversy about the action to be taken after the ingestion of an asymptomatic foreign body. Klinger et al. propose the endoscopic removal of all foreign bodies by upper gastrointestinal endoscopy; if this procedure is not available, the case should be accompanied with serial radiographs and leucograms.<sup>8</sup>

Colonoscopy should be used to remove stationary objects in the lower right quadrant of the abdomen for a period of at least 72 h, even if these objects are asymptomatic.<sup>8,9</sup>

In fact, thin and pointed impacted objects show a greater propensity to cause symptoms, around 93% of cases; abscesses (88%) or intestinal perforation (70%) are the most common findings. On the other hand, blunt objects may be asymptomatic for long periods, and an incidence of up to 66% of appendicitis in the case of impaction of such objects was reported.<sup>3</sup>

If the endoscopic removal failed, a fluoroscopy-guided laparoscopy to remove these foreign bodies is indicated.<sup>2</sup>

The positioning of the appendix in a more caudal location than the usual may be due to the weight caused by the presence of both foreign bodies into the lumen; in a way, this complicates the exact location of these objects.

In the case in study, the endoscopic procedure was not attempted, since there was a surgical indication due to the inflammation caused by the foreign bodies. Failure to use a laparoscopic procedure was due to the unavailability of this procedure in the period when the patient was seen.

---

### Conflicts of interest

The authors declare no conflicts of interest.

### REFERENCES

---

1. Chandrasegaram MD, Rothwell LA, An EI, Miller RJ. Pathologies of the appendix: a 10-year review of 4670 appendectomy specimens. *ANZ J Surg.* 2012;82:844-7.
2. Klinger PJ, Seelig MH, DeVault KR, Wetscher GJ, Floch NR, Branton SA, et al. Ingested foreign bodies within the appendix: a 100-year review of the literature. *Dig Dis.* 1998;16:308-14.
3. Benizri EI, Cohen C, Bereder JM, Rahili A, Benchimol D. Swallowing a safety pin: report of a case. *World J Gastrointest Surg.* 2012;4:20-2.
4. Baek SK, Bae OS, Hwang I. Perforated appendicitis caused by foreign body ingestion. *Surg Laparosc Endosc Percutan Tech.* 2012;22:e94-7.
5. Sar S, Mahawar KK, Marsh R, Small PK. Recurrent appendicitis following successful conservative management of an appendicular mass in association with a foreign body: a case report. *Cases J.* 2009;2:7776.
6. Pilichos C, Tasiias G, Pyleris E, Anyfantis N, Pantelarios N, Barbatzas C. Endoscopic extraction of a metal key impacted within the appendix. *World J Gastrointest Endosc.* 2010;2:372-4.
7. Selfa Munoz A, Palacios Perez A, Martinez Tirado P, Barrientos Delgado A. An unusual cause of acute appendicitis. *Med Clin.* 2012;138:e15.
8. Sarkar RR, Bisht J, Sinha Roy SK. Ingested metallic foreign body lodged in the appendix. *J Indian Assoc Pediatr Surg.* 2011;16:29-30.
9. Schwab D, Baum U, Hahn EG. Colonoscopic treatment of obstructive appendicitis caused by dislocation of a biliary stent. *Endoscopy.* 2005;37:606.