



Journal of Coloproctology

www.jcol.org.br



Case Report

Diagnostic difficulty in Peutz–Jeghers syndrome[☆]



Jenifer Loureiro^a, Gian Luigi Menegazzo^a, Lucas Vergamini^a,
Roberto Carmagnani Pestana^a, Fernanda Bellotti Formiga^{b,*},
Marcella Guilherme Carolino de Sousa^b, Thais Yuka Takahashi^b, Felipe Silveira^c,
Paulo de Azeredo Passos Candelária^b, Dino Martini Filho^d, Fang Chia Bin^b

^a Faculdade de Ciências Médicas da Santa Casa de São Paulo, São Paulo, SP, Brazil

^b Department of Surgery, Irmandade da Santa Casa de Misericórdia de São Paulo, São Paulo, SP, Brazil

^c Irmandade da Santa Casa de Misericórdia de São Paulo, São Paulo, SP, Brazil

^d Department of Pathology, Irmandade da Santa Casa de Misericórdia de São Paulo, São Paulo, SP, Brazil

ARTICLE INFO

Article history:

Received 19 November 2013

Accepted 11 August 2014

Available online 29 January 2015

Keywords:

Peutz–Jeghers syndrome

Intestinal polyps

Diagnosis

ABSTRACT

A case of diagnostic difficulty facing the patient with colonic polyposis secondary to Peutz–Jeghers syndrome, but without family history and pathognomonic clinical features of the disease, is illustrated. The exams, including biopsy, led to diagnostic uncertainty and the definitive diagnosis was characterized in therapeutic of exception.

© 2014 Sociedade Brasileira de Coloproctologia. Published by Elsevier Editora Ltda. All rights reserved.

Dificuldade diagnóstica na Síndrome de Peutz-Jeghers

RESUMO

Ilustra-se um caso de dificuldade diagnóstica frente à paciente com polipose colônica secundária a Síndrome de Peutz-Jeghers, sem história familiar e sem características clínicas patognomônicas da doença. Os exames, incluindo biópsia, geraram dúvida diagnóstica, sendo o diagnóstico definitivo caracterizado em terapêutica de exceção.

© 2014 Sociedade Brasileira de Coloproctologia. Publicado por Elsevier Editora Ltda. Todos os direitos reservados.

Palavras-chave:

Síndrome de Peutz-Jeghers

Pólipos intestinais

Diagnóstico

[☆] Study conducted at Faculdade de Ciências Médicas da Santa Casa de São Paulo (FCMSCSP) and Department of Surgery and Pathology, Irmandade da Santa Casa de Misericórdia de São Paulo, São Paulo, Brazil.

* Corresponding author.

E-mail: dc@santacasasp.org.br (F.B. Formiga).

<http://dx.doi.org/10.1016/j.jcol.2014.08.012>

2237-9363/© 2014 Sociedade Brasileira de Coloproctologia. Published by Elsevier Editora Ltda. All rights reserved.

Introduction

Peutz-Jeghers syndrome (PJS) is an autosomal dominant disorder characterized by multiple hamartomatous polyps in the gastrointestinal tract, generally associated with mucocutaneous hyperpigmentation.^{1,2} This is a rare condition, with prevalence between 1:8300 and 1:280,000.²

Patients with PJS are predisposed to the development of benign and malignant neoplasms of the gastrointestinal tract, breast, ovary, uterus, cervix and testis.^{2,3}

In the spectrum of colonic polyposis, histology is decisive to establish the etiologic diagnosis and define the therapeutic conduct. Thus, the motivation of this work is to present a case of Peutz-Jeghers syndrome in which there was diagnostic difficulty.

Case report

Man, 44, previously healthy, began hematochezia that evolved into an intermittent minor enterorrhagia a year ago. Denied change in bowel habits, abdominal or anal pain, adynamia or weight loss. Also denied family history of intestinal disease, but the patient did not keep in touch with family members.

On examination, the patient was ruddy and in good general condition, the abdominal examination was normal and no mucocutaneous changes were observed. The digital rectal examination revealed polyps located approximately 5 cm from the anal margin, especially on the posterior wall, with no bleeding.

The colonoscopy revealed multiple polyps (approximately 50) throughout the colon, reaching distal rectum. The biggest polyps in the right colon were about 3 cm in size. The rectum contained approximately 14 polyps (Fig. 1). The chromoendoscopy with magnification revealed type II, III and IV crypts, according to Kudo⁴ classification. Incisional biopsies were performed in three separate polyps that were histologically characterized as hyperplastic polyps (Fig. 2).

Triple-contrast computerized tomography (CT) of the abdomen and pelvis revealed only a 5-cm polyp in the right colon.

Our patient underwent total colectomy with video-assisted ileo-rectal anastomosis, without complications and with good postoperative evolution.

Macroscopically, 62 polypoid injuries were observed, some of them pedunculated, measuring from 3 mm to 6 cm (Fig. 3). The microscopic exam revealed hamartomatous polyps compatible with Peutz-Jeghers syndrome, seen in both hematoxylin-eosin and in Masson's trichrome (Fig. 2).

Currently, the patient evacuates soft feces five times a day and shows no fecal incontinence. There is an ongoing investigation of the rest of the gastrointestinal tract, in search of polyps and cancers associated with the syndrome.

Discussion

Peutz-Jeghers syndrome (PJS) is characterized clinically by the presence of multiple hamartomatous polyps in the

gastrointestinal tract, associated, in most cases, with mucocutaneous hyperpigmentation.^{1,2} This syndrome was originally described in a Dutch family (Harrisburg) by Peutz in 1921.^{2,5} After 28 years, the clinical presentation of the syndrome was described by Jeghers.^{1,3}

This is a rare autosomal dominant disease with high penetrance.² The defect identified in patients with PJS is a mutation in the gene LKB1/STK11, encoding a serine-threonine kinase and located in the region 13³ of the short arm of chromosome 19.³ This gene regulates apoptosis, thus the loss of its function is related to an unregulated cell proliferation.^{6,7}

It is believed that a great genetic heterogeneity occurs among patients with PJS.⁸ One study evaluated 33 patients with PJS and showed that only 52% of them had a mutation in the LKB1/STK11 gene, suggesting that about half of the cases are not caused by mutation in this gene.⁸

Malignant degeneration of these injuries occurs only rarely.² The patient described in this paper had no such hyperpigmentation and was unaware of such manifestation during childhood.

In association with hyperpigmentation, the presence of multiple hamartomatous polyps in the gastrointestinal tract is mandatory; these polyps are characterized by a single central bundle of smooth muscle fibers from muscularis mucosa, with branches in a tree-shaped form and covered by normal mucosa of the area.^{1,2,7}

In a study of 202 patients, 52 of them had their diagnosis based on skin lesions, while in 150 others the diagnosis was based on intestinal polyps.⁵

Approximately 25% of patients have no family history, as was the case with our patient. In the absence of mucocutaneous manifestations and of a family history, the diagnostic confusion in the described case occurred because the colonoscopy study suggested hyperplastic (type II crypts) and adenomatous (crypts III and IV) polyps, with a biopsy showing hyperplastic features.

Histologically, hyperplastic features may be present on the surface of any polyp, as shown in Fig. 2. Thus, to believe that the endoscopic appearance, chromoendoscopy and incisional biopsies will be sufficient for the diagnosis could, actually, hinder its establishment.

The resulting information on the diagnostic method used led the medical staff to think in a surgical treatment, supposing a mixed hereditary polyposis with an associated adenomatous component, besides the possibility of hyperplastic polyposis.

In the cited polyposes, colectomy is an option widely regarded, because of a greater chance of polyp malignization. Mixed adenomatous polyposes with an adenomatous component must necessarily be treated by resective surgery,³ and hyperplastic polyposes can be treated both with a short-term follow-up and with a prophylactic colectomy, since their carcinogenesis is fast and can surprise interval tumors.^{3,9}

Thus, total colectomy with ileum-rectum anastomosis in the present case caused surprise with a definitive diagnosis of hamartomatous polypomatosis of Peutz-Jegher, because with the surgical specimen it was possible to complete the assessment of polyps.

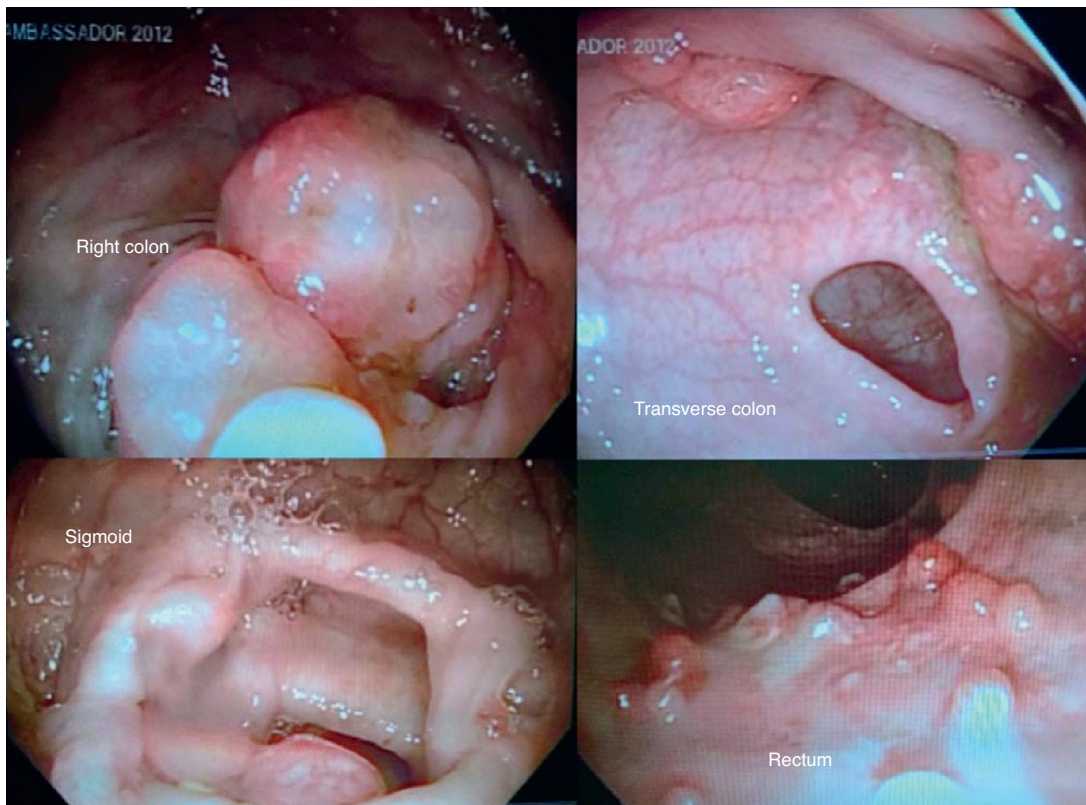


Fig. 1 – Colonoscopy with more than 50 polyps scattered throughout the colon and rectum.

In 1987, Giardiello proposed, for the first time, criteria for establishing the diagnosis of PJS. This author put in place three points: family history consistent with autosomal dominant inheritance, mucocutaneous hyperpigmentation and small intestine polyposis.¹⁰

Currently, the diagnosis of PJS is established by the presence of three or more hamartomatous polyps already characterized and histologically confirmed, or any number of polyps in association with family history, or mucocutaneous hyperpigmentation in association with family history, or even any number of polyps associated with a mucocutaneous manifestation.³ Thus, the diagnosis of PJS may be characterized for the patient described, which alone had 62 hamartomatous colonic polyps.

Even with the possibility of carrying out genetic tests to identify the *LBK1/STK11* gene, negative results do not exclude the diagnosis, because not all of the genetic mechanisms involved in this syndrome were discovered till now.⁸

Hamartomatous gastrointestinal polyps are predominant in the small intestine.² A series of cases showed the following frequency of polyps: 64% in the small intestine, 53% in the colon, 49% in the stomach, and 32% in the rectum.⁶ It is important to underscore that, initially, this growth has not malignant potential, because hamartomas are composed of elements of the gastrointestinal tract itself, but with its architecture distorted.¹¹ It is impossible to differentiate endoscopically a characteristic hamartomatous polyp in a case of SPJ from other polyps, requiring a microscopic study.¹²

The polyps grow in the first decade of life, and most patients become symptomatic between 10–30 years of age. In a series of cases, the most common gastrointestinal symptoms were: obstruction caused by intussusception, or luminal occlusion by polyps (43%), abdominal pain (23%), acute or chronic rectal bleeding (14%) and polyp extrusion through rectum (7%).⁶ In up to 69% of patients intussusception will occur during their life, and this problem is more common in the small intestine.

Given the importance of the small intestine in the characterization of the disease, our patient will be submitted, in addition to the CT study already held, to an upper digestive endoscopy and a study with an endoscopy capsule in search of small polyps that were not identified in the previous laparoscopic surgery.

Peutz-Jeghers syndrome is associated with an increased risk of gastrointestinal and non-gastrointestinal malignancies.² A meta-analysis involving six studies and 210 patients showed a cumulative risk of 93% from 15 to 64 years for all types of malignancies. Thus, the relative risk of an individual with SPJ to present neoplasia in any region, compared with the general population, is up to 15 times higher.¹³

The most frequent neoplasm in patients with PJS is the colonic tumor (57%), followed by breast (45%), pancreas (36%), stomach (29%), ovary (21%), small intestine (13%) and uterus (10%) tumors.³

Risks such as these justify the search, from childhood, for small and large intestine polyps, with polypectomy for polyps

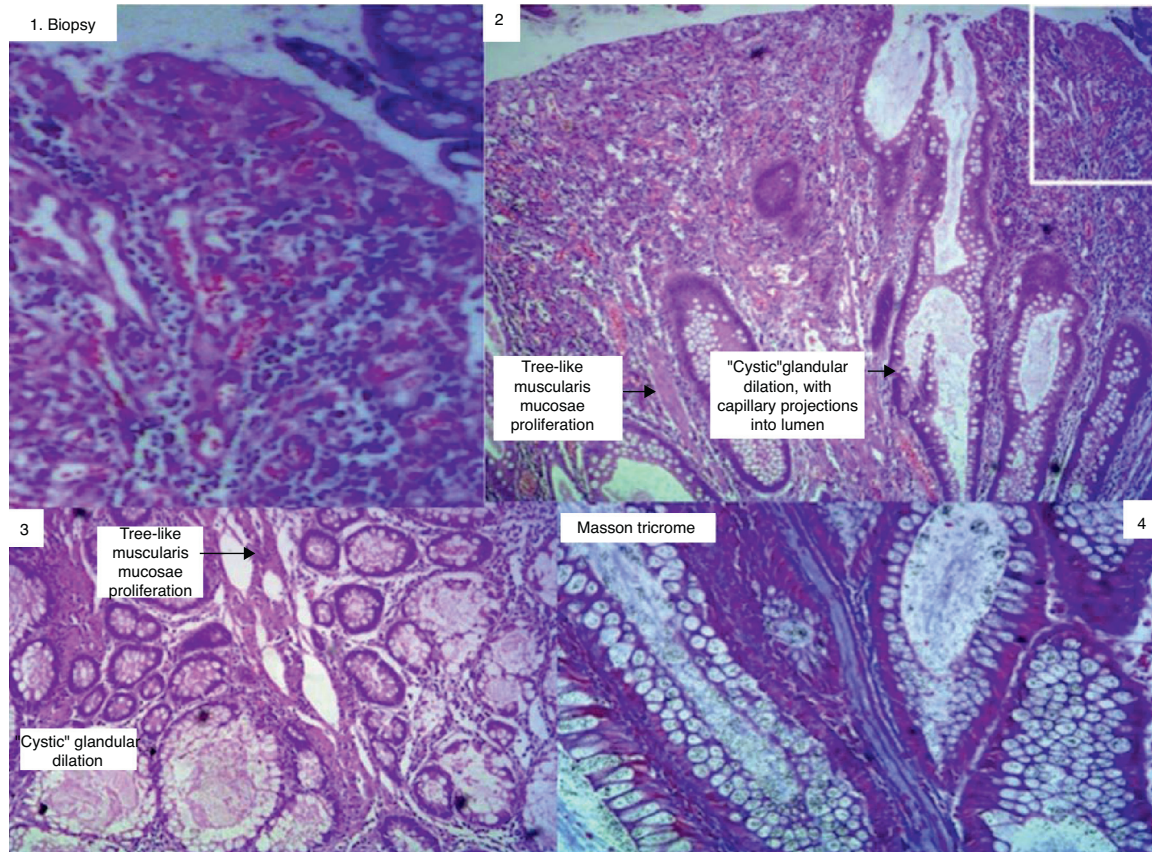


Fig. 2 – Histological study: biopsy of polyp with hyperplastic aspect (1). Hamartomatous polyp (2 and 3). The white square represents the hyperplastic component in a hamartomatous polyp. Masson trichrome staining showing muscle fiber bundle (4).

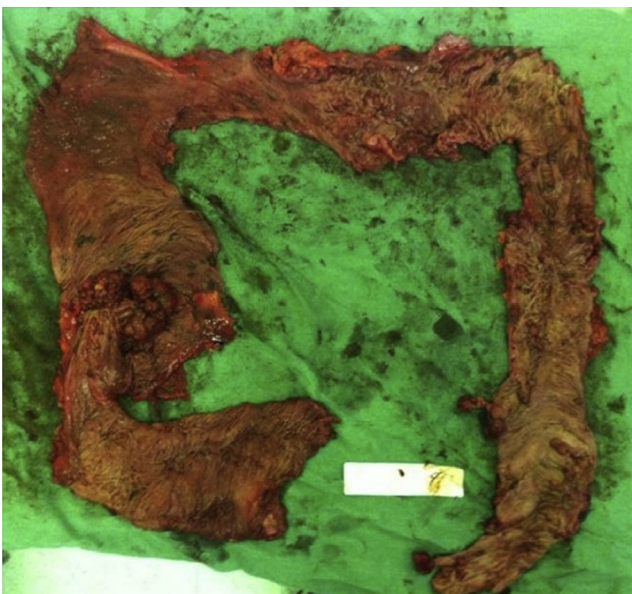

Fig. 3 – Product of a total colectomy: 62 hamartomatous polyps.

greater than 5 mm.^{14,15} The use of capsule endoscopy is considered as a good method for searching the small intestine.¹⁶ Another less expensive but less sensitive option is the CT scan with oral contrast.¹⁷ The double-balloon enteroscopy is a great option, when therapeutically associated; but this procedure is too invasive for control or scanning procedures.²

In addition, a search for other cancers is deemed necessary, although there is still no established consensus concerning the periodicity and on what tests should be ordered. Colonoscopy, endoscopy, CT scan, MRI or pancreatic ultrasound, chest X-ray, mammography and pelvic ultrasound in women, testicular examination in men, and CA-19-9 and CA-125 dosing are recommended.^{3,8,13,18,19}

In an uncomplicated disease, the recommendation is serial polypectomy, double-balloon enteroscopy, or colonoscopy. You can also make use of intraoperative enteroscopy, but with the technological advancements this method is becoming less and less suitable.² In cases in which the disease is complicated with invagination, a partial bowel resection, or enterotomy with polypectomy, will be needed.

If the patient studied was diagnosed with SPJ before surgery, colectomy could have been more economical (segmental colectomy for removal of the 6-cm right colon polyp and cleaning of polyps with an intraoperative endoscopy).

There is evidence that the removal of polyps prevents emergency laparotomy and progression to neoplasia, and also increases the time free of surgery.^{2,20}

We still do not have a pharmacological treatment. Studies suggest the role of chemoprophylaxis with use of rapamycin or of a non-steroidal anti-inflammatory drug (because of the strong activity of COX-2 in polyps).¹⁰

Final considerations

Non-adenomatous colonic polypoid syndromes are not rare and are difficult to diagnose. Representative polypectomies are required for diagnosis and therapeutic management.

Conflicts of interest

The authors declare no conflicts of interest.

REFERENCES

- Jeghers H, McKusick VA, Katz KH. Generalized intestinal polyposis and melanin spots of the oral mucosa, lips and digits: a syndrome of diagnostic significance. *N Engl J Med*. 1949;241:1031.
- Kopacova M, Tacheci I, Rejchrt S, Bures J. Peutz-Jeghers syndrome: diagnostic and therapeutic approach. *World J Gastroenterol*. 2009;15:5397-408.
- Stojcev Z, Borun P, Hermann J, Krokowicz P, Cichy W, Kubaszewski L, et al. Hamartomatous polyposis syndromes. *Hered Cancer Clin Pract*. 2013;11:4.
- Kudo S, Tamura S, Nakajima T, Yamano H, Kusaka H, Watanabe H. Diagnosis of colorectal tumorous lesions by magnifying endoscopy. *Gastrointest Endosc*. 1996; 44:8.
- Peutz JL. Over een zeer merkwaardige, gecombineerde familiale polyposis van de slimgliezen van den tractus intestinalis met die van de neuskeelholte en gepaard met eigenaardige pigmentaties van huid-en slijmvliezen. *Ned Maandschr v Gen*. 1921;10:134.
- Utsunomiya J, Gocho H, Miyanaga T, Hamaguchi E, Kashimura A. Peutz-Jeghers syndrome: its natural course and management. *Johns Hopkins Med J*. 1975;136:71.
- Taheri D, Afshar-Moghadam N, Mahzoni M, Eftekhari A, Hashemi SM, Emami MH, et al. Cancer problem in Peutz-Jeghers syndrome. *Adv Biomed Res*. 2013;2:35.
- Lim W, Hearle N, Shah B, Murday V, Hodgson SV, Lucassen A, et al. Further observations on LKB1/STK11 status and cancer risk in Peutz-Jeghers syndrome. *Br J Cancer*. 2003;89:308.
- Horii J, Kato J, Nagasaka T, Hiraoka S, Sun DS, Watanabe K, et al. Development of invasive colon cancer with microsatellite instability in a patient with hyperplastic polyposis syndrome. *Jpn J Clin Oncol*. 2012;42:451-4.
- Giardiello FM, Welsh SB, Hamilton SR, Offerhaus GJA, Gittelsohn AM, Booker SV, et al. Increased risk of cancer in the Peutz-Jeghers syndrome. *N Engl J Med*. 1987;316:1511.
- Chen HM, Fang JY. Genetics of the hamartomatous polyposis syndromes: a molecular review. *Int J Colorectal Dis*. 2009;24:865-74.
- Burkart AL, Sheridan T, Lewin M, Fenton H, Ali NJ, Montgomery E. Do sporadic Peutz-Jeghers polyps exist? Experience of a large teaching hospital. *Am J Surg Pathol*. 2007;31:1209-14.
- Giardiello FM, Brensinger JD, Tersmette AC, Goodman SN, Petersen GM, Booker SV. Very high risk of cancer in familial Peutz-Jeghers syndrome. *Gastroenterology*. 2000;119:1447-53.
- Oncel M, Remzi FH, Church JM, Connor JT, Fazio VW. Benefits of 'clean sweep' in Peutz-Jeghers patients. *Colorectal Dis*. 2004;6:332-5.
- Vidal I, Podevin G, Piloquet H, Le Rhun M, Frémond B, Aubert D, et al. Follow-up and surgical management of Peutz-Jeghers syndrome in children. *J Pediatr Gastroenterol Nutr*. 2009;48:419-25.
- Gay G, Delvaux M, Frederic M. Capsule endoscopy in non-steroidal anti-inflammatory drugs-enteropathy and miscellaneous, rare intestinal diseases. *World J Gastroenterol*. 2008;14:5237-44.
- Gammon A, Jasperson K, Kohlmann W, Burt RW. Hamartomatous polyposis syndromes. *Best Pract Res Clin Gastroenterol*. 2009;23:219-31.
- Hearle N, Schumacher V, Menko FH, Olschwang S, Boardman LA, Gille JJP, et al. Frequency and spectrum of cancers in the Peutz-Jeghers syndrome. *Clin Cancer Res*. 2006;12:3209-15.
- Boardman LA, Thibodeau SN, Schaid DJ, Lindor NM, McDonnell SK, Burgart LJ, et al. Increased risk for cancer in patients with the Peutz-Jeghers syndrome. *Ann Intern Med*. 1998;128:896-9.
- Yajima H, Isomoto H, Nishioka H, Yamaguchi N, Ohnita K, Ichikawa T, et al. Novel serine/threonine kinase 11 gene mutations in Peutz-Jeghers syndrome patients and endoscopic management. *World J Gastrointest Endosc*. 2013;5:102-10.