



## Case Report

# Successful endoscopic treatment of fecalith blocking sinus in a patient with ileal pouch-anal anastomosis



Jessica Ma<sup>a,1</sup>, Brook Zhang<sup>a,1</sup>, Xian-rui Wu<sup>b</sup>, Bo Shen<sup>a,\*</sup>

<sup>a</sup> Department of Gastroenterology/Hepatology, The Cleveland Clinic Foundation, Cleveland, USA

<sup>b</sup> Department of Colorectal Surgery, The Cleveland Clinic Foundation, Cleveland, USA

## ARTICLE INFO

## Article history:

Received 13 February 2014

Accepted 27 February 2014

Available online 2 July 2014

## Keywords:

Fecalith

Needle knife

Pouch sinus

Ulcerative colitis

## ABSTRACT

**Background:** Ulcerative colitis patients who underwent restorative proctocolectomy with ileal pouch-anal anastomosis can develop various mechanical complications. Among them is presacral sinus resulting from chronic anastomotic leak.

**Methods:** We present a symptomatic patient with a large fecalith blocking the sinus which was successfully treated with Doppler ultrasound guided endoscopic needle knife sinusotomy along with fecalith extraction.

**Results:** A 67-year-old female presented with a 4-month history of perianal pain and urgency. Pouchoscopy showed a 3-cm deep wide-mouthed anastomotic sinus, the orifice of which was blocked by a large hard fecalith. Removal of the fecalith using RothNet, Tripod, or Basket were made but failed. Then needle knife was applied to cut the orifice to enlarge the opening of the sinus. One month later, the patient returned and the fecalith was successfully removed with two Baskets and two Rothnets. Six months after fecalith extraction, pouchoscopy showed a compartalized distal pouch sinus with two cavities, which was treated by two sessions of Doppler ultrasound guided endoscopic needle knife sinusotomy. Six months following the treatment, the sinus was completely healed. The patient tolerated all procedures well without any complication.

**Conclusion:** Fecalith blocking pouch anastomotic sinus is a rare complication in patients with restorative proctocolectomy. In our case, this surgical complication was successfully treated with a carefully planned, stepwise endoscopic approach.

© 2014 Sociedade Brasileira de Coloproctologia. Published by Elsevier Editora Ltda.

Este é um artigo Open Access sob a licença de [CC BY-NC-ND](https://creativecommons.org/licenses/by-nc-nd/4.0/)

\* Corresponding author.

E-mail: [shenb@ccf.org](mailto:shenb@ccf.org) (B. Shen).

<sup>1</sup> Summer intern from Case Western Reserve University, Cleveland, OH, USA.

<http://dx.doi.org/10.1016/j.jcol.2014.06.005>

2237-9363/© 2014 Sociedade Brasileira de Coloproctologia. Published by Elsevier Editora Ltda.

Este é um artigo Open Access sob a licença de [CC BY-NC-ND](https://creativecommons.org/licenses/by-nc-nd/4.0/)

## Tratamento endoscópico bem-sucedido de fecálito bloqueando seio em paciente com anastomose bolsa ileal-anal

### R E S U M O

#### Palavras-chave:

Fecálito  
Bisturi-agulha  
Seio bursal  
Colite ulcerativa

*Experiência:* Pacientes com colite ulcerativa tratados por proctocolectomia restauradora com anastomose bolsa ileal-anal podem ser acometidos por diversas complicações mecânicas. Entre elas, cita-se o seio pré-sacral resultante de vazamento crônico pela anastomose.

*Métodos:* Apresentamos uma paciente sintomática com um grande fecálito bloqueando o seio, com tratamento bem-sucedido com sinusotomia por bisturi-agulha guiado por ultrassom, juntamente com a extração do fecálito.

*Resultados:* Mulher, 67 anos, apresentou-se com história de 4 meses de dor perianal e urgência. A avaliação endoscópica da bolsa ileal revelou um seio anastomótico com grande abertura situada a 3 cm de profundidade, cujo orifício estava bloqueado por um grande fecálito endurecido. Foi tentada sem sucesso a remoção do fecálito com a ajuda de RothNet, Tripod, ou cestos recuperadores. Depois dessas tentativas, aplicamos um bisturi-agulha com o objetivo de seccionar o orifício com vistas à ampliação da abertura do seio. Um mês depois, a paciente retornou, e o fecálito foi removido com sucesso com dois cestos recuperadores e dois RothNets. Transcorridos seis meses após a remoção do fecálito, uma avaliação endoscópica da bolsa ileal revelou um seio distal compartimentado com duas cavidades, tratado por duas sessões de sinusotomia endoscópica por bisturi-agulha guiado por ultrassom. Seis meses depois do tratamento, o seio estava completamente curado. A paciente tolerou satisfatoriamente todos os procedimentos, sem qualquer complicação.

*Conclusão:* A presença de um fecálito bloqueando o seio anastomótico de bolsa ileal é complicação rara em pacientes submetidos a uma proctocolectomia restauradora. Em nosso caso, essa complicação cirúrgica foi tratada com sucesso com uma abordagem endoscópica em etapas, cuidadosamente planejada.

© 2014 Sociedade Brasileira de Coloproctologia. Publicado por Elsevier Editora Ltda.

Este é um artigo Open Access sob a licença de [CC BY-NC-ND](#)

## Background

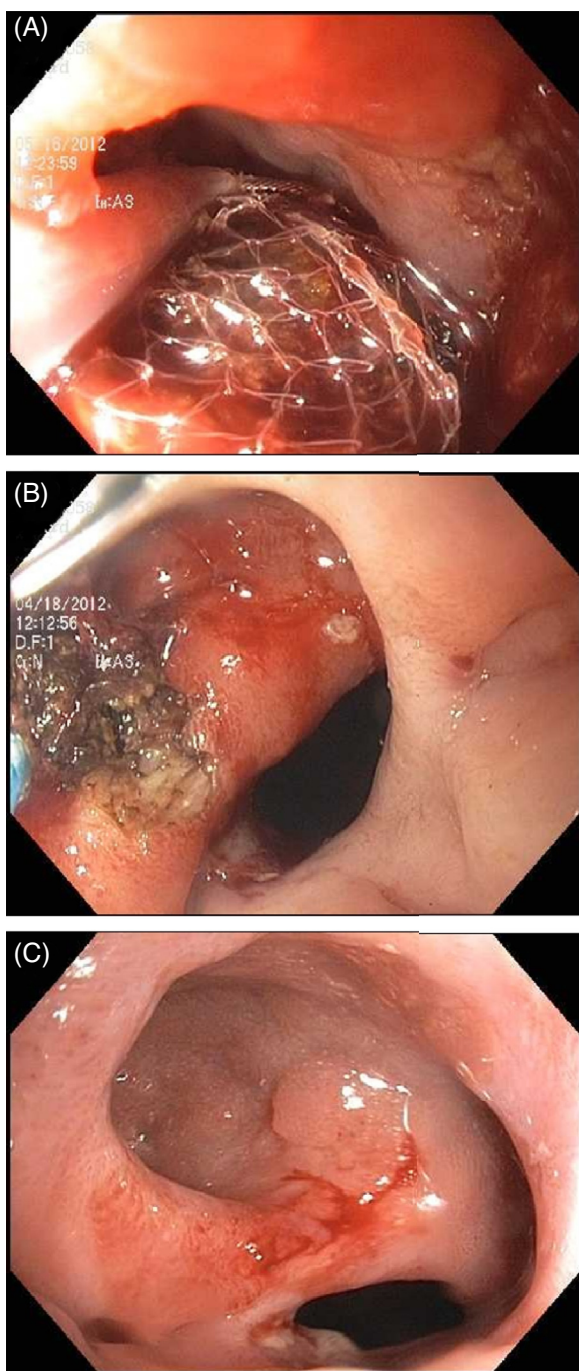
Restorative proctocolectomy with ileal pouch-anal anastomosis (IPAA) has been widely accepted as the surgical procedure of choice for the majority of patients with ulcerative colitis (UC) or familial adenomatous polyposis (FAP) who require colectomy. However, this procedure can cause various postoperative complications. Anastomotic leak resulting in the formation of sinus is one of the most common surgical technique-associated complications.<sup>1,2</sup> On the other hand, fecal bezoar can occur in patients with ileal pouches, being often located at the pouch body.<sup>2,3</sup> Here we reported on a patient with a large fecalith located at the orifice of anastomotic sinus causing severe symptoms. The fecalith and sinus were successfully treated with a stepwise endoscopic approach.

## The patient

A 67-year-old female presented to our Pouch Center with a 4-month history of perianal pain and urgency in April 2012. Her past medical and surgical history was significant for having a two-stage J pouch surgery for medically refractory ulcerative colitis (UC) in 1999. Both surgery and hospitalization were uneventful.

At presentation, the patient was taken to the outpatient endoscopy suite. Informed consent was obtained. On conscious sedation, a pouchoscopy was performed with a GIF-H180 gastroscope (Olympus, Tokyo, Japan). An anastomotic sinus with a depth of 3 cm was found and the orifice was blocked by a large hard fecalith. Initially we planned to retrieve the fecalith first followed by treating the pouch sinus with ultrasound (Vascular Technology Inc. [VTI], Nashua, New Hampshire, USA) guided endoscopic needle knife (Olympus Medical Systems, Tokyo, Japan) sinusotomy at the setting of ERCP endocut (USA Incorporated Surgical Systems, Marietta, Georgia, USA). Multiple attempts using RothNet (US Endoscopy, Mentor, OH), Tripod (Endoscopy Support Service America, Brewster, NY), or endoscopic Basket (Olympus America, Melville, NY) were made to remove the fecalith, however none of them succeeded. Then we decided to use the needle knife to cut the common wall between the sinus and the pouch body to lay open the sinus tract and try to take out the fecalith in the next pouchoscopy. At the pouchoscopy, there was also a tight anastomotic stricture, which was successfully dilated using the guide wire-controlled radial expansion (CRE) balloons (Boston Scientific, Boston, MA). Multiple biopsies were taken, which were not remarkable.

One month later, the patient returned to our Pouch Center. Pouchoscopy was performed following the same protocol as the previous one. The fecalith at the sinus cavity was successfully removed with two endoscopic Baskets and two Rothnets (Fig. 1A). Since there was still mucosal scar at the septum



**Fig. 1 – Successful endoscopic treatment of fecalith blocking sinus in a patient with an ileal pouch. A, fecalith removed using two baskets and two Roth-Nets; B, compartmentalized sinus treated with needle-knife sinusotomy; C, a healed and epithelialized pouch sinus.**

between the sinus and pouch body resulted from the last session of needle-knife therapy, pouch sinus was not treated. Six months after removing the fecalith, the patient came back to our Pouch Center for the further management of the pouch sinus. Then, the pouchoscopy showed a compartmentalized distal pouch sinus with two cavities. Another session of Doppler ultrasound guided endoscopic needle knife sinusotomy was

offered to treat the sinus (Fig. 1B). At the most recent follow-up 6 months after treating the pouch sinus, the pouchoscopy showed a healed sinus (Fig. 1C). The patient tolerated all procedures well in an outpatient setting without any complication. The patient continued to do well after the procedures and reported the resolution of her symptoms.

## Discussion

Pouch sinus, a less known disease entity in patients with IPAA, is a special form of anastomotic leak defined by a blind-ended track. The reported frequency of pouch sinus in patient undergoing IPAA ranged from 2.8% to 8%.<sup>1,4,5</sup> The common symptoms of pouch sinus included pelvic discomfort or pain, dyschezia, and urgency. Pouch sinus deserves a close surveillance and timely treatment, as it may have a significant impact on pouch outcomes and patients' QOL. Bezoar in the ileal pouches is an even more rare complication following IPAA, with only case reports published in the literature.<sup>2,3,6</sup> To the best of our knowledge, our study reported the first case with a symptomatic sinus at the distal pouch which was blocked by a large fecalith. Furthermore, we showed the feasibility of treating fecalith blocking sinus by removing the fecalith and applying the ultrasound guided needle knife sinusotomy accomplished using the endoscopic approach.

The management for bezoar in the ileal pouches is straightforward. With advanced equipment and techniques, retrieval of the bezoar using the endoscopic approach has become the preferred treatment modality. The challenging part of endoscopic extraction in this patient is the location of the fecalith. In our case, we failed to remove the fecalith in the first pouchoscopy although multiple attempts were made using different tools.

Pouch sinus may be managed by observation, endoscopy, or surgery. Patients with pouch sinuses have been historically managed with an operative approach, including drainage or surgical closing of the sinus, mucosal advanced flaps, redo pouch surgery or pouch excision.<sup>4</sup> Although surgical treatment for pouch sinus might be effective in experienced hands, the procedures themselves are often technically challenging with the potential risk for procedure-related adverse events. In our study of 65 patients with pouch sinuses from our group,<sup>1</sup> we showed that endoscopic needle-knife therapy was an efficacious and safe procedure for pouch sinuses. With previous vast experience of this treatment modality, we applied ultrasound guided needle knife sinusotomy to treat the pouch sinus in this patient, after two sessions of which the pouch sinus was found to be completely healed in the follow-up pouchoscopy. As shown in our previous study,<sup>1</sup> the needle-knife therapy has its pros and cons. Endoscopic needle-knife sinusotomy holds the benefits of being less invasive, relatively easy to perform. No hospitalization is required, and patients have a quick recovery. However, some of patients need to be treated in multiple sessions. Furthermore, this procedure should be performed in experienced hands.

In conclusion, we successfully applied endoscopic therapy in a symptomatic patient with a large fecalith trapped at the orifice of presacral sinus. We demonstrated that this complex surgical complication might be successfully treated with a carefully planned, stepwise endoscopic approach.

---

### Conflicts of interest

The authors declare no conflicts of interest.

---

### Acknowledgments

Prof. Bo Shen hold the Ed and Joey Story Endowed Chair.

### REFERENCES

---

1. Wu XR, Wong RC, Shen B. Endoscopic needle-knife therapy for ileal pouch sinus: a novel approach for the surgical adverse event (with video). *Gastrointest Endosc.* 2013;78:875-85.
2. Lian L, Fazio V, Shen B. Endoscopic treatment for pill bezoars after continent ileostomy. *Dig Liver Dis.* 2009;41:e26-8.
3. Mmeje C, Bouchard A, Heppell J. Image of the month. Pharmacobezoar: a rare complication after ileal pouch-anal anastomosis for ulcerative colitis. *Clin Gastroenterol Hepatol.* 2010;8:A28.
4. Ahmed Ali U, Shen B, Remzi FH, Kiran RP. The management of anastomotic pouch sinus after IPAA. *Dis Colon Rectum.* 2012;55:541-8.
5. Akbari RP, Madoff RD, Parker SC, Hagerman G, Minami S, Bullard Dunn KM, et al. Anastomotic sinuses after ileoanal pouch construction: incidence, management, and outcome. *Dis Colon Rectum.* 2009;52:452-5.
6. Goligher JC. Impaction of plastic emptying tube in reservoir of continent ileostomy. *Br J Surg.* 1984;71:734.