



Review Article

Management of acute colorectal diseases in febrile neutropenic patients[☆]



Camila Perazzoli^a, Marley Ribeiro Feitosa^{a,*}, Lorena Lobo de Figueiredo-Pontes^b,
José Joaquim Ribeiro da Rocha^a, Belinda Pinto Simões^b, Omar Féres^a

^a Division of Coloproctology, Department of Surgery and Anatomy, Ribeirão Preto Medical School, University of São Paulo (USP), Ribeirão Preto, SP, Brazil

^b Division of Hematology, Department of Internal Medicine, Ribeirão Preto Medical School, University of São Paulo (USP), Ribeirão Preto, SP, Brazil

ARTICLE INFO

Article history:

Received 24 April 2014

Accepted 17 June 2014

Available online 8 July 2014

Keywords:

Febrile neutropenia

Typhlitis

Anal canal

ABSTRACT

Patients with hematologic malignancies are susceptible to serious complications due to immunosuppression. Neutropenic-related infection is one of the major causes of morbidity and mortality in this group of diseases. Febrile neutropenia is a common complication of the hematologic neoplasm itself or chemotherapy, and has worse prognosis if prolonged (lasting more than 7 days) or severe (neutrophil count below 500 cells per μL). Among the usual sites of infection, we highlight the neutropenic enterocolitis and perianal infection as gastrointestinal complications of greater interest to the colorectal surgeon. Although most cases respond to conservative treatment, a portion of patients will need surgery for complete recovery.

© 2014 Sociedade Brasileira de Coloproctologia. Published by Elsevier Editora Ltda.

Este é um artigo Open Access sob a licença de [CC BY-NC-ND](https://creativecommons.org/licenses/by-nc-nd/4.0/)

Tratamento das doenças colorretais agudas no paciente neutropênico febril

RESUMO

Os pacientes com neoplasias hematológicas estão sujeitos a uma séria de complicações devido à imunossupressão. Infecção é umas das principais causas de morbidade e mortalidade nesse grupo de doenças. A neutropenia febril é uma complicação frequente da própria doença onco-hematológica ou da quimioterapia, e apresenta pior prognóstico se prolongada (duração acima de 7 dias) ou severa (contagem de neutrófilos inferior a 500 células por microlitro). Dentre os focos de infecção mais comuns destacamos a enterocolite neutropênica e a infecção perianal como complicações de maior interesse para o

Palavras-chave:

Neutropenia febril

Tiflíte

Canal anal

[☆] Performed at the Department of Surgery and Anatomy, Ribeirão Preto Medical School, University of São Paulo (USP), São Paulo, SP, Brazil.

* Corresponding author.

E-mail: marleyfeitosa@yahoo.com.br (M.R. Feitosa).

<http://dx.doi.org/10.1016/j.jcol.2014.06.002>

2237-9363/© 2014 Sociedade Brasileira de Coloproctologia. Published by Elsevier Editora Ltda.

Este é um artigo Open Access sob a licença de [CC BY-NC-ND](https://creativecommons.org/licenses/by-nc-nd/4.0/)

cirurgião colorretal. Apesar de grande parte dos casos apresentar boa resposta ao tratamento conservador, uma parcela de pacientes necessitará de cirurgia para completa recuperação.

© 2014 Sociedade Brasileira de Coloproctologia. Publicado por Elsevier Editora Ltda.

Este é um artigo Open Access sob a licença de [CC BY-NC-ND](#)

Febrile neutropenia

Neutropenia is a common finding in patients with hematological malignancies. It occurs as a manifestation of the disease or a consequence of immunosuppressive treatment.¹ It is usually defined as an absolute neutrophil count (ANC) of 1500 or fewer neutrophils per μL of blood. Patients affected by acute leukemia, leukemic phase lymphomas, myelodysplastic syndromes and those receiving high intensity chemotherapy or bone marrow transplantation conditioning regimens are especially prone to develop severe neutropenia defined by an ANC of less than 500 cells/ μL .²

The risk of serious infection is significantly higher if neutropenia is severe or prolonged (more than seven days) and the most common sites are: skin, venous catheters, dental diseases, oropharynx, gums, paranasal sinuses, lungs, abdomen, genitals and perianal area.² Inflammatory response is compromised in those patients, thus few or no signs may be found. Sometimes fever may be the only complaint. In this context, the clinical condition of Febrile Neutropenia is defined as the detection of a single oral temperature measurement of $\geq 38.3^\circ\text{C}$ or a temperature of $\geq 38^\circ\text{C}$ sustained over a one hour-period in the presence of an $\text{ANC} \leq 500$ neutrophils/ μL or an ANC that is expected to decrease to ≤ 500 neutrophils/ μL during the next 48 h. In addition, neutropenic patients who are a febrile but have signs or symptoms of infection should be equally managed as febrile neutropenic patients. Prompt recognition and treatment of any infectious process is crucial since the clinical status may rapidly deteriorate to sepsis and death.²

Correct evaluation of patients includes detailed anamnesis, meticulous physical exams and laboratory tests to determine the severity of the complication and to locate the source of infection. Low-risk patients are those who have estimated neutropenia for no longer than seven days and no organ failures. In contrast, high-risk patients are those with anticipated prolonged neutropenia, profound neutropenia ($\text{ANC} \leq 100$ neutrophils/ μL) and/or clinical conditions such as hypotension, pneumonia, neurological symptoms and abdominal pain. The index from the Multinational Association for Supportive Care in Cancer may be used as a risk assessment tool with high sensitivity and specificity.³ Of note, all high risk patients should be admitted to the hospital and receive empirical intravenous large spectrum antibiotic therapy.²

The physician must carefully evaluate the complaint of abdominal pain in a neutropenic patient since it may alert for the occurrence of a severe gastrointestinal infection. Indeed, signs of peritonitis during the evaluation may represent complications such as typhlitis, pseudomembranous colitis or other causes of acute abdomen.^{4,5} Patients must also have their perianal region checked for anorectal diseases and

flogosis. Rectal exam should not be neglected and invasive procedures must be taken with the appropriate consideration of the risk of bacterial translocation and disease worsening.⁶

Neutropenic enterocolitis

Classically known as typhlitis or ileocecal syndrome, neutropenic enterocolitis is a necrotizing polymicrobial colitis, diagnosed almost exclusively in patients with neutropenia.⁷ The word “typhlon” means cecum in Greek, nevertheless the terminal ileum and the whole colon may be also affected. Although this condition is often described as necrotizing enterocolitis, the clinical picture may vary from a mild, non-necrotizing form, to a severe transmural process with a high risk of death.⁸

Neutropenic enterocolitis has been historically reported as the most common gastrointestinal complication in patients with fever, neutropenia and abdominal pain, affecting as much as 50% of such patients, which mortality rates that vary from 20 to 50%.^{9,10}

The genesis of this complication waits for complete understanding, however some factors may be involved: chemotherapy cytotoxic effects, damage of gut mucosa, immunosuppression and translocation of virulent microorganisms. The pathologic result is gangrenous necrosis, subserosal gas accumulation and perforation of the affected segment, due to intestinal infarction.⁴

The diagnosis of typhlitis should be presumed in patients with severe neutropenia, abdominal pain (right lower quadrant) and fever. Physical exam may evidence abdominal distention and tenderness. Differential diagnosis includes acute appendicitis, psoas abscess and pseudomembranous colitis.^{5,11} Computed tomography usually seals the diagnosis by revealing thick and dilated bowel walls with mesenteric stranding.¹² Plain films of the abdomen can be used to detect pneumoperitoneum. Invasive procedures such as colonoscopy and barium enema may cause bowel perforation and should not be attempted. A flexible sigmoidoscopy and *C. difficile* assays may be necessary to rule out pseudomembranous colitis in a patient with important diarrhea associated to abdominal distention and recent history of antibiotic therapy.¹³

Medical treatment of uncomplicated typhlitis consists of broad-spectrum antibiotics, bowel rest, nasogastric suction, hydroelectrolytic adjustment and anemia correction (Fig. 1). To choose the right empiric antibiotic regimen, the physician must: (1) consider the polymicrobial nature of the infection; (2) evaluate the patient's risk factors for complicated outcome; and (3) know the local resistance of pathogens.^{2,14} Cefepime, a fourth generation cephalosporin, is the first option in our institution. If resistant gram-negative bacteria infection is

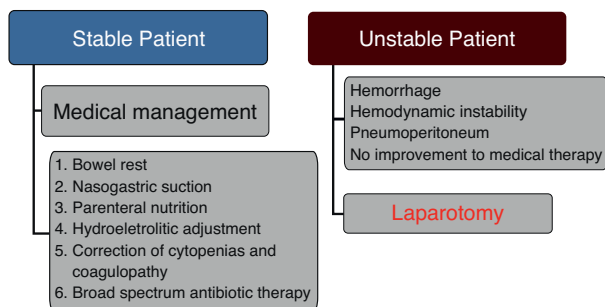


Fig. 1 – Neutropenic enterocolitis management.

suspected either by blood cultures or previous patient's colonization, the addition of an aminoglycoside is recommended. The use of a carbapenem or piperacillin-tazobactam is also acceptable as first line therapy. Metronidazole or vancomycin should be added for suspected *C. difficile* infection. The use of antifungal therapy can be also advised in individual cases with persistent and long-term neutropenia and refractoriness to the antibacterial agent. Finally, supportive care with transfusions to improve anemia, thrombocytopenia and coagulation defects as well as the use of granulocyte stimulating factors or granulocyte infusions should be also be considered and individualized to each patient.

The disease is considered as complicated in the presence of bowel perforation with peritonitis, gastrointestinal hemorrhage or deterioration of the clinical status (such as sepsis or organ perfusion impairment). For those cases, surgery is the only option and patient's life depends on the ability of the surgeon to identify and remove all devitalized tissue.¹⁵ Usually, a right hemicolectomy with a terminal ileostomy and mucous fistula appears to be a reasonable option given the serious nature of the disease at this point.¹⁶

Anorectal diseases

Neutropenic patients are susceptible to any anorectal disease. Perianal infection (represented by an abscess or infected fistula) is the most feared complication, considering the lack of natural defense against infectious microorganisms. Manifestations may differ from those with a competent immune system and include mild to severe anorectal pain, fever and a poorly defined induration of the anal canal. Perianal infection is a life-threatening complication that requires ready diagnosis and intervention as recurrence and mortality rates may be expressive.¹⁷ In a series of 92 patients with acute or chronic leukemia, the most common manifestations were perirectal abscess (27%), followed by anal fissures (23%), external hemorrhoids (19%) and perianal ulcerations (13%). Only 16% of the patients required surgery most commonly to drain perirectal abscesses.¹⁸ Another retrospective study of 1102 patients found a perianal infection prevalence of 6.7%. Recurrence was diagnosed in 31% of the cases and 34% of the patients received surgical intervention.¹⁹

Conservative measures consist of systemic antibiotics, sitz baths, stool softeners and proper anal hygiene. Spectrum of antibiotic coverage should be broad given the polymicrobial

nature of the Infection. In a review of 963 cases of bone marrow transplantation, the most common microorganisms were *Escherichia coli*, *Bacteroides*, *Enterococcus*, and *Klebsiella*.²⁰ Surgery harbors the risks of uncontrolled bleeding and poor healing but may be the only choice for abscesses and fistulas. If any operation is to be considered, common sense dictates the decision on holding the chemotherapy.

Conclusions

Patients with neutropenia are predisposed to a variety of infectious diseases. Prompt recognition and early treatment of such complications are essential for survival. Much attention should be paid to the abdomen, perineum and anorectal area, since they can be the sites of infection. The diagnosis of neutropenic enterocolitis, anorectal abscesses, or fistulas requires immediate consultation with a colorectal surgeon, even though medical management may be sufficient for a significant portion of cases. In the presence of uncontrolled sepsis, bowel wall perforation, continuous gastrointestinal hemorrhage, surgery becomes the last resource and life will depend on the surgeon's knife.

Conflicts of interest

The authors declare no conflicts of interest.

REFERENCES

- Keidan RD, Fanning J, Gatenby RA, Weese JL. Recurrent typhilitis. A disease resulting from aggressive chemotherapy. *Dis Colon Rectum*. 1989;32:206–9.
- Freifeld AG, Bow EJ, Sepkowitz KA, Boeckh MJ, Ito JI, Mullen CA, et al. Clinical practice guideline for the use of antimicrobial agents in neutropenic patients with cancer: update by the Infectious Diseases Society of America. *Clin Infect Dis*. 2010;52:427–31.
- Uys A, Rapoport BL, Anderson R. Febrile neutropenia: a prospective study to validate the Multinational Association of Supportive Care of Cancer (MASCC) risk-index score. *Support Care Cancer*. 2004;12:555–60 [Epub 2004].
- Katz JA, Wagner ML, Gresik MV, Mahoney Junior DH, Fernbach DJ. Typhilitis. An 18-year experience and postmortem review. *Cancer*. 1990;65:1041–7.
- Wade DS, Nava HR, Douglass HO. Neutropenic enterocolitis clinical diagnosis and treatment. *Cancer*. 1992;69:17–23.
- Grewal H, Guillem JG, Quan SH, Enker WE, Cohen AM. Anorectal disease in neutropenic leukemic patients: Operative vs. nonoperative management. *Dis Colon Rectum*. 1994;37:1095–9.
- Rolston KV, Bodey GP, Safdar A. Polymicrobial infection in patients with cancer: an underappreciated and underreported entity. *Clin Infect Dis*. 2007;45:228–33.
- Bremer CT, Monahan BP. Necrotizing enterocolitis in neutropenia and chemotherapy: a clinical update and old lessons relearned. *Curr Gastroenterol Rep*. 2006;8:333–41.
- Gorschlüter M, Mey U, Strehl J, Ziske C, Schepke M, Schmidt-Wolf IG, et al. Neutropenic enterocolitis in adults: systematic analysis of evidence quality. *Eur J Haematol*. 2005;75:1–13.

10. Cardona AF, Ramos PL, Casasbuenas A. From case reports to systematic reviews in neutropenic enterocolitis. *Eur J Haematol*. 2005;75:445–6.
11. de Brito D, Barton E, Spears KL, Cranmer HH, Karp SJ, Anglin D, et al. Acute right lower quadrant pain in a patient with leukemia. *Ann Emerg Med*. 1998;32:98–101.
12. Kirkpatrick ID, Greenberg HM. Gastrointestinal complications in the neutropenic patient: characterization and differentiation with abdominal CT. *Radiology*. 2003;226:668–74 [Epub 2003].
13. Kelly CP, Pothoulakis C, LaMont JT. *Clostridium difficile* colitis. *N Engl J Med*. 1994;330:257–62.
14. Averbuch D, Orasch C, Cordonnier C, Livermore DM, Mikulska M, Viscoli C, et al. ECIL4, a joint venture of EBMT, EORTC, ICHS, ESGICH/ESCMID and ELN. European guidelines for empirical antibacterial therapy for febrile neutropenic patients in the era of growing resistance: summary of the 2011 4th European Conference on Infections in Leukemia. *Haematologica*. 2013;98(December (12)):1826–35, <http://dx.doi.org/10.3324/haematol.2013.091025> [Erratum in: *Haematologica*. 2014;99:400].
15. Shamberger RC, Weinstein HJ, Delorey MJ, Levey RH. The medical and surgical management of typhlitis in children with acute nonlymphocytic (myelogenous) leukemia. *Cancer*. 1986;57:603.
16. Moir CR, Scudamore CH, Benny WB. Typhlitis: selective surgical management. *Am J Surg*. 1986;151:563–6.
17. Barnes SG, Sattler FR, Ballard JO. Perirectal infections in acute leukemia Improved survival after incision and debridement. *Ann Intern Med*. 1984;100:515–8.
18. North JH, Weber TK, Rodriguez-Bigas MA, Meropol NJ, Petrelli NJ. The management of infectious and noninfectious anorectal complications in patients with leukemia. *J Am Coll Surg*. 1996;183:322–8.
19. Chen CY, Cheng A, Huang SY, Sheng WH, Liu JH, Ko BS, et al. Clinical and microbiological characteristics of perianal infections in adult patients with acute leukemia. *PLOS ONE*. 2013;8:e60624, <http://dx.doi.org/10.1371/journal.pone.0060624> [Epub 2013].
20. Cohen JS, Paz IB, O'Donnell MR, Ellenhorn JD. Treatment of perianal infection following bone marrow transplantation. *Dis Colon Rectum*. 1996;39:981–5.