



Original Article

Four-arm single docking full robotic surgery for low rectal cancer: techniques and post-operative outcomes



José Reinan Ramos^{a,*}, Alexandre Duarte Miranda^a, Wilermo Torres^a,
Eduardo Parra-Davila^b

^a Service of Robotic Surgery, Hospital Samaritano, Rio de Janeiro, RJ, Brazil¹

^b Medical Director for Minimally Invasive Abdominal Reconstruction and Colorectal Surgery, Florida Hospital Celebration Health, Orlando, USA

ARTICLE INFO

Article history:

Received 15 September 2013

Accepted 21 November 2013

Available online 13 April 2014

Keywords:

Robotic rectal surgery

Robotic intersphincteric resection

Robotic extralevator

abdominoperineal resection

Full robotic low anterior resection

ABSTRACT

Background: laparoscopic rectal surgery has not yet achieved a high penetration rate because of its steep learning curve and its relatively high conversion rate. Robotic rectal resection represents the main indication of the use of the robotic platform in colorectal surgery. The aim of this study was to present an early experience with robotic surgery to treat mid and low rectal cancer focusing on the technique and early postoperative outcomes.

Methods: from December 2012 to October 2013, a total of 16 patients with colorectal diseases were operated on using a four-arm single docking full robotic procedure (daVinci Si Surgical System). The treatment of six consecutive patients who underwent robotic rectal cancer surgery for mid or low rectal adenocarcinoma was prospectively analyzed regarding technique standardization, pathological findings and postoperative outcomes.

Results: there were no conversions and one intraoperative complication. The mean operative time was 245 min (180–360 min). The mean console time was 170 min (110–240 min). All patients underwent a standardized totally robotic rectal dissection. There were no mortality or urinary dysfunction and one complication (postoperative ileo-16%). The median length of hospital stay was 6 (4–11 days). The median number of lymph nodes harvested was 22 (7–38), and distal and circumferential resection margins were negative in all specimen. R0 resection was achieved in all cases and complete total mesorectal excision in five specimen and nearly complete in one.

Conclusion: standardized robotic rectal surgery is a promising alternative to treat patients with mid or low rectal cancer and is expected to overcome the low penetration rate of laparoscopic surgery in this field. This technique was successfully performed in six patients with excellent immediate postoperative and pathological results. Additional studies in a large series of patients are necessary to confirm those advantages.

© 2014 Sociedade Brasileira de Coloproctologia. Published by Elsevier Editora Ltda.

Este é um artigo Open Access sob a licença de CC BY-NC-ND

* Corresponding author.

E-mail: jreinanramos@hotmail.com (J.R. Ramos).

¹ General Coordinator: Vipul Patel.

<http://dx.doi.org/10.1016/j.jcol.2014.04.002>

2237-9363/© 2014 Sociedade Brasileira de Coloproctologia. Published by Elsevier Editora Ltda.

Este é um artigo Open Access sob a licença de CC BY-NC-ND

Cirurgia totalmente robótica para o tratamento do câncer do reto distal: técnicas e resultados do pós-operatório imediato

R E S U M O

Palavras-chave:

Cirurgia robótica retal
Ressecção Interesfínctérica robótica
Ressecção abdominoperineal extraelevadora robótica
Ressecção anterior do reto totalmente robótica

Introdução: a utilização da cirurgia videolaparoscópica para o tratamento do câncer do reto ainda não apresentou uma alta penetração devido a longa curva de aprendizado e a uma taxa de conversão relativamente alta. A ressecção retal robótica é a principal indicação para o uso da plataforma robótica na cirurgia colorretal. O objetivo desse estudo é apresentar as técnicas e os resultados pós-operatórios imediatos com o uso da cirurgia robótica para o tratamento do câncer do reto distal.

Pacientes e métodos: no período de dezembro de 2012 a outubro de 2013 foram operados 16 pacientes com patologias colorretais utilizando o robô daVinci SI Surgical System. O tratamento de 6 consecutivos pacientes portadores de câncer do reto do terço médio e do terço inferior foram prospectivamente avaliados quanto a sistematização técnica, achados patológicos e evolução pós-operatória.

Resultados: não houve conversão e ocorreu uma complicação intraoperatória. A duração média das operações foi de 245 minutos (180-360 minutos) e o tempo médio do uso do console foi de 170 minutos (110-240 minutos). Ocorreu uma complicação pós-operatória (Íleo) e não houveram nenhuma disfunção urinária ou mortalidade. A duração média da internação hospitalar foi de 6 dias (4-11 dias). O número médio de linfonodos examinados foi de 22 (7-38) e todas as peças tinham margens distal e circunferencial negativas. Ressecção RO foi observada em todos os casos e o grau de excisão total do mesorreto foi completo em 5 peças e quase completo em uma.

Conclusão: cirurgia robótica sistematizada esta tendo uma crescente aceitação e é uma ótima alternativa para o tratamento dos pacientes com câncer do reto distal. Esta tecnologia foi utilizada em 6 pacientes com excelentes resultados não só na recuperação pós-operatória imediata como também nos achados da avaliação patológica. Grandes series randomizadas são importantes para confirmar as possíveis vantagens dessa nova tecnologia.

© 2014 Sociedade Brasileira de Coloproctologia. Publicado por Elsevier Editora Ltda.

Este é um artigo Open Access sob a licença de [CC BY-NC-ND](#)

Introduction

Recent studies¹⁻⁴ have reported better short-term outcomes and similar oncological result when comparing laparoscopic rectal cancer surgery to open surgery. Laparoscopic rectal surgery could not achieve a high impact because of the steep learning curve, high rate of conversion, and the technical challenge of work in a narrow pelvis with limited instruments maneuverability, especially in obese patient and in patients who were treated by preoperative chemoradiotherapy. It is currently estimated that only 10% of the rectal resections are performed by laparoscopic technique.

Enthusiasm for the robotic platform, as a minimally invasive approach, has gained most interest in the area of rectal surgery. Robotic rectal surgery offers various advantages over traditional laparoscopy because it can provide surgeons with a three-dimension magnification (3D) view and the ability to control the operative field by manipulating the camera, as well as enhanced dexterity and precision due to endowrist instruments with 7 degrees of freedom. The robotic system improves visualization, exposure, and dissection in confined spaces such as the pelvic cavity. Studies⁵⁻⁹ have reported not only a lower learning curve but also a lower conversion rate and a better mesorectal grade when compared to laparoscopic rectal cancer surgery.

The aim of this study was to present an early experience with robotic surgery to treat mid and low rectal cancer focusing on the technique and early postoperative outcomes.

Patients

The treatment of six consecutive patients who underwent robotic rectal cancer surgery for mid or low rectal adenocarcinoma at the department of robotic surgery of Samaritano Hospital-Rio de Janeiro-Brasil from December 2012 to October 2013 was prospectively analyzed regarding technique standardization, pathological findings and postoperative outcomes. All procedures were carried out by the same surgeon (JRR) and the same proctor (EPD). All patients received an extensive explanation about the robotic technique.

Surgical technique

The four-arm single docking full robotic procedure employed for total mesorectal excision and coloanal anastomosis or intersphincteric resection or cylindrical abdominoperineal resection has been published by Ramos JR and Parra-Dávila E.¹⁰ There are eight main steps for those procedures.

1. Lloyd-Davis lithotomy position in a 30° Trendelenburg and 20° right-side down with the arms alongside the body. The position was secured with a vacuum-mattress device.

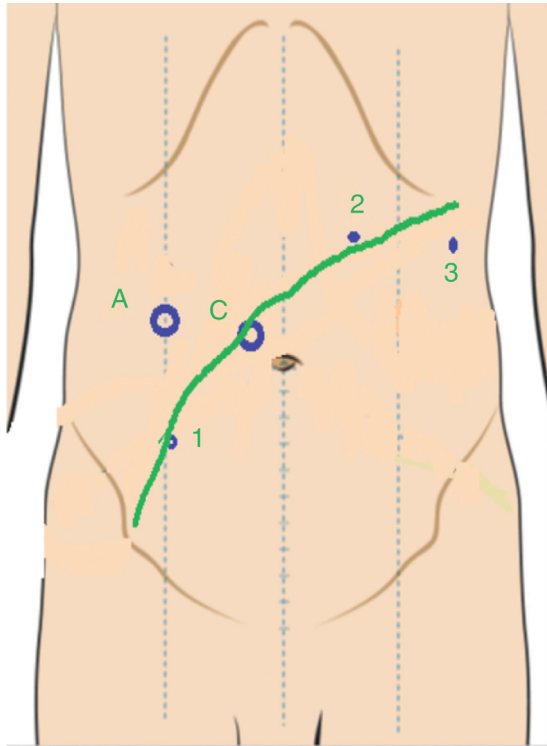


Fig. 1 – Trocars set-up.

2. Trocars set-up and robot docking over the patient left hip (Figs. 1 and 2).
3. Sigmoid colon, left colon and splenic flexure mobilization (lateral-to-medial approach) (Fig. 3).
4. Inferior mesenteric artery and vein ligation (medial-to-lateral approach) (Fig. 4).
5. Total mesorectum excision and hypogastric and pelvic autonomic nerves preservation (sacral rectal dissection, lateral rectal dissection, pelvic rectal dissection) (Fig. 5A–D).
6. Division of the rectum using an endo roticulator stapler (Fig. 6), undocking the robot, extraction of the specimen via abdominal incision and performing a double-stapled coloanal anastomosis laparoscopically (tumor type I – Fig. 7).
7. Intersphincteric resection, extraction of the specimen through the anus and latero-to-end hand sewn coloanal anastomosis (Fig. 8A and B). Tumor Type II.




Fig. 2 – Robot docking.

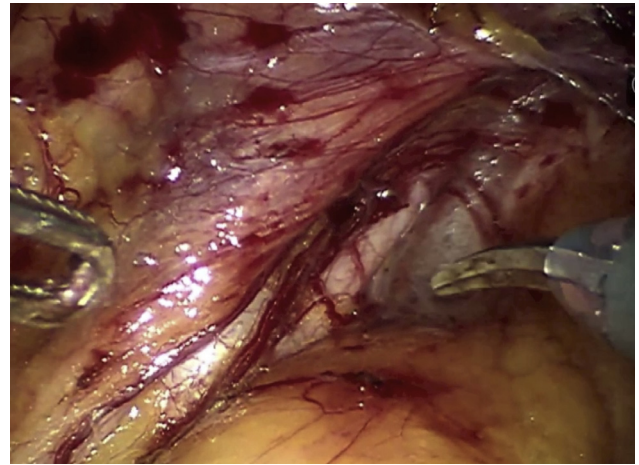


Fig. 3 – Sigmoid colon mobilization and left ureter identification (lateral-to-medial approach).

8. Cylindrical APR resection with transabdominal section of the levator muscles (Fig. 9A and B). Tumor type IV.

Results

From December 2012 to October 2013, 6 consecutive patients with mid or low rectal cancer were operated on using a four-arm single docking full robotic procedure (daVinci Si Surgical System-Intuitive Surgical, Mountain View, CA, USA). There were 4 male patients and 2 female patients. The median age was 68 years and median body mass index (BMI) was 25.3 kg/m². Four patients have comorbidity, three have previous abdominal surgery and four were treated by preoperative chemo-irradiation therapy (Table 1). Four tumors were type I, one type II and one type IV following Rullier's classification (Fig. 7).¹¹

The median operative time was 245 min (180–360 min), the median console time was 170 min (110–240 min), and no procedure was converted. The median length of hospital stay was 6 days.⁴⁻¹¹ There were no urinary dysfunction and one postoperative complication (ileus) and one intraoperative complication (subcutaneous enzifema and hypercarptenia)

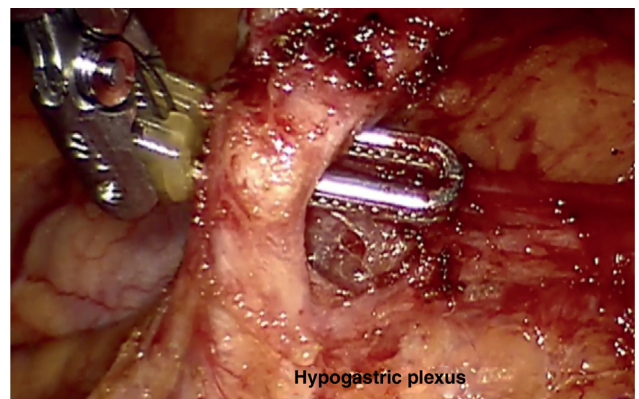


Fig. 4 – Inferior mesenteric artery ligation and hypogastric plexus preservation (medial-to-lateral approach).

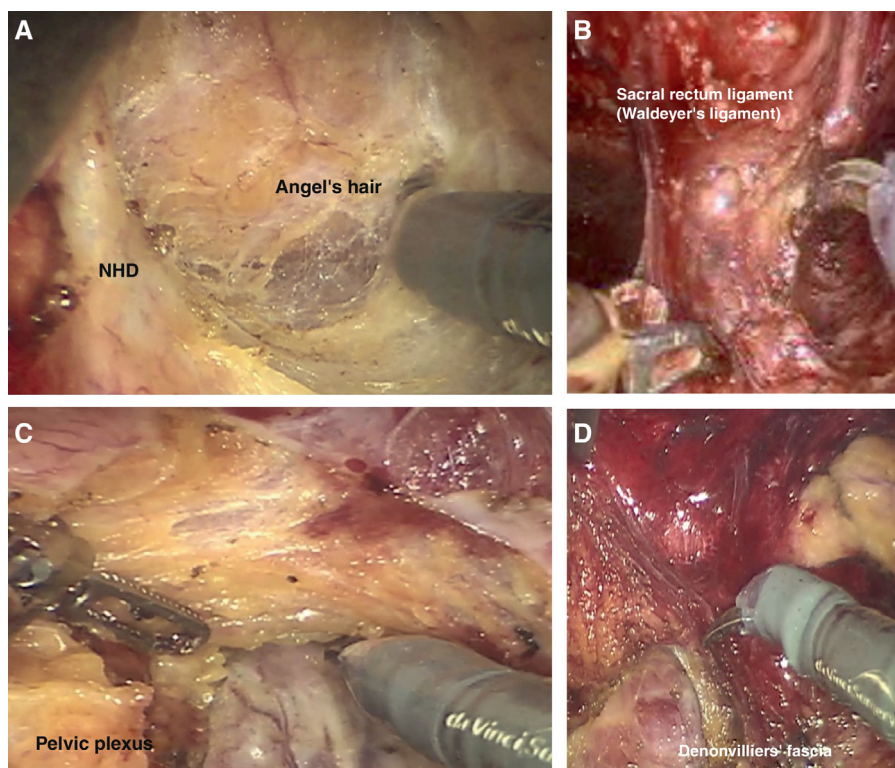


Fig. 5 – Total mesorectal excision and hypogastric and pelvic nerves preservation. (A) Dissection in the horizontal or sacral plane. (B) Lateral dissection. (C) and (D) Dissection in the vertical or pelvic plane.

Table 1 – Patients' characteristics and tumor location.

Male	4
Female	2
Age (years)-median	68
BMI-median	25
Comorbidity	4
History of abdominal surgery	3
Tumor location	
Low <6 cm	4
Mid 6–11 cm	2
Pre QRT	4
Rullier classification	
Type I	4
Type II	1
Type IV	1

(Table 2). Pathological TNM stage was II in 2, III in 2 and IV in 2 patients. The median number of lymph nodes harvested was 22 (7–38). The distal (>2 cm) and circumferential margins (>1 mm) were negative in all specimens. R0 resection was obtained in all cases. Macroscopic grading of quality of the total mesorectum excision was complete in five and nearly complete in one specimen (Table 2).

Discussion

The general consensus has been that most rectal adenocarcinomas located in the distal portion of the rectum (<5 cm from the anal border) should be treated by abdominoperineal

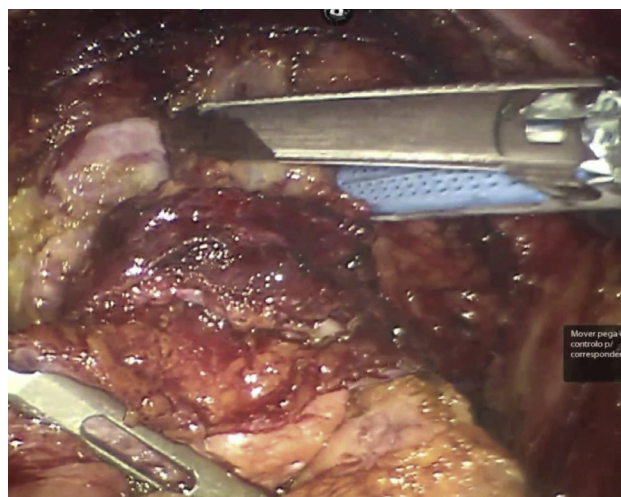


Fig. 6 – Division of the rectum using an endorectal stapler.

resection (APR) of the rectum.¹² However, with better knowledge of the importance not only of the circumferential resection margin, but also of total mesorectal excision (TME),¹³ currently added to the routine use of neoadjuvant chemoradiotherapy (CRT),¹⁴ new surgical techniques for sphincter preservation have been disseminated. The individualization of the best surgical procedure, which is facilitated by the pelvic magnetic resonance imaging (MRI) examination,¹⁵ has recently been supported by Rullier et al.,¹¹ who proposed

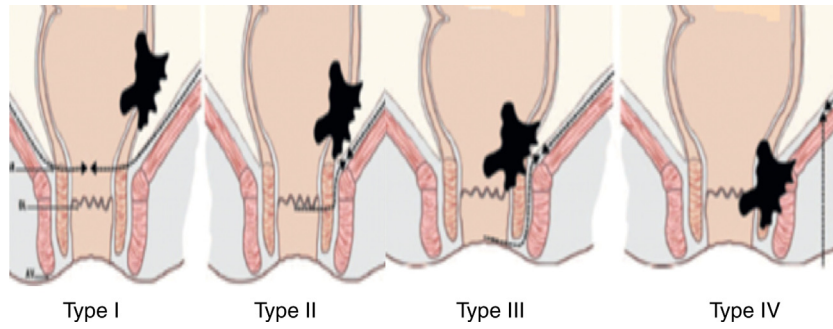


Fig. 7 – Low rectal cancer: Rullier's classification (4).

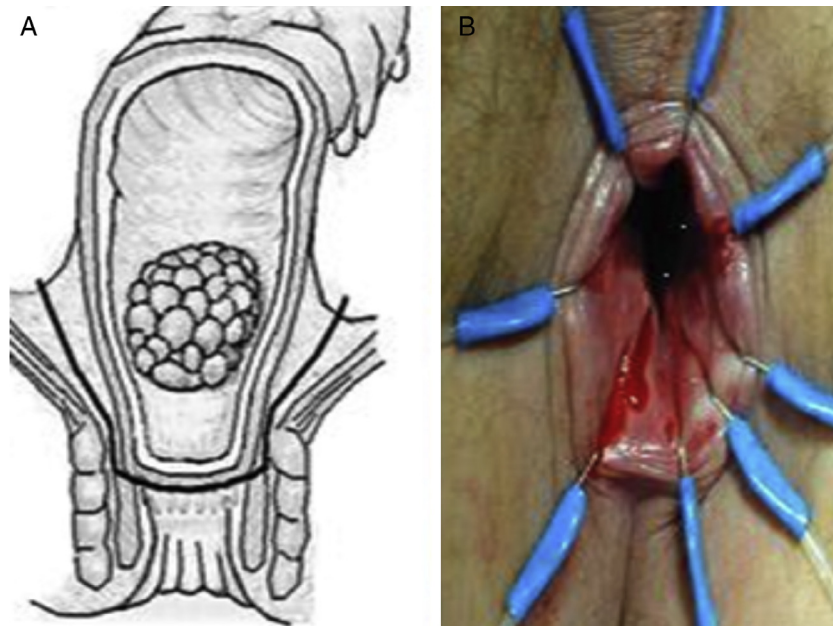


Fig. 8 – Plane for the intersphincteric resection and latero-to-end hand sewn coloanal anastomosis.

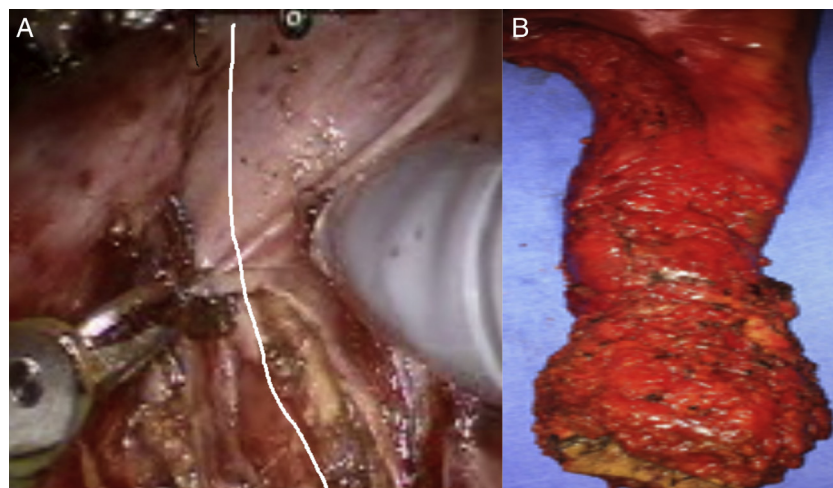


Fig. 9 – Cylindrical abdominoperineal resection. (A) Transabdominal section of the levator muscles in U shape. (B) Postoperative specimen.

Table 2 – Surgical and pathological outcomes.

LAR	2
ULAR-coloanal anastomosis	2
RAP cylindrical	1
Partial ISR	1
Diverting loop ileostomy	2
Conversion	0
Intraoperative complication	1
Operative time-median	245 min
Console time-median	170
Postoperative complication	1 (16%)
Length of stay-median	6
TNM	
Stage II	2
Stage III	2
Stage IV	2
Number of lymph nodes-median	22
Distal and circumferential negative margins	6
Mesorectum grade	
Complete	5
Nearly complete	1

a classification divided into 4 types of tumors (Supra-anal, juxta-anal, intra-anal and transanal) and, respectively, 4 types of surgical procedures (Ultra-Low Anterior Resection, Partial intersphincteric resection, Total IR and APR). The personalization of cylindrical abdominoperineal resection of the rectum was also recently proposed by Han et al.,¹⁶ who selected the extent of surgery according to the invasion of the elevator muscles of the anus.

One of the main advantages of the robotic system is that the surgeon controls a stable 3DHD camera that enhances depth perception and promotes clear visibility of the operative field. The stable and magnified view allows precise identification of the hypogastric plexus nerves, for instance, and tremor filtration minimizes the risk of injury to anatomical structures during dissection. The several multiarticulated instruments (180°) with high mobility of rotation (540°) allow the surgeon to perform complex movements and make an excellent exposure of the surgical field using the benefits of the third arm.

Hemostasis can be meticulous and precise. Additionally, in the robotic platform the surgeon is ambidextrous and can operate the console comfortably seated with excellent ergonomics and thus, physical stress is very small. The da Vinci system currently offers the articulated sealer (Vessel Sealer), the articulated endostapler (EndoWrist Stapler) and fluorescence imaging ("Firefly") to evaluate perfusion of the lowered colon and rectal stump.

Although the robotic arms do not transmit tactile sensation and traction tension in tissues or sutures, the excellent vision is sufficient to prevent injuries to the main structures (vessels, nerves, ureter, intestines), especially after surpassing the learning curve. The change of position of the patient, as well as redocking of the robot is an inconvenient factor only by prolonging the operative time by 5–10 min. However, the total cost of the robotic system and tools is still the main problem at the moment.

Basically 3 types of robotic techniques can be used for rectal cancer surgery. When using the hybrid technique, the robot is only used to perform total mesorectal excision; the

mobilization of the left colon and upper rectum and ligation of the inferior mesenteric vessels are performed laparoscopically. In the multiple docking technique, the robot can be docked/undocked 2 or 3 times. The devascularization, mobilization of the left colon and TME are carried out entirely by robotic means; in the single docking technique, the operation is also performed entirely by the robot. The surgeon chooses one of the techniques according to their experience.

One of the main reasons for conversion of laparoscopic surgery in rectal cancer is the technical difficulty in pelvic dissection of distal rectum tumors in male patients, obese individuals and those that have been treated with neoadjuvant CRT (conversion rate of 15–29%.^{17,18} Therefore, the learning curve is long and the number of patients needed is high (50 cases).¹⁹ Bokhari et al.⁷ and Jimenez et al.²⁰ reported shorter learning curves in robotic surgery and a smaller number of patients for the surgeon to achieve a high level of competence (15–25 cases). Baek et al.⁸ reported lower rates of conversion of robotic surgery when compared with laparoscopic ones in ultralow rectal resections (16.2 vs. 2.1% $p = 0.02$). The same was confirmed by Yang et al.²¹ in a meta-analysis study ($p < 0.001$). Conversion is directly related to a higher rate of postoperative complications (45%) and mortality (9%).¹⁸

When using the robotic system, the precise dissection in the avascular space in the mesorectal excision (Holly plane) not only improves the quality of excision but also provides greater number of surgical specimens with a degree of complete excision, especially in anterior ultralow rectal resections.^{22,23} In the CLASSIC study,¹⁸ the positive circumferential resection margin (CRM) was 12% in the laparoscopic group. Baik et al.⁹ showed a significant difference ($p = 0.033$) in the degree of mesorectal excision when comparing robotic low anterior resection (LAR) (56 patients) and laparoscopic resection (57 patients). Due to the optimal exposure and view of pelvic structures, the preservation of the pelvic plexus nerves is superior and, consequently, urinary and sexual functional results are better as demonstrated by Luca et al.²⁴ and D'Annibale et al.²⁵

Recent nonrandomized studies showed a higher incidence of anastomotic fistula in anterior resections, especially in ultralow resections performed through laparoscopy and a lower incidence when performed through robotic techniques (13–15% vs. 3–6%).^{17,26–27}

The worst oncological outcomes of the conventional abdominoperineal resection of the rectum seem to be related to a higher incidence of rectal or tumor perforation and positive circumferential margin found in surgical specimens. To minimize these results Holm et al.²⁸ proposed the extralevator abdominoperineal excision (ELAPE) or cylindrical (CAPE), which consists of the perineal excision of the elevators in the supine position (jackknife position). In a review in 5244 cases, Stelzner et al.²⁹ showed a lower rate of positive CRM (9.6% vs. 15.4%, $p = 0.022$) and perforation (4.1% vs. 10.4%, $p = 0.004$) in the cylindrical resection group. The incidence of local recurrence was lower (6.6% vs. 11.9%, $p < 0.001$). Marecik et al.³⁰ prefer the lithotomy position and the robotic access for the sectioning of the elevator muscles of the anus by abdominal approach. We prefer to individualize each surgical procedure and follow the recommendations of Han et al.,³¹ who recommend less extensive procedures according to the topography

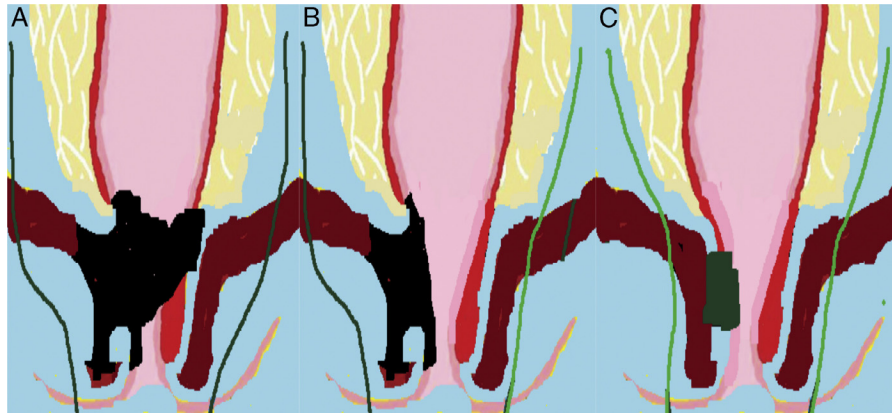


Fig. 10 – Individual cylindrical APR technique according to Han and colleagues. (A) Bilateral extralevator APR. (B) Unilateral EAPR. (C) Conventional APR.

and size of the tumor, and invasion of the elevator muscles (Fig. 10) selected by pelvic magnetic resonance, as rates of perineal complications, mainly due to chronic pelvic pain and perineal hernia, are very high (>50%) and the closure of the perineal wound is much more complex (flap rotation, mesh placement).

The six patients undergoing surgery for cancer of the distal rectum in the Robotic Surgery Service of Hospital Samaritano, RJ used the daVinci SI robotic system. There was no conversion or positive CRM in this group and only one postoperative complication (ileus). Ileostomy was not performed in 3 patients (2 coloanal and 1 partial IR). The mean time to hospital discharge was six days.

Currently, the indication for this new minimally invasive technology in the treatment of rectal cancer seems to benefit mainly male patients, obese individuals and those who have been treated with preoperative chemoradiotherapy. The excellent quality of mesorectal dissection associated with excellent vision and pelvic surgical field exposure observed in this initial experience will translate into a low conversion rate and positive CRM, and perhaps a lower incidence of anastomotic fistula, even without the performance of routine ileostomy.

We await with great interest the final results of the international, multicenter, randomized trial ROLARR³² to evaluate the level of evidence and grade of recommendation of robotic surgery for the treatment of rectal cancer.

Conclusion

Standardized robotic rectal surgery is a promising alternative to treat patients with mid or low rectal cancer and is expected to overcome the low penetration rate of laparoscopic surgery in this field. This technique was successfully performed in six patients with excellent immediate postoperative and pathological results. Additional studies in a large series of patients are necessary to confirm those advantages.

Conflicts of interest

The authors declare no conflicts of interest.

REFERENCES

- Jayne DG, Thorpe HC, Copeland J, Quirke P, Brown JM, Guillou PJ. Five-year follow-up of the Medical Research Council CLASICC trial of laparoscopically assisted versus open surgery for colorectal cancer. *Br J Surg*. 2010;97:1638–45.
- Kang SB, Park JW, Jeong SY, et al. Open versus laparoscopic surgery for mid or low rectal cancer after neoadjuvant chemoradiotherapy (COREAN trial): short-term outcomes of an open-label randomised controlled trial. *Lancet Oncol*. 2010;11:637–45.
- van der Pas MH, Haglind E, Cuesta MA, et al. Laparoscopic versus open surgery for rectal cancer (COLOR II): short-term outcomes of a randomized, phase 3 trial. *Lancet Oncol*. 2013;14:210–8.
- Arezzo A, Passera R, Scozzari G, Verra M, Morino M. Laparoscopy for rectal cancer reduces short-term mortality and morbidity: results of a systematic review and meta-analysis. *Surg Endosc*. 2013;27:1485–502.
- Halabi WJ, Kang CY, Jafari MD, et al. Robotic-assisted colorectal surgery in the United States: a nationwide analysis of trends and outcomes. *World J Surg*. 2013.
- Zang Y, Wang F, Zhang P, Sou Y, Qin H, Ma Y. Robotic-assisted versus conventional laparoscopic surgery for colorectal disease, focusing on rectal cancer: a meta-analysis. *Ann Surg Oncol*. 2012;19:3727–36.
- Bokhari MB, Patel CB, Ramos-Valadez DI, Ragupathi M, Haas EM. Learning curve for robotic-assisted laparoscopic colorectal surgery. *Surg Endosc*. 2011;25:855–60.
- Baek SJ, Al-Asari S, Jeong DH, et al. Robotic versus laparoscopic coloanal anastomosis with or without intersphincteric resection for rectal cancer. *Surg Endosc*. 2013.
- Baik SH, Kwon HY, Kim JS, et al. Robotic versus laparoscopic low anterior resection of rectal cancer: short-term outcome of a prospective comparative study. *Ann Surg Oncol*. 2009;16:1480–7.
- Ramos JR, Parra-Dávila E. Four-arm single docking full robotic surgery for low rectal cancer: technique standardization. *Rev Col Bras Cir*. 2014.
- Rullier E, Denost Q, Vendrely V, Rullier A, Laurent C. Low rectal cancer: classification and standardization of surgery. *Dis Colon Rectum*. 2013;56:560–7.
- Miles EW. A method of performing abdominoperineal excision for carcinoma of the rectum and of the terminal portion of the pelvic column. *Lancet*. 1908;2:1812–3.

13. MacFarlane JK, Ryall RD, Heald RJ. Mesorectal excision for rectal cancer. *Lancet*. 1993;341:457-60.
14. Habr-Gama A, Sabbaga J, Gama-Rodrigues J, et al. Watch and wait approach following extended neoadjuvant chemoradiation for distal rectal cancer: are we getting closer to anal cancer management? *Dis Colon Rectum*. 2013;56:1109-17.
15. Nougaret S, Reinhold C, Mikhael HW, Rouanet P, Bibeau F, Brown G. The use of MR Imaging in treatment planning for patients with rectal carcinoma: have you checked the "DISTANCE"? *Radiology*. 2013;268:330-44.
16. Han JG, Wang ZJ, Wei GH, et al. Technical improvements and results of individual cylindrical abdominoperineal resection for locally advanced low rectal cancer. *Zhonghua Wai Ke Za Zhi*. 2013;51:335-8.
17. Rottoli M, Bona S, Rosati R, et al. Laparoscopic rectal resection for cancer: effects of conversion on short-term outcome and survival. *Ann Surg Oncol*. 2009;16:1279-86.
18. Guillou PJ, Quirke P, Thorpe H, et al. MRC CLASICC trial group Short-term endpoints of conventional versus laparoscopic-assisted surgery in patients with colorectal cancer (MRC CLASICC trial): multicentre, randomised controlled trial. *Lancet*. 2005;365:1718-26.
19. Kayano H, Okuda J, Tanaka K, Kondo K, Tanigawa N. Evaluation of the learning curve in laparoscopic low anterior resection for rectal cancer. *Surg Endosc*. 2011;25:2972-9.
20. Jiménez-Rodríguez RM, Díaz-Pavón JM, de la Portilla de Juan F, Prendes-Sillero E, Dussort HC, Padillo J. Learning curve for robotic-assisted laparoscopic rectal cancer surgery. *Int J Colorectal Dis*. 2013;28:815-21, 27:4157-63.
21. Yang Y, Wang F, Zhang P, et al. Robot-assisted versus conventional laparoscopic surgery for colorectal disease, focusing on rectal cancer: a meta-analysis. *Ann Surg Oncol*. 2012;19:3727-36.
22. Baik SH, Kim NK, Lim DR, Hur H, Min BS, Lee KY. Oncologic outcomes and perioperative clinicopathologic results after robotic-assisted tumor-specific mesorectal excision for rectal cancer. *Ann Surg Oncol*. 2013.
23. Kang J, Yoon KJ, Min BS, et al. The impact of robotic surgery for mid and low rectal cancer: a case-matched analysis of a 3-arm comparison-open, laparoscopic, and robotic surgery. *Ann Surg*. 2013;257:95-101.
24. Luca F, Valvo M, Ghezzi TL, et al. Impact of robotic surgery on sexual and urinary functions after fully robotic nerve-sparing total mesorectal excision for rectal cancer. *Ann Surg*. 2013;257:672-8.
25. D'Annibale A, Pernazza G, Monsellato I, et al. Total mesorectal excision: a comparison of oncological and functional outcomes between robotic and laparoscopic surgery for rectal cancer. *Surg Endosc*. 2013.
26. Zeng DZ, Shi Y, Lei X, et al. Short-term efficacy of da Vinci robotic surgical system on rectal cancer in 101 patients. *Zhonghua Wei Chang Wai Ke Za Zhi*. 2013;16:451-4.
27. deSouza AL, Prasad LM, Marecik SJ, et al. Total mesorectal excision for rectal cancer: the potential advantage of robotic assistance. *Dis Colon Rectum*. 2010;53:1611-7.
28. Holm T, Ljung A, Haggmark T, Jurell G, Lagergren J. Extended abdominoperineal resection with gluteus maximus flap reconstruction of the pelvic floor for rectal cancer. *Br J Surg*. 2007;94:232-8.
29. Stelzner S, Koehler C, Stelzner J, Sims A, Witzigmann H. Extended abdominoperineal excision vs. standard abdominoperineal excision in rectal cancer – a systematic overview. *Int J Colorectal Dis*. 2011;26:1227-40.
30. Marecik SJ, Zawadzki M, Desouza AL, Park JJ, Abcarian H, Prasad LM. Robotic cylindrical abdominoperineal resection with transabdominal levator transection. *Dis Colon Rectum*. 2011.
31. Han JG, Wang ZJ, Wei GH, Gao ZG, Yang Y, Zhao BC. Randomized clinical trial of conventional versus cylindrical abdominoperineal resection for locally advanced lower rectal cancer. *Am J Surg*. 2012;204:274-82.
32. Collinson FJ, Jayne DG, Pigazzi A, et al. An international, multicentre, prospective, randomised, controlled, unblinded, parallel-group trial of robotic-assisted versus standard laparoscopic surgery for the curative treatment of rectal cancer. *Int J Colorectal Dis*. 2012;27:233-41.