



Journal of Coloproctology

www.jcol.org.br



History article

A new method of colorectal anastomosis in abdominoperineal resection[✧]

Um novo método de anastomose colorretal em ressecção abdominoperineal

Daher E. Cutait[†], Felipe José Figliolini^{††}

Department of Surgery, Medical School of the University of São Paulo, São Paulo, Brazil

ABDOMINOPERINEAL rectosigmoidectomy is, at present, considered the operative method of choice for treatment of megacolon. This operation is based on the pathogenic basis of dyskinesia of the distal portion of the intestine. According to this theory, dilatation of the sigmoid flexure results from lack of the propulsive function of the rectum and sometimes also of the sigmoid flexure, due to defective contraction of its muscular fibers. The defective contraction is caused by agenesis of the Auerbach's myenteric plexus in Hirschsprung's disease and by inflammatory lesions in the acquired megacolon that cause partial or total destruction of the Auerbach's myenteric plexus. To remedy this condition, removal of the diseased, as well as the dilated portion of colon, with immediate re-establishment of bowel continuity by colorectal anastomosis, seems therefore to be a rational surgical procedure. This is why rectosigmoidectomy has been performed by most experienced surgeons all over the world. Notwithstanding its effectiveness, there are some restrictions owing to the high incidence of postoperative complications, most of which are due to disruption, of varying degrees, of the colorectal anastomosis. In Hirschsprung's disease disruption is rather rare, but in acquired megacolon it is encountered in a large number of cases. In Raia and Haddad's¹ 158 patients with acquired megacolon who underwent rectosigmoidectomy, this complication was encountered in 67 cases (42.4 per cent) and in our series of 222 patients it was noted in more than 30 per cent. In our

experience, proximal colostomy, may reduce the hazard of disruption, but it does not prevent it.

Leakage of the anastomosis is usually accompanied by infection of the presacral space. In such cases purulent discharges should be drained through a rubber tube introduced through a stab wound at the anococcygeal line or they may be drained into the peritoneal cavity. This complication may be followed by an infected perineal stercoral fistula or peritonitis, respectively.

When disruption of the anastomosis produces a sinus, healing occurs spontaneously in the majority of cases. On a fair number of patients, however, it is necessary to perform corrective operations, such as enlargement of the perineal drainage area or fistulectomy, either of which usually gives poor results. Obviously the results are worse when the disruption is larger. Stenosis, anal incontinence and permanent infection may follow disruption of the anastomosis, requiring the patient to continue permanently with the proximal colostomy.

In order to lessen the incidence of disruption and to obviate its harmful effects after abdominoperineal rectosigmoidectomy, we devised and began to perform a new technic of colorectal anastomosis in 1959. This method is based on the principle of "adhesion by contact between the muscular surface of the everted rectum and the serosa surface of the pulled colon, and in the suture of the mucosa coat of the rectum to the mucosa coat of the colon" (primary-secondary colorectal anastomosis). ~ge feel that the gratifying results obtained by this technic justify presentation of this report.

[✧]Republication of the historical article of *Diseases of the Colon & Rectum: Cutait DE, Figliolini FJ. A new method of colorectal anastomosis in abdominoperineal resection. Diseases of the Colon & Rectum. 4(5):335-342, September/October 1961. Read at the meeting of the American Proctologic Society, Pittsburgh, Pennsylvania, June 21 to 24, 1961.*

[†] Head of the group in charge of colorectal surgery (Professor Eurico da Silva Bastos).

^{††} Assistant Professor..

* Corresponding author.

E-mail: editorchefe@jcol.org.br (A. da Luz Moreira)

2237-9363 © 2013 Elsevier Editora Ltda. Este é um artigo Open Access sob a licença de [CC BY-NC-ND](https://creativecommons.org/licenses/by-nc-nd/4.0/)

<http://dx.doi.org/10.1016/j.jcol.2013.12.003>

Technic

Our new method of anastomosis is performed in two stages as follows:

First Stage: After dissection of the sigmoid flexure and the rectum down to the level of the levator ani muscles and identifying, with a cotton stitch, the appropriate level of division of the sigmoid flexure (Fig. 1) to be made during the perineal phase of the operation, an obturator of a sigmoidoscope is introduced through the anus and passed up to the proximal limit of the rectum (Fig. 2). The obturator is fixed at this level with a heavy silk ligature and used to apply gentle traction. This traction easily effects complete eversion or intussusception, through the anus, of the entire rectum and lower segment of the sigmoid flexure (Fig. 3).

The everted rectal wall is grasped with an Allis clamp and an incision is made with scissors around the entire circumference of the rectum at a level approximately 2 to 3 cm. from the pectinate line (Figs. 4 and 5). The bowel is then pulled out through the anus as far as the level previously marked by the cotton stitch, which is situated about 6 cm. beyond the border of the everted rectum (Fig. 6). A heavy silk ligature is applied to the colon at this level and the colon is divided distal to it (Fig. 7).

The sigmoid flexure is then attached to the everted rectum by means of four stitches applied anteriorly, posteriorly and laterally (Fig. 8). The stitches are introduced into the seromuscular coat of the sigmoid flexure and to the muscular

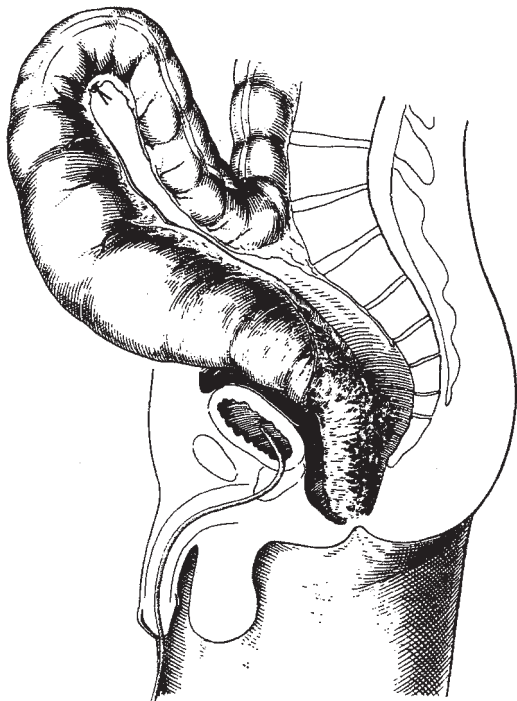


Fig. 1 - Sigmoidorectal segment dissected down to the anus in the abdominal phase of the operation. Stitch shows the level where the sigmoid is to be divided in the perineal phase of the operation.

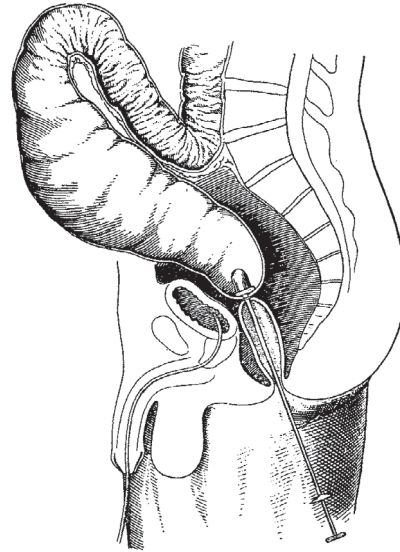


Fig. 2 - Obturator of a sigmoidoscope introduced through the anus and fixed at the proximal level of the rectum by a heavy silk ligature.

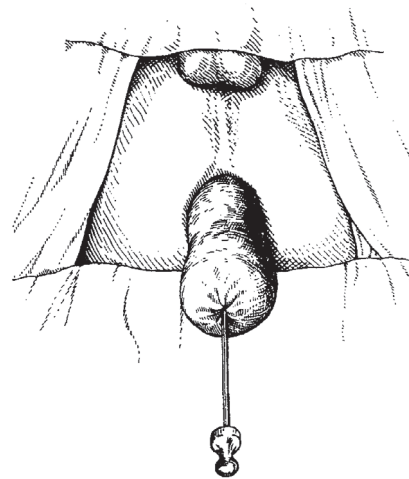


Fig. 3 - Rectum everted by traction on the obturator.

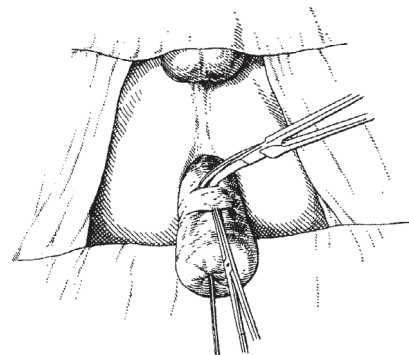


Fig. 4 - Allis clamp attached and incision of the rectal wall begun.

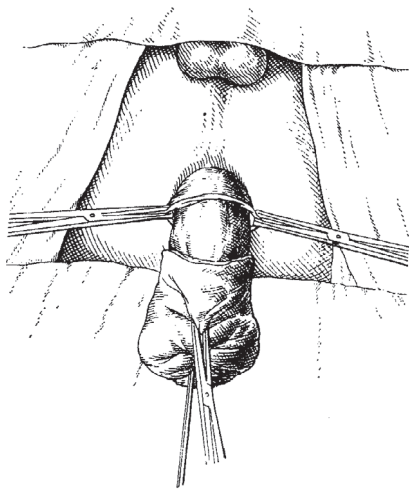


Fig. 5 - Incision of the rectal wall completed.

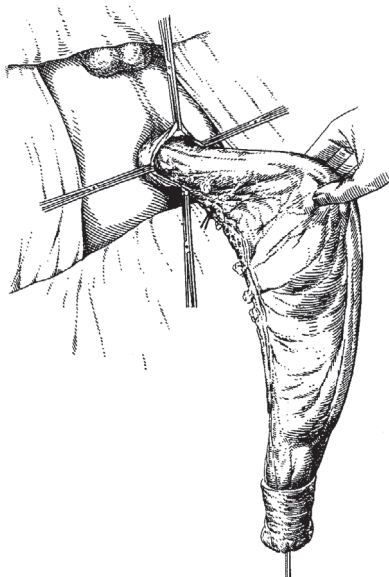


Fig. 6 - Sigmoid pulled out through the anus to the level previously marked by the stitch.

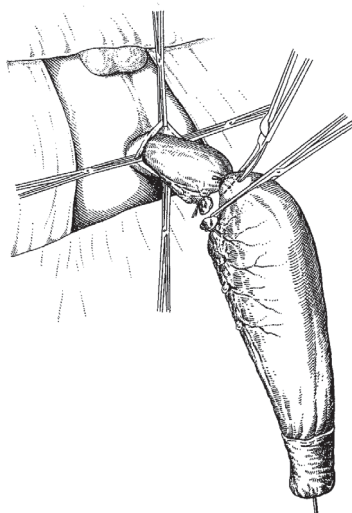


Fig. 7- Ligation and division of the sigmoid flexure.

coat of the rectum. The two lateral stitches are then transfixed and attached to the perineal skin about 2.5 cm. from the pectinate line and the sigmoidorectal stump is covered with vaseline gauze (Fig. 9). This prevents retraction of this stump.

While the perineal phase of the operation is being performed, the assistants, who have remained at the abdominal field, reconstruct partially the pelvic peritoneal floor and close the abdominal wound. Maintenance of a communication between the pelvic and peritoneal cavities facilitates drainage and absorption by the peritoneum of the residual blood in the pelvic cavity. The fixation skin stitches and the sigmoidal ligature are cut the next day. The pulled-through colonic segment then starts to act as a temporary perineal colostomy.

Second Stage: The second stage is usually performed seven to 10 days after the first. The interval of seven to 10 days is sufficient for perfect adhesion between the muscular coat of the everted rectum and the serosal surface of the pulled-through portion of the colon (Figs. 10 and 11). This phase of the operation can be performed in 15 to 90 minutes and does not require anesthesia.

After the vaseline gauze dressing is removed, the colon is grasped with an Allis clamp and incised with a knife at the level of the border of the everted rectum, around its entire circumference. The incision is made as deep as the mucosa only (Fig. 12). The mucosa is dissected downward for about 0.5 cm. It is then divided with scissors all around the distal limit of the dissection (Fig. 13). The mucosa of the rectum is then sutured to the mucosa of the sigmoid flexure with interrupted cotton sutures (Figs. 14, 15, 16 and 17). Upon completion of the anastomosis, the rectum is forced through the anus with the index finger (Figs. 18 and 19). The patient leaves the hospital two days later.

The rectosigmoidectomy and colorectal anastomosis just described was performed on 40 patients with acquired megacolon.

In six cases the operation was performed on patients with previous transverse colostomy performed simultaneously with detorsion of volvulus of the sigmoid flexure.

In two cases transverse colostomy was performed simultaneously with the rectosigmoidectomy and on the remaining 32 cases no proximal colostomy was established. On the first 20 patients of this series perineal drainage of the presacral space was established through a rubber tube drain. Due to the fact that in none of these cases did disruption of the anastomosis occur, it was felt that this type of drainage could be abandoned. In such cases there was an accumulation of uninfected serosanguineous liquid in the presacral space which could be drained into the peritoneal cavity. In order to facilitate this arrangement the peritoneal pelvic floor should be closed only partially.

Based on the experience acquired in the management of patients of this series, we perform, at present as a routine procedure, rectosigmoidectomy with the colorectal anastomosis that we have described, without establishment of a proximal colostomy and without perineal drainage of the presacral space. We feel that the results obtained by employing the new technic of colorectal anastomosis justify the procedure.

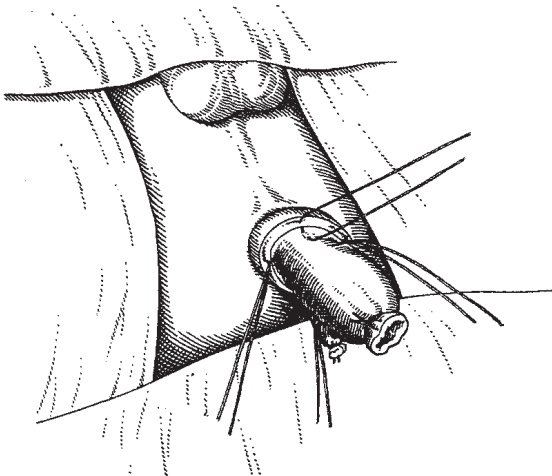


Fig. 8 - Fixation of the sigmoid flexure to the everted rectum by means of four stitches applied to the muscular coat of the rectum and to the seromuscular coat of the sigmoid flexure.

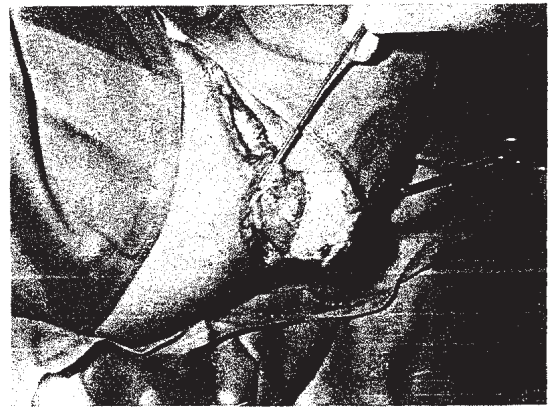


Fig. 11 - Sigmoidorectal stump on the ninth postoperative day. The mucosa of the everted rectum and the serosa of the pulled-through portion of the sigmoid are covered by a serofibrinopurulent exudate. The probe marks the pectinate line.

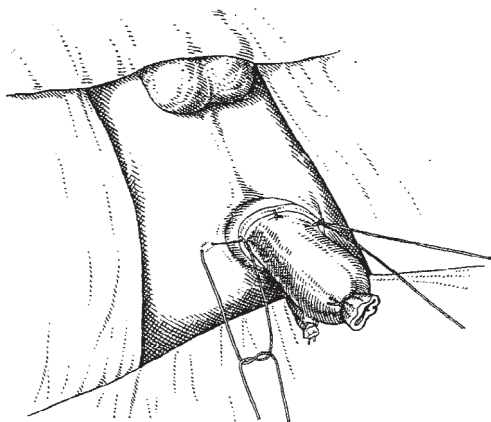


Fig. 9 - Transfixation of the two lateral stitches to the perineal skin.

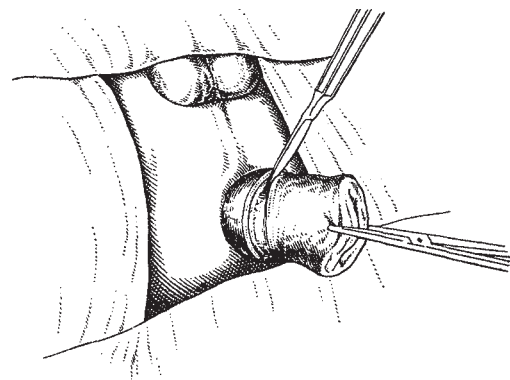


Fig. 12 - Incision of the sigmoid flexure at the level of the border of the everted rectum. The incision is made as deep as the mucosa and the mucosa is dissected downward for a distance of 1/2 cm.

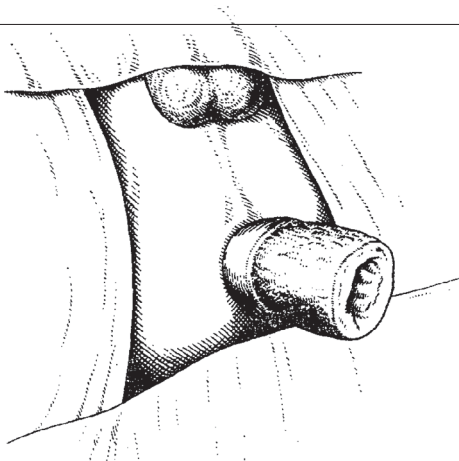


Fig. 10- Appearance of the sigmoidorectal stump several days after the operation. The muscular coat of the everted rectum is firmly adherent to the serosal coat of the pulled-through portion of the bowel.

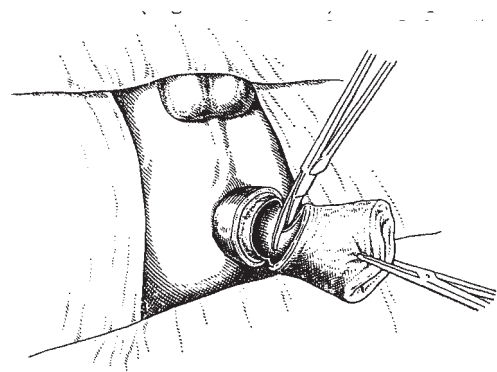


Fig. 13 - Division of the mucosa of the sigmoid flexure.

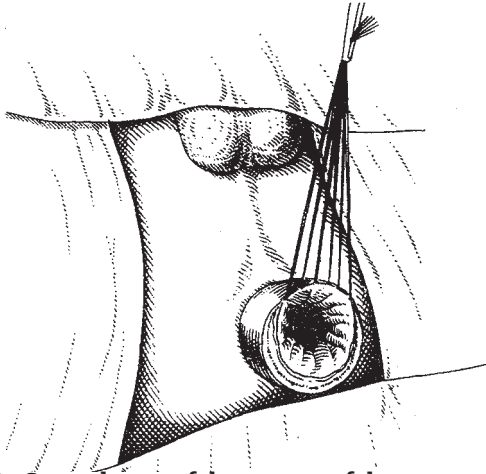


Fig. 14 - Suture begun of the mucosa of the rectum to the mucosa of the sigmoid flexure with interrupted cotton sutures.

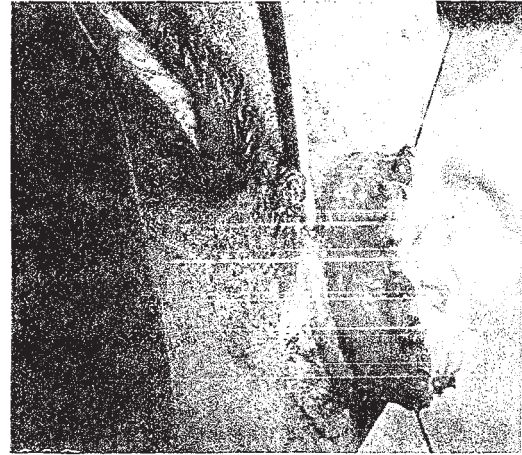

Fig. 17 - The sigmoidorectal stump, after completion of the suture (lateral view).

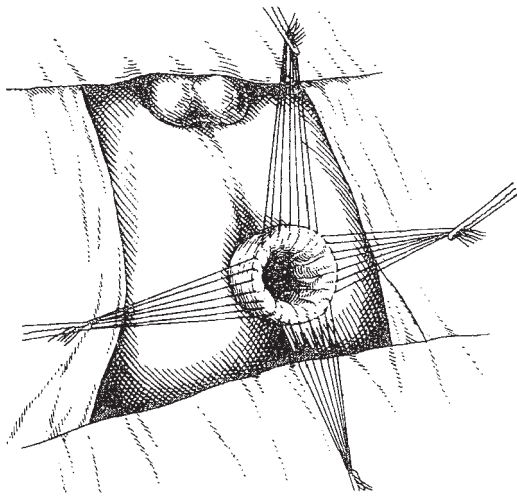


Fig.15 - Suture completed.

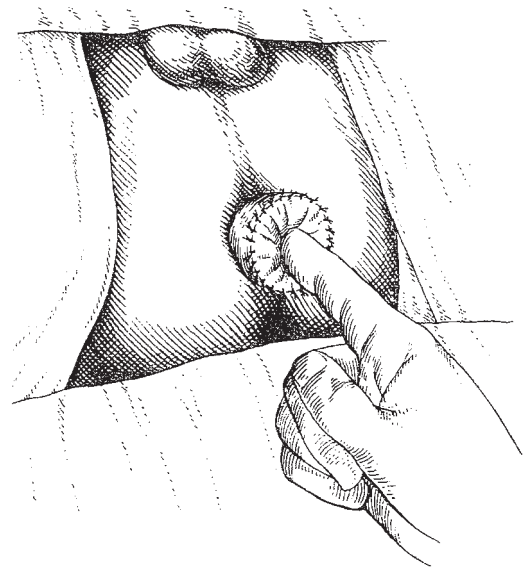


Fig.18 - Reduction of the everted rectum by forcing it in with the index finger.

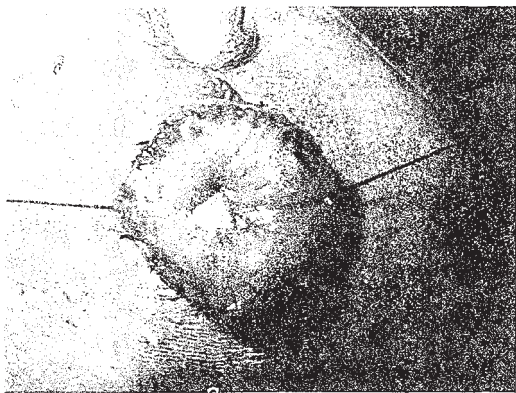


Fig. 16 - The sigmoidorectal stump, after completion of the suture (frontal view).

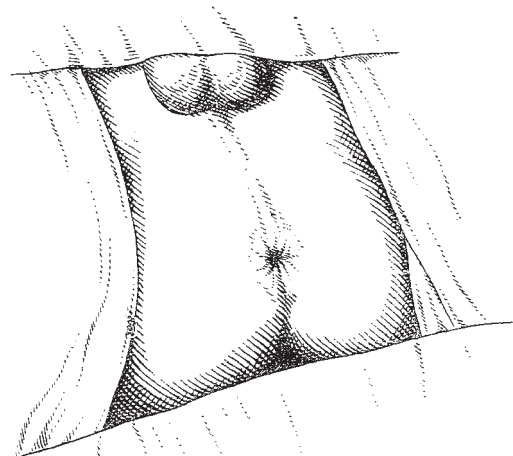


Fig. 19 - Final appearance of the rectal outlet.

Results

Disruption of the colorectal anastomosis occurred in only one case, an incidence of 2.5 per cent. This incidence of disruption is significantly lower than that noted in the conventional type of anastomosis (Table 1). The only disruption that occurred was in a patient who developed pseudomembranous enteritis after operation. In this case transverse colostomy had to be performed. Integrity of the suture line was demonstrated by endoscopic examination in all other cases.

Table 1 – Disruption of colorectal anastomosis: comparative results.

Type of colorectal anastomosis	Cases, number	Number of cases of disruption of anastomosis	Percent
Primary colorectal anastomosis	222	70	31.5
Primary-secondary colorectal anastomosis	40	1	2.5

Infection of the presacral space was noted in three patients. In the first the infection was due to disruption of the anastomosis; in the second infection followed laceration of the vaginal wall that occurred while performing the dissection incidental to removal of the rectum, and in the third case, infection occurred after a new pull-through procedure which was performed after the occurrence of necrosis of the intestine. As we have said, in only one case was infection related to imperfection of the anastomosis.

Stenosis of the anastomosis did not occur in any case. In some patients a diaphragmatic ring could be noted early in the postoperative period. However, these contractures subsided in all cases in about two or three weeks. Almost all patients had anal incontinence during the early period after operation, the bowel movements numbering five to 15 daily. This trouble, however, subsided within a few weeks.

There was one death in our series (2.5 per cent), which is significantly lower than the mortality rate of the conventional type of anastomosis (6.8 per cent; Table 2). It occurred in the patient who had necrosis of the pulled-through colon. This

Table 2 – Mortality rate of colorectal anastomosis: comparative results.

Type of colorectal anastomosis	Cases, number	Deaths	Percent
Primary colorectal anastomosis	222	15	6.8
Primary-secondary colorectal anastomosis	40	1	2.5

patient underwent the new colon pull-through operation, but developed a serious presacral infection which required perineal drainage. After cessation of the drainage the patient died suddenly. Necrolz_{sy} revealed the presacral infection, but the actual cause of death could not be determined. Probably this was due to cardiac arrest which has been observed in some patients with Chaga's disease.

In view of the gratifying results obtained with this new method of colorectal anastomosis, we employed it recently on five cases requiring abdominoperineal rectosigmoidectomy for cancer of the upper rectum and rectosigmoidal area. No anastomotic leakage occurred in these patients.

Summary and conclusions

A new technic of colorectal anastomosis in abdominoperineat rectosigmoidectomy is presented.

Justification of this technic is based on the principle of "adhesion by contact between the muscular surface of the everted rectum and the serosa surface of the pulled colon, and in the suture of the mucosa coat of the rectum to the mucosa coat of the colon." The anastomosis is performed in two stages.

The results obtained on 40 patients with acquired megacolon and on five with cancer of the rectum and rectosigmoid are described.

There was a gratifying reduction in the incidence of disruption of the anastomosis.

REFERENCE

1. Raia, A. and J. Haddad: Complicações da retossigmoidectomia abdomino-perineal. Paper presented to the First Latin-American, Second International and Tenth Brazilian Congress of Proctology, S-o Paulo, Brazil, September 1960.