



# Journal of Coloproctology

www.jcol.org.br



## Case reports

# Endoscopic management of anastomotic bleeding in the ileal pouch with staples removal and clipping

Xian-rui Wu<sup>a,b</sup>, Nan Lan<sup>b</sup>, Bo Shen<sup>c,\*</sup>

<sup>a</sup>Department of Colorectal Surgery, the Cleveland Clinic Foundation, Cleveland, USA

<sup>b</sup>Department of Colorectal Surgery, the Sixth Affiliated Hospital, Sun Yat-sen University, Guangzhou, China

<sup>c</sup>Department of Gastroenterology/ Hepatology, the Cleveland Clinic Foundation, Cleveland, USA

### ARTICLE INFO

#### Article history:

Received 4 February 2013

Accepted 1 March 2013

#### Keywords:

Ileal pouch anal anastomosis

Bleeding

Pouchoscopy

### ABSTRACT

**Objective:** Postoperative pouch bleeding is a rare but detrimental complication following ileal pouch surgery. It is usually self-limited, however continuous bleeding requires intervention. There is limited published data on its management.

**Design:** Ileoscopy via stoma for loop ileostomy and pouchoscopy via anus for ileal pouch were performed under sedation for the purpose of diagnosis and management of postoperative bleeding.

**Results:** Ileoscopy demonstrated a large, long blood clot in the lumen of efferent limb, but no sign of active bleeding was identified. Pouchoscopy showed that lumen of pouch body as well as afferent limb was filled with maroon-colored liquid stool. Pouch and neo-terminal ileum mucosa was normal. Two dislodged staples at the anastomotic line with sharp tips towards the lumen were found, with activating bleeding at one site. The staples were removed by biopsy forceps, and active bleeding was successfully controlled by the deployment of one endoclip.

**Conclusions:** We reported the first case that postoperative pouch bleeding, which was caused by dislodged staples, was successfully managed by endoscopic removal of the staples combined with clipping.

© 2013 Elsevier Editora Ltda. Este é um artigo Open Access sob a licença de [CC BY-NC-ND](#)

## Abordagem endoscópica do sangramento anastomótico da bolsa ileal com a remoção dos grampos e clipagem

### RESUMO

**Objetivo:** O sangramento pós-operatório da bolsa ileal é uma complicação rara, mas prejudicial após abordagem cirúrgica da bolsa ileal. Esse sangramento é geralmente autolimitado, porém, requer intervenção quando contínuo. Não há dados publicados sobre o tratamento. **Método:** Ileoscopia através de estoma para ileostomia em alça e endoscopia via ânus para a bolsa ileal foram realizadas sob sedação para diagnóstico e tratamento do sangramento pós-operatório.

#### Palavras-chave:

Anastomose íleo-anal com bolsa ileal

Sangramento

Endoscopia da bolsa ileal

\* Corresponding author.

E-mail: shenb@ccf.org (B. Shen)

**Resultados:** A ileoscopia demonstrou um grande e longo coágulo sanguíneo no lúmen do ramo eferente, mas nenhum sinal de sangramento ativo foi identificado. A endoscopia da bolsa ileal mostrou que os lumens do corpo da bolsa e ramo aferente estavam cheios de fezes líquidas de cor marrom. A bolsa e a mucosa do íleo neoterminal estavam normais. Dois grampos deslocados na linha da anastomose e com pontas afiadas em direção ao lúmen foram encontrados, com sangramento ativo em um dos locais. Os grampos foram removidos com pinça de biópsia e o sangramento ativo controlado com sucesso pela implantação de um endoclipse.

**Conclusão:** Relatamos o primeiro caso em que o sangramento pós-operatório da bolsa ileal causado por grampos deslocados foi controlado com sucesso pela remoção endoscópica dos grampos combinada com clipagem.

© 2013 Elsevier Editora Ltda. Este é um artigo Open Access sob a licença de [CC BY-NC-ND](https://creativecommons.org/licenses/by-nc-nd/4.0/)

## Introduction

Restorative proctocolectomy with ileal pouch-anal anastomosis (IPAA) has evolved into the surgical treatment of choice for patients with ulcerative colitis (UC) and familial adenomatous polyposis (FAP). Postoperative complications including mechanical/surgical, inflammatory and functional complications are common. Postoperative pouch bleeding is a rare but detrimental complication and there was limited published data on its management.<sup>1</sup> Here we reported on a 21-year-old female who developed pouch anastomotic bleeding following IPAA surgery for refractory UC and was successfully managed by removing the staples combined with endoscopic clipping.

## Case report

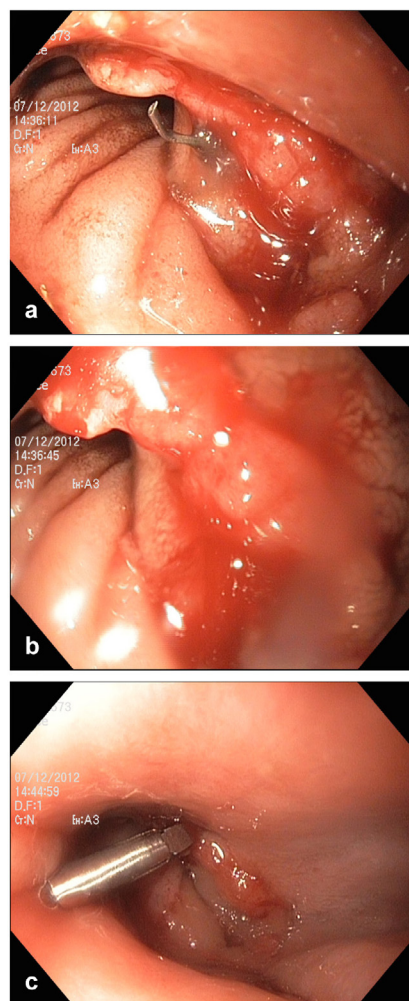
### The patient

The patient suffered from extensive UC for three years when she was referred to our institution for evaluation. Despite therapy with mesalamine, prednisone, azathioprine and infliximab, she developed medically refractory disease and underwent total proctocolectomy with IPAA and temporary loop ileostomy. Both surgery and hospitalization were uneventful; she was discharged on postoperative day 8.

Two weeks after the surgery, she started having bleeding per anus and stoma and 2 weeks later she was readmitted to our hospital. She also had mild right-sided abdominal discomfort. Her hemoglobin was 11.1 g/dL. Coagulation test was normal. She had persistent bleeding per anus and stoma and her hemoglobin continued to drop to 9.9 g/dL within 24 hours after admission. She refused to have blood transfusion.

Postoperative pouch bleeding was suspected. Ileoscopy via stoma for loop ileostomy and pouchoscopy were performed under sedation with a GIF-H180 gastroscope (Olympus, Tokyo, Japan). On ileoscopy via stoma, 20 cm of the afferent limb was intubated, which was normal and demonstrated no sign of bleeding. The efferent limb was also evaluated which showed a large, long blood clot in the lumen. Pouchoscopy via the anus showed that lumen of pouch body as well as afferent limb was filled with maroon-colored liquid stool. Pouch and neoterminal ileum mucosa was normal. We found two dislodged staples at the anastomotic line with sharp tips towards the lumen. There was activating bleeding at one site. The staples

were removed by biopsy forceps (Boston Scientific, Boston, MA, USA). Active bleeding was seen before and after the removal of one of the staples. We deployed one endoclip (Wilson-Cook, Winston-Salem, NC, USA) at the bleeding site (Fig. 1), which successfully controlled bleeding. The entire procedure took 25 minutes. The total dose of intravenous meperidine was 87.5 mg and midazolam 3 mg. The patient tolerated the procedure



**Fig. 1 – Pouch anastomotic bleeding: (a) before, (b) after the removal of the staples, and (c) one endoclip was deployed.**

well and the hemorrhage was stopped successfully. After the procedure, the patient continued to do well and showed no sign of active bleeding. Her hemoglobin was 10.3 g/dL and she was discharged next day after the procedure. The patient reported no recurrence of pouch bleeding at her most recent follow-up three months after the procedure.

## Discussion

Postoperative pouch bleeding was a rare complication following the IPAA surgery, with a reported prevalence rate of 1.5%.<sup>1</sup> The majority of bleeding occurred within one week after the surgery, and it could present as bleeding from either pouch site and/or stoma site. Multiple factors may contribute to the bleeding, including inadequate hemostasis, misfired staples, patients' underlying hematological disorders, and the use of postoperative anticoagulant. Studies showed that the stapled technique seemed to have a slightly higher rate of anastomotic bleeding than hand-sewn technique in non-pouch patients.<sup>2,3</sup> In this study, we reported a case of postoperative bleeding caused by a dislodged staple two weeks after the IPAA surgery with stapled anastomosis.

Postoperative pouch bleeding is usually self-limited. However, continuous bleeding requires intervention. It was reported that around 60% of continuous postoperative pouch bleeding required blood transfusion.<sup>1</sup> Regarding the management of pouch bleeding in the postoperative period, there was no standardized algorithm available in the literature. However, pouch endoscopy as both a diagnostic tool and a treatment maneuver was suggested. Treatment with epinephrine enema could be used when patients presented with diffuse bleeding, while endoscopic cauterization might be more effective when specific bleeding points could be identified. But there were two concerns when endoscopic cauterization was applied to the staple line of the anastomosis.<sup>4</sup> One concern would be that tissue ischemia and necrosis caused by the technique

might lead to further complications such as fistula or anastomotic dehiscence. Another concern was that the dissipation of the energy might not be uniform and localized because of the presence of the staples which would lead to increased tissue damage. On the other hand, endoscopic clipping was shown to have similar efficacy with cauterization without injuring tissues in the treatment upper gastrointestinal bleeding in non-pouch patient.<sup>5</sup> In this case, which is the first case in the literature, we found that the endoscopic therapy with staple removal and deployment of endoclips was easily and effectively performed.

## Conflict of interest

The authors declare no conflict of interest.

## REFERENCES

1. Lian L, Serclova Z, Fazio VW, Kiran RP, Remzi F, Shen B. Clinical features and management of postoperative pouch bleeding after ileal pouch-anal anastomosis (IPAA). *J Gastrointest Surg* 2008; 12:1991-1994.
2. Lustosa SA, Matos D, Atallah AN, Castro AA. Stapled versus handsewn methods for colorectal anastomosis surgery. *Cochrane Database Syst Rev* 2001; CD003144.
3. Neutzling CB, Lustosa SA, Proenca IM, da Silva EM, Matos D. Stapled versus handsewn methods for colorectal anastomosis surgery. *Cochrane Database Syst Rev* 2012; 2: CD003144.
4. Perez RO, Sousa A, Jr., Bresciani C, Proscurshim I, Coser R, Kiss D, Habr-Gama A. Endoscopic management of postoperative stapled colorectal anastomosis hemorrhage. *Tech Coloproctol* 2007; 11:64-66.
5. Sung JJ, Tsoi KK, Lai LH, Wu JC, Lau JY. Endoscopic clipping versus injection and thermo-coagulation in the treatment of non-variceal upper gastrointestinal bleeding: a meta-analysis. *Gut* 2007; 56:1364-1373.