


Available online at www.sciencedirect.com

SciVerse ScienceDirect

journal homepage: www.elsevier.com/locate/ijnt

Case Report

Cranioplasty after decompressive craniectomy

Satya Bhusan Senapati^{a,*}, Sudhansu Sekhar Mishra^b, Srikanta Das^a,
Pratap Chandra Satpathy^a^a PG Department of Neuro Surgery, SCB Medical College and Hospital, Cuttack 753007, Odisha, India^b Prof and HOD, PG Department of Neuro Surgery, SCB Medical College and Hospital, Cuttack 753007, Odisha, India

ARTICLE INFO

Article history:

Received 22 July 2012

Accepted 31 October 2012

Available online 7 November 2012

Keywords:

Decompressive craniectomy

Early cranioplasty

Delayed cranioplasty

ABSTRACT

Decompressive craniectomy is a well accepted procedure for management of refractory intracranial hypertension after head trauma. All cases of decompressive craniectomy eventually require second surgery for cranioplasty. Most people believe that cranioplasty is for cosmetic purpose only, where as it has a definitive impact on restoration of normal intracranial physiology and improvement of patient neurological condition. There is conflicting opinion regarding timing for cranioplasty even in text books. In this article we describe operative procedure adopted by us for cranioplasty and simultaneously review the literature regarding appropriate timing for cranioplasty after decompressive craniectomy. We found there are definitive advantages of early cranioplasty over delayed cranioplasty. Points in favor of early cranioplasty are highlighted.

Copyright © 2012, Neurotrauma Society of India. All rights reserved.

1. Introduction

The rationale behind decompressive craniectomy (DC) is to convert an injury within a closed box with a fixed volume and limited reserve, into an open system with increased capacity to accommodate mass.¹ After bone removal, there is an increase in brain compliance and a shift of the pressure volume curve to the right. DC also induces a hyperemic response as evidenced by ^{99m}Tc SPECT, ³¹P MR imaging, and ¹³³Xe CT studies demonstrating augmentation of CBF as well as cerebral metabolism. Physiological monitoring using CBF, transcranial Doppler, and brain tissue oxygen probes has demonstrated increased CBF and brain tissue oxygen following decompressive craniectomy. After DC, bone is preserved either underneath the adjoining galea, subcutaneous pocket of anterior abdominal wall or cryopreserved. The bone flap remains stable in the subcutaneous plane of the

anterior abdominal wall for up to 6 months then resorption starts. If autogenous bone graft is not available for cranioplasty, then synthetic materials such as tantalum, silastic, titanium plate, prefabricated acrylic, synthetic bone substitute, and other similar material manufactured for the use of implantation into the body can also be used.

2. Case report

A 25 yr male underwent Rt Hemispheric DC for Rt acute subdural hemorrhage with underlying contusion and diffuse brain edema. Bone piece was preserved in fat layer of abdominal wall. He was discharged on 10th post operative period with GCS of E4 V4 M 6. Within next 15 days his condition improved to E4 V5 M 6. After 2 months of DC elective cranioplasty done by repositioning the preserved bone.

* Corresponding author.

E-mail addresses: satya.bhusan.senapati@gmail.com (S.B. Senapati), drssmishra@gmail.com (S. Sekhar Mishra), drsrikantadas@gmail.com (S. Das), senapati2k@yahoo.com (P. Chandra Satpathy).

0973-0508/\$ – see front matter Copyright © 2012, Neurotrauma Society of India. All rights reserved.

<http://dx.doi.org/10.1016/j.ijnt.2012.10.006>

(Fig. 1). Incision was given over previous scar. Scalp with underlying muscles dissected out from dura (Fig. 2). Edges of the surrounding bone are cleaned to let the graft to fit. After repositioning the preserved bone it is secured with screws (Figs. 3-5). Post operative period was uneventful. Though procedure looks simple but it requires skillful dissection. Dissecting out scalp with underlying muscles from dura is the most difficult step in this procedure. Keeping these difficulties in mind, it may be wise to lay another sheet of dural substitute over the entire area of exposed dura at the time of DC. This maneuver will prevent adhesion formation between the dura and scalp, however the infection rates have been found to be higher when this is used. Because of adhesion there is every chance of injuring underlying dura, if injured it should be repaired.

3. Discussion

Complications of DC can be divided into early and late complications. Expansion of contusions, new subdural and epidural hematomas contralateral to the decompressed hemisphere, and external cerebral herniation are the early post-operative complications of DC for TBI.^{2,3} Within the 1st week following decompression, CSF circulation derangements manifest commonly as subdural hygromas. There is a higher rate of wound infection in early post-operative period after DC. Contaminated wound in trauma patient, emergency surgery, large scalp flap with narrow and long scalp pedicle,

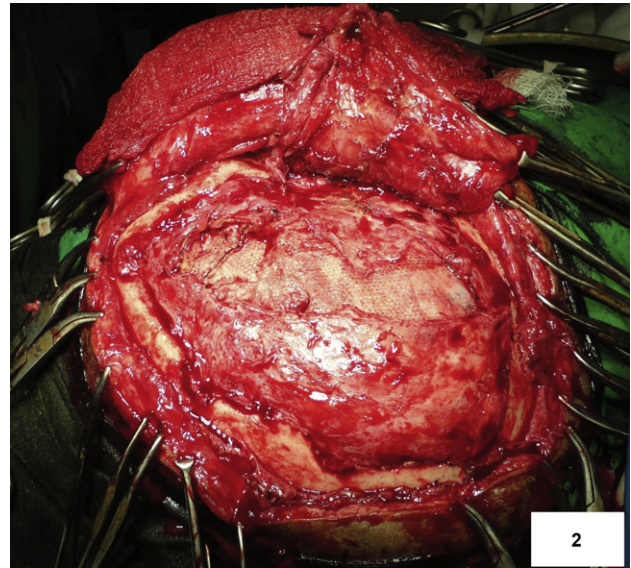


Fig. 2 – Scalp with underlying temporalis muscle were dissected out from dura. Previously used artificial dura for augmentation duroplasty can be seen at center.

tendency to injure superficial temporal artery and open up frontal air sinus makes this procedure vulnerable for higher rate of wound infection in early post-operative period. Sinking scalp flap, resorption of preserved bone, slower neurological

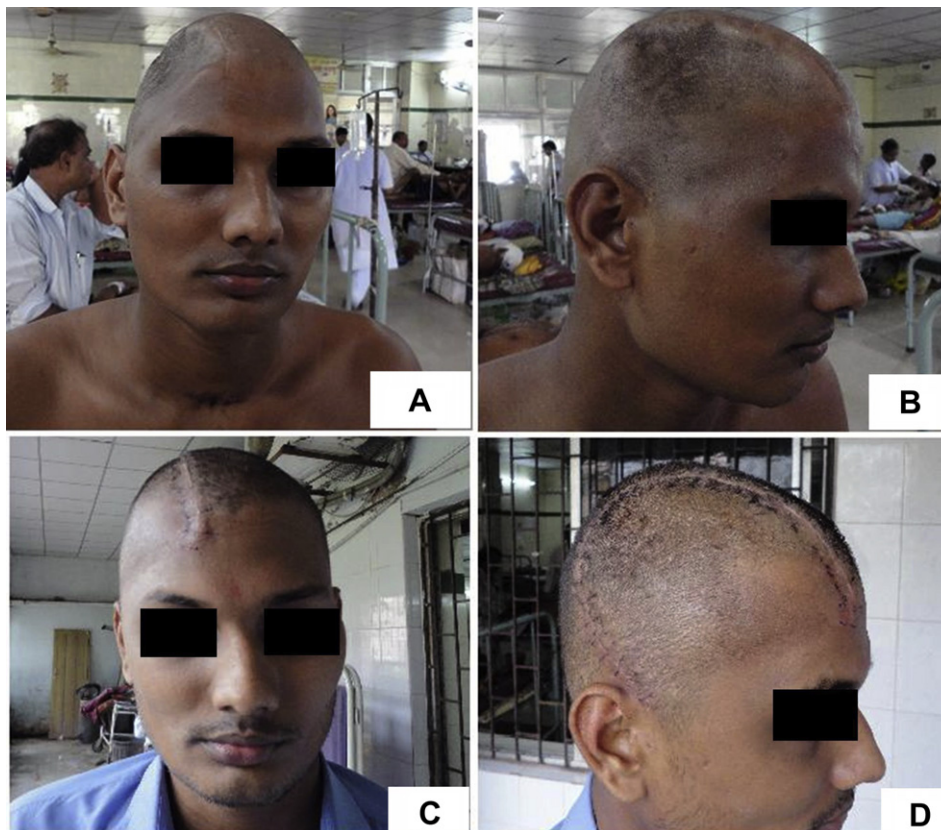

Fig. 1 – (A, B) Before cranioplasty. (C, D) After cranioplasty.

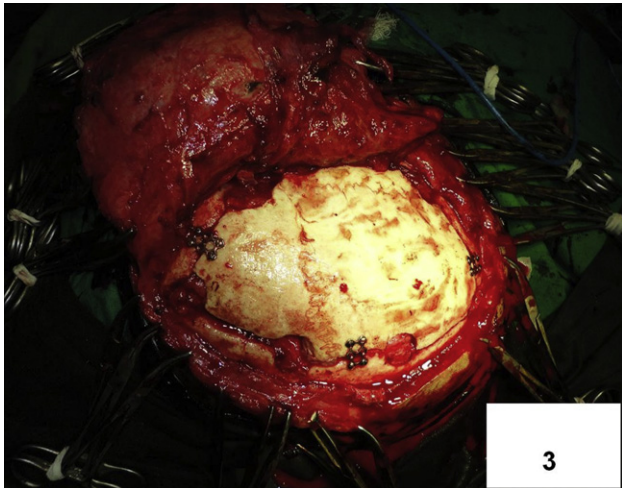


Fig. 3 – After repositioning the preserved bone, it is secured with titanium screws and plate.

recovery rates, persistent headache, hydrocephalus are the most frequent complications of DC beyond 1 month.^{4–6} All these late complications get reversed after cranioplasty.

According to traditional neurosurgical dictum, a shorter time from craniectomy to cranioplasty is associated with poor outcome.^{7,8} This opinion was based upon the large series of patients reported by Rish and colleagues in 1979.⁹ They found that cranioplasty taking place 1–6 months after craniectomy had the highest complication rate (7.9%) and those performed 12–18 months after craniectomy had the lowest complication rate (4.5%). The major complication they found was wound infection in early period. The biasing factor in that study was inclusion of only patients with penetrating head injuries. From our experience we found that in those cases where cranioplasty was done after 3 months of post surgery they had a greater difficulty in dissecting the tissue planes and blood loss was more. We reviewed literature available in text book and internet regarding appropriate time for cranioplasty after

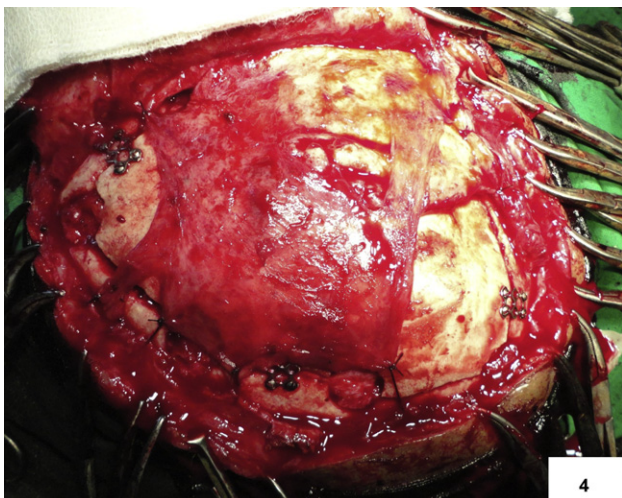


Fig. 4 – Temporalis muscle repositioned to its place.

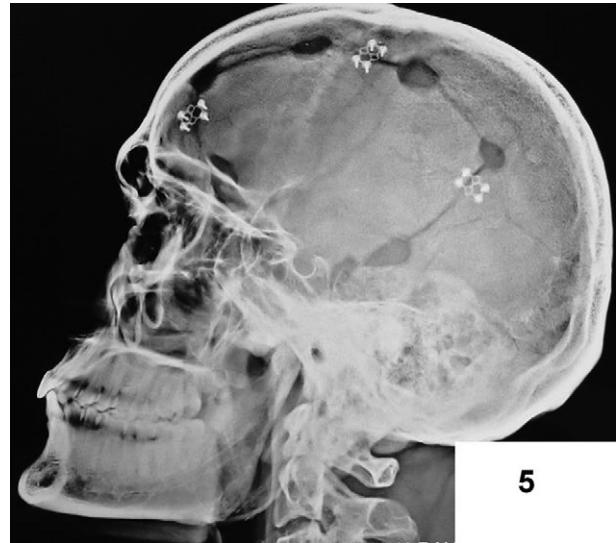


Fig. 5 – Post cranioplasty X-ray showing bone flap at proper place.

DC. In most recent literature authors conclude that there is a definitive advantage of early cranioplasty around 2 months post surgery over delayed cranioplasty. However we want to emphasize that the time should not be bound by a chronological number of two months, rather the neurological status of the patient, and its progression, Infections on the scalp, decubitus sores, sinking of skin flap and hydrocephalus should be taken into consideration before planning for cranioplasty.

4. Conclusion

Early cranioplasty prevents late complications of DC like sinking scalp flap, resorption of preserved bone, hydrocephalus and syndrome of the trephined. Dissection of tissue planes is easier in early post operative period. So far wound infection is concerned almost all infected wound get cured around 2nd month. If infection at surgical site found then cranioplasty can be postponed till infection subsides. Patient's attendant should be properly counseled regarding importance of early cranioplasty, it should be emphasized that cranioplasty after DC is not only for cosmetic purpose; rather it helps in early recovery of neurological conditions.

Conflicts of interest

All authors have none to declare.

REFERENCES

1. Plesnila N. Decompression craniectomy after traumatic brain injury: recent experimental results. *Prog Brain Res.* 2007;161:393–400.

2. Cohen JE, Rajz G, Itshayek E, Umansky F. Bilateral acute epidural hematoma after evacuation of acute subdural hematoma: brain shift and the dynamics of extra axial collections. *Neurol Res.* 2004;26:763–766.
3. Mazzini L, Campini R, Angelino E, Rognone F, Pastore I, Oliveri G. Posttraumatic hydrocephalus: a clinical, neuroradiologic, and neuropsychologic assessment of long-term outcome. *Arch Phys Med Rehabil.* 2003;84:1637–1641.
4. Grant F, Norcross N. Repair of cranial defects by cranioplasty. *Ann Surg.* 1939;110:488–512.
5. Grant GA, Jolley M, Ellenbogen RG, Roberts TS, Gruss JR, Loeser JD. Failure of autologous bone-assisted cranioplasty following decompressive craniectomy in children and adolescents. *Neurosurgery.* 2004;100:163–168.
6. Marmarou A, Foda MA, Bandoh K, et al. Posttraumatic ventriculomegaly: hydrocephalus or atrophy? A new approach diagnosis using CSF dynamics. *J Neurosurg.* 1996;85:1026–1035.
7. Foster RD, Antonyshyn OM, Lee C, Holland M, Fazl M. Cranioplasty: indications, techniques, and results. In: Schmidek HH, ed. *Schmidek and Sweet Operative Neurosurgical Techniques.* Philadelphia: WB Saunders; 2000:29–44.
8. Shaffrey ME, Persing JA, Shaffrey CI, Delashaw JB, Jane JA. Craniofacial reconstruction. In: Apuzzo MLJ, ed. *Brain Surgery: Complication and Avoidance Management.* New York: Churchill Livingstone; 1993:1373–1398.
9. Rish BL, Dillon JD, Meierowsky AM, et al. Cranioplasty: a review of 1030 cases of penetrating head injury. *Neurosurgery.* 1979;4:381–385.