


Available online at www.sciencedirect.com

SciVerse ScienceDirect

journal homepage: www.elsevier.com/locate/ijnt

Case report

Severe traumatic brain injury in a child falling from the fourth floor and a remarkable recovery with exquisite team management

K.I. Mathai*, Rahul Yadav, Kapil Muley, Vishwanath Kulkarni, S.S. Mathai

INHS Asvini, Colaba, Mumbai, India

ARTICLE INFO

Article history:

Received 14 February 2012

Accepted 8 April 2012

Available online 23 April 2012

Keywords:

Severe head injury

Decompressive craniectomy

Outcome

ABSTRACT

A 04-year-old child sustained a severe head injury as a result of a fall from the fourth floor to a cemented surface on 20 Sep 2011. Prompt resuscitation by the pediatric team and decompressive craniectomy followed by elective ventilation resulted in remarkable recovery of both the motor deficit (Hemiplegia) and Dysphasia.

Copyright © 2012, Neurotrauma Society of India. All rights reserved.

1. Case report

1.1. History

This 04-year-old female child was in good health, when she accidentally fell from the verandah of her fourth floor house to the cemented road below on 20 Sep 2011.

She was rushed to hospital in a comatose state. Evaluated within 1 h of accident she was found to have an unstable respiration with apneic spells. Her heart rate was 146/min. Her GCS was E1V1M4-5 with (Rt) Hemiplegia. There was a Left Fronto-parietal boggy scalp swelling. There was Left sixth nerve palsy. An IV line was established and fluid resuscitation initiated. With intermittent bag and mask and oxygen support she was rushed to the CT center.

CT scan showed of depressed fracture of the Left Frontal region. There was evidence of bleeding in the Left Sylvian

fissure and hypodensity of the L Temporal region suggestive of an evolving contusion or infarct (Fig. 1).

Ultrasound for abdominal trauma, chest X-ray and skeletal survey revealed only a fracture of her wrist.

The child was resuscitated and intubated in the pediatric intensive care unit while the operation theater was reached and blood transfusions arranged.

1.2. Surgical procedure

A Fronto-parieto-temporal decompressive craniectomy was done. The dura was opened with stellate incisions and clots and contusions irrigated away. Warm saline irrigation in the Sylvian fissure was continued and blood transfusion given till return of pulsatility of MCA branches was achieved. A Temporalis fascia dural patch was used to provide a wide duraplasty. The bone flap was cleaned and wrapped in sterile plastic for

* Corresponding author.

E-mail address: khalimathai@yahoo.co.in (K.I. Mathai).

0973-0508/\$ – see front matter Copyright © 2012, Neurotrauma Society of India. All rights reserved.

doi:10.1016/j.ijnt.2012.04.006

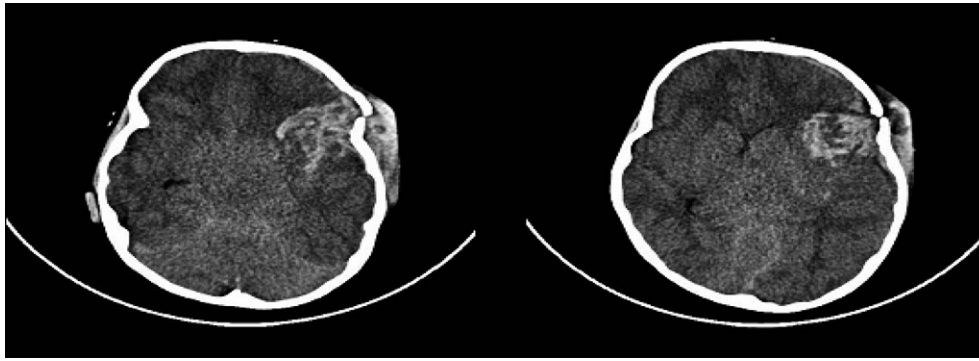


Fig. 1 – CT scan showing Sylvian region contusion and MCA Territory Hypodensity.



Fig. 2 – Child with no significant deficit post-cranioplasty.

refrigeration. The patient was electively ventilated thereafter for 72 h.

1.3. Post-operative recovery

Weaning was achieved successfully by day 5 post-operatively. (Rt) Hemiplegia and dysphasia persisted.

By 10 days post-op there was return of power initially in the lower limb and then in upper limb. Speech started returning by the third week post-operatively.

On 28 Oct 2011 she was taken up again for restoration of cranial integrity. The bone flap was replaced.

1.4. Present status

The child is now ambulating with mild weakness (4/5) of R upper limb. She is now speaking a few words. Antiepileptics are being continued for six months (Fig. 2).

2. Discussion

Pediatric Brain injuries behave differently from adult TBI.¹ The Childs brain is relatively hypersensitive to hypoxia

but dramatic resilience is demonstrated with expedient management.

In this patient prompt fluid resuscitation² and opportune surgical management helped avert the secondary cascades³ which would have lead on to irreversible neurological deficits.

The importance of early and appropriate resuscitation and surgical intervention is highlighted in this case.⁴

Routine ICP monitoring is not performed in all patients at our center. The status of brain bulge is apparent after a decompressive craniectomy and along with neurological status provides sufficient clues for post-operative ventilatory and anti-edema manipulations.⁵

Monitoring Brain Tissue Oxygen (PbO₂) has been reported to be of benefit in the management of the severely head injured patients.^{6,7}

A team approach to Traumatic Brain Injury and opportune interventions are the key to hearing results.^{8,9}

3. Conclusion

Falling from the fourth floor to a cemented ground resulted in a severe head injury. Prompt team based management by the pediatric team, Neuro surgery, Neuro Anesthetic team, has lead to remarkable recovery.

REFERENCES

1. Nortam PK, Burganrappa SC, Raynor SC, Rao M, Taylon C. Cerebral oxygenation in major paediatric trauma, its relevance to trauma severity and outcome. *J Pediatr Surg*. 2006 Mar;41(3):505–513.
2. Clifton GL, Miller ER, Choi SC, Levin HS, Smith VL. Fluids thresholds and outcome from severe brain injury. *Crit Care Med*. 2002 Apr;30(4):739–745.
3. Sarrof Zahed AS, Peltonen EE, Unterberg AW. Secondary insults in severe head injury.... do multiply injured patients do worse? *Crit Care Med*. 2001 Jan;29(6):1116–1123.
4. Henzier D, Cooper DJ, Tremayne AB, Rossiant R, Higgins A. Early modifiable factors associated with fatal outcome in patients with severe traumatic brain injury: a case control study. *Crit Care Med*. 2007 Apr;35(4):1027–1031.
5. Stocchetti N, Rossi S, Colombo A. Intracranial hypertension in head injury: management and results. *Intensive Care Med*. 1999 Apr;25(4):371–376.
6. Nortam PK, Morrison JF, Nathoo N. Brain tissue oxygen monitoring in traumatic brain injury & major trauma: outcome analysis of a brain tissue oxygen directed therapy. *J Neurosurg*. 2009 Oct;111(4):672–682.
7. Spiotta AM, Stiefel MF, Gracias VH, et al. Brain tissue oxygen directed management & outcome in patients with severe traumatic brain injury. *J Neurosurg*. 2010 Sep;113(3):571–580.
8. Piper DR, Valadha AB, Maish C. Surgical management of patients with severe head injuries. *AORN J*. 1996 May;63(5):854–864.
9. Stocchetti N, Penny KI, Teasdale GM. European Brain Injury Consortium. Intensive care management of head injured patients in Europe: a survey from the European brain injury consortium. *Intensive Care Med*. 2001 Feb;27(2):400–406.