

### Lesionectomy and tailored disconnection in a case of refractory extratemporal lobe epilepsy



Suchanda Bhattacharjee, A. Jabeen, T. Indar Mohan

Nizam's Institute of Medical Sciences, Hyderabad, India

A 9 year old girl presented with complaints of seizure for six years, five to six episodes per day along with a bony defect in the vertex region. Seizure was characterised by an aura of abdominal discomfort and visual hallucination. Ictal event was comprised of tonic and clonic movement of all four limbs. Post ictally there was drowsiness, vomiting and excessive salivation lasting for one hour. There was reduced visual acuity and bilateral inferior quadrantanopia. She was on four antiepileptics and on and off course of steroids. EEG was suggestive of abnormal awake and sleep multifocal IEDs and ictal seizures suggested left hemispheric involvement. Ictal EEG showed electrodecremental pattern. MRI showed a left parietal atretic cephalocele with underlying gliosis and polygyria of left cuneus. There were many radiological abnormalities in the MRI. DTI of visual pathway showed reduced connectivity and arborisation with dysplastic left cuneus. PET CT scan showed hypometabolism of left frontal, parietal and occipital regions.

A left parietal craniotomy with excision of the herniated atretic cephalocele along with ECoG guided lesionectomy was done. A tailored posterior disconnection was done on the basis of EcoG findings. Split calvarial graft was placed over the bony defect. Child is completely seizure free on 3 months follow up and post surgery 7th day EEG showed marked reduction in IEDS.

Histopathology revealed an encephalocele with microdysgenesis.

Extratemporal epilepsy is commoner in children but the localisation and lateralisation is difficult in many cases due to a multitude of factors. Surgery offers reasonably good result in high refractory cases and should be done as early as possible for treating seizure, preventing cognitive decline and early social rehabilitation of child and family. A proper presurgical evaluation along with customised surgical plan is the key to a good outcome.

<http://dx.doi.org/10.1016/j.ijep.2015.12.044>

How I do it

### Minimally invasive anterior temporal lobectomy with linear skin incision based on SEEG findings

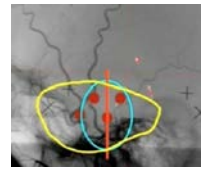


Tomokatsu Hori, Taku Ochiai, Yuichi Kubota

Department of Neurosurgery, Tokyo Women's Medical University, Japan

• Based on the stereotactically implanted depth EEG recording of interictal and ictal activity, in this medically intractable right temporal lobe epileptic patient, the extent of removal is planned to remove temporal lobe as indicated yellow line

in Fig. 1, and linear skin incision in Fig. 1 is supposed to be sufficient to accomplish anterior temporal lobectomy.



• In order to get into the temporal horn in this patient, superior temporal sulcus (STS) is selected to reach the base of STS, and then rostrocaudal suction of white matter (temporal stem) will be able to open temporal horn. After opening the temporal horn widely, lateral part of the temporal cortex (middle temporal, inferior temporal and fusiform gyri) is planned to remove en bloc, then medial part of the temporal cortex including hippocampus anterior to the choroidal point, and finally basolateral part of the amygdala and uncus are planned to be removed in piecemeal fashion without opening arachnoid membrane covering oculomotor nerve, posterior cerebral artery, anterior choroidal artery and basal vein.

<http://dx.doi.org/10.1016/j.ijep.2015.12.045>

### Lesionectomy with frontal disconnection is useful for frontal epilepsy with cortical dysplasia. Report of 6 consecutive patients



T. Hori, K. Abe, G. Matsuoka, K. Niimura

Department of Neurosurgery, Shin Yurigaoka General Hospital & Moriyama Memorial Hospital, Japan

• Generally frontal lobe epilepsy with FCD is difficult to manage in terms of seizure control. In this communication, the authors will present a new surgical technique, that is, lesionectomy and frontal disconnection for medically intractable frontal lobe epilepsy caused by FCD in consecutive five patients. All resected specimens are neuropathologically investigated by the member of ILAE task force (HM). Post-operative follow-up period ranged from 3 months to 5 years and 6 months, and no definite postoperative complication has been observed so far. Place and extent of frontal disconnection was determined by the perioperative ECoG findings in each case, and postoperative MRI images have shown the extent of frontal disconnection.

• The postoperative seizure control is satisfactory, that is, Engel's class Ia for four cases, and class II for two pats. In conclusion, this new technique is useful to manage medically intractable frontal lobe epilepsy with FCD.

• MCD types are ILAE Class Ia: two, Ic: one, IIc cavernous angioma; one, IIId porencephaly: one, and mMCD; one.

<http://dx.doi.org/10.1016/j.ijep.2015.12.046>