

Role of intraoperative MRI in epilepsy surgeries: Preliminary experience for two years



Nilesh Kurwale, P. Sarat Chandra*, Vivek Tandon, Ajay Garg, Chitra Sarkar, Madhavi Tripathi, C.S. Bal, Manjari Tripathi

Dept of Neurosurgery and Center of Excellence
AIIMS, New Delhi, India
E-mail address: saratpchandra3@gmail.com
(P.S. Chandra).

Background: Epilepsy surgery often involves resection substrates that are subtle and often require special MRI sequences to detect them. Guidance at the time of surgery is often by visual cues, neuronavigation and EEG parameters. Intraoperative MRI (iMRI) may provide better guidance especially in providing information about total excision that has a clear impact on outcome.

Objective: To determine the usefulness of iMRI in epilepsy surgeries with regards to extent of surgical resection and seizure outcome along.

Study design: Longitudinal, observational.

Methods: Patients undergoing epilepsy surgeries in intraoperative MRI OT were primarily evaluated for extent of resection, operative time, pathologies, resultant extra resection, and seizure outcome along with complications.

Results: Thirty-nine patients with mean age of 18 years (range 3–65 years) with PRE underwent surgical intervention. Mean duration of seizures was 10.2 years. Surgical interventions included tumor resection (23%), resection of focal cortical dysplasia (28%), medial temporal lobe surgeries (18%) and disconnection surgeries (31%). In 13% (5 out of 39) of these patients, iMRI was decisive and resulted in increased resection of lesions despite extensive use of electrocorticography and navigation in all cases. This is only observed for lesional pathologies where it made 36.6% change in surgeon's intraoperative decision. Complete resection was observed in (89%) of patients. It is at the cost of 24% increase in operative time without any clinical complications of prolonged anesthesia and surgeries. Major and minor complications were observed in 2.5% and 10% of patients respectively. The mean follow-up was 14 months. Favorable postoperative seizure control (Engel Classes I and II) was achieved in 85% and complete seizure freedom in 77% patients.

Conclusions: iMRI increases the extent of resection mainly in extratemporal lesional epilepsy surgeries translating in good seizure outcomes and not found to be much beneficial in medial temporal sclerosis surgeries and disconnection surgeries. Increase in operative times does not found to lead any clinical significant complications.

<http://dx.doi.org/10.1016/j.ijep.2015.12.020>

Use of multi-modal imaging to improve the localization of epileptogenic focus



Nilesh Kurwale, P. Sarat Chandra*, Vivek Tandon, Ajay Garg, Chitra Sarkar, Madhavi Tripathi, C.S. Bal, Manjari Tripathi

Dept of Neurosurgery and Center of Excellence
AIIMS, New Delhi, India
E-mail address: saratpchandra3@gmail.com
(P.S. Chandra).

Multi-modal imaging using MRI, PET, SPECT along with MEG provides the best possible option to localize the epileptogenic focus non-invasively. The option to use it with intra-operative MRI along with neuronavigation provides the best possible option to localize the epileptogenic focus. The paper describes the centre's experience in localizing the epileptogenic focus for extra temporal and lateral temporal pathologies by co-registering MRI, PET, SPECT and MEG. In addition, intra operative ECoG was used to localize the focus at surgery. The center has now experience with over 100 cases from an experience of over 1500 cases of epilepsy surgery where this technique was used. The preliminary experience is described here.

<http://dx.doi.org/10.1016/j.ijep.2015.12.021>

Abstract – 9th AESC Udaipur, 2015

How to decide the candidates of epilepsy surgery?



Eun-ik Son

Neurosurgery and Epilepsy Center, Keimyung University Hospital, Daegu, Republic of Korea

Introduction: Patients are considered for the epilepsy surgery if they have medically intractable epilepsy that interferes with quality of life significantly. Our sequential protocol for presurgical evaluation consists of a battery of tests designed to both lateralize and localize the epileptogenic region. Intractable patients with incidental small lesions on high-resolution MRI could also enter into this protocol to identify adjacent and/or remote epileptogenic areas.

Presurgical evaluation: Phase I (non-invasive studies); All patients evaluated for surgery undergo complete clinical history and detailed semiology, electrophysiologic (scalp EEG and 24-h video-EEG monitoring) and neuroimaging (CT, MRI, SPECT, PET scan) studies, and neuropsychological studies with intracarotid amobarbital procedure (IAP). Data from the non-invasive evaluation are analyzed in an attempt to localize the area of brain responsible for initiation of the patient's habitual seizures. If suggests a localized area responsible for the seizures, surgery is recommended. Phase II (invasive monitoring); Intracranial recordings are performed in patients who may be good candidates for surgery but who do not meet criteria for surgery based on noninvasive evaluation. Multiple types of implanted electrodes, such as subdural strip, grid and/or depth electrodes may be used. The type and location of electrodes are carefully determined to prevent sampling error.

Intraoperative evaluations: Tailored resection for minimalism by intraoperative acute recording (ECoG) and functional brain mapping with the electrical stimulation technique to identify the epileptic and essential areas related to language or sensorimotor are usually performed under local and intravenous propofol anesthesia.

Conclusion: Our protocols to decide the candidates of epilepsy surgery for patients with intractable epilepsy will be presented greater detail along with the subject of the procedural issues of epilepsy care as well.

<http://dx.doi.org/10.1016/j.ijep.2015.12.022>

The treatment of foci resection and bipolar electro-coagulation on functional cortex in multifocal epilepsy associated with tuberous sclerosis complex involving eloquent cortex

Feng Zhai, Guoming Luan

Department of Neurosurgery, Beijing Sanbo Brain Hospital, Capital Medical University, China



Objectives: Tuberous sclerosis complex (TSC)-associated epilepsy is medically refractory seizures secondary to cortical tubers and leads to mental retardation in childhood. TSC patients are often with refractory epilepsy involving eloquent and noneloquent cortex in multiple lobes and multiple independent seizure foci which made these patients poor candidates for conventional surgery. We have previously presented that the approach of pure bipolar electro-coagulation on functional cortex (BCFC) in the treatment of unifocal epilepsy involving eloquent areas is effective, safe and easy to use. This report describes our long-term follow-up for combined resective surgery and BCFC in TSC patients with refractory epilepsy involving eloquent and noneloquent cortex.

Methods: 8 patients aged from 8 to 31 years were admitted with epilepsy. The cranial computerized tomography (CT) showed cortical and subependymal calcification, magnetic resonance imaging (MRI) demonstrated multiple cortical tubers. All patients were with drug resistant epilepsy, despite treatment with two antiepileptic drugs (AEDs). Initiated combination therapy of foci resection and BCFC for epilepsy management between May 2004 and May 2012, the patients were retrospectively reviewed with regard to seizure outcome, postoperative complications.

Results: The combination therapy of foci resection and BCFC resulted in remarkable improvement in patient's ambulation and cessation of seizures. Engel class I outcome was achieved in 3 patients, Engel class II in 3 patients, Engel class III in 1 patient and Engel class IV in 1 patient. All patients were with no permanent neurological deficit noticed during a standard clinical examination. In addition, all patients showed some improvement in behavior or cognitive function (Figs. 1-3).

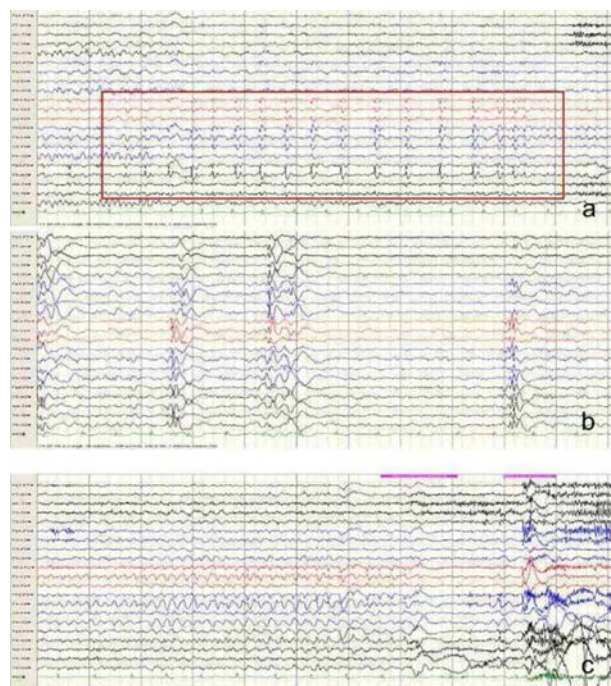


Fig. 1 – (a) Interictal-1 displays as bilateral symmetric high amplitude of multi-spike and slow waves during sleep. (b) Interictal-2 shows low to medial amplitude of awake multi-spike and slow waves on the right frontal (F4, F8), central (C4) and temporal (T4). Clinical seizures were characterized by tonic of left arm, laughing (Gelastic seizures) and followed by secondary generalized tonic seizures. (c) The corresponding ictal EEG revealed bilateral epileptiform discharge, more predominant over the right frontal (F4, F8), central (C4) and temporal.

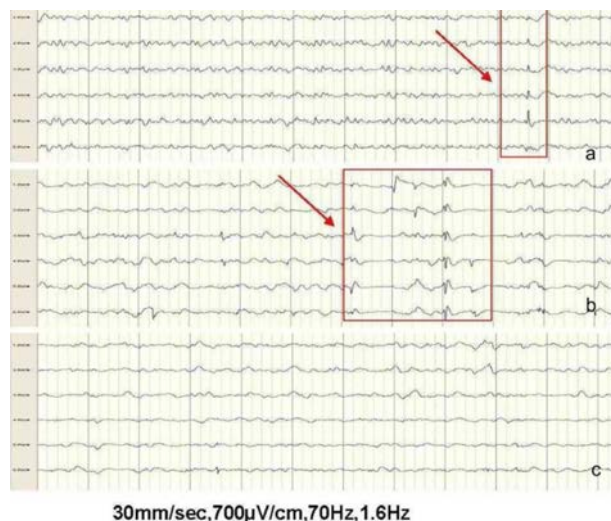


Fig. 2 – (a) Pre-resection EcoG revealed significant spiking in the central (eloquent epileptogenic zone) (arrows). (b) Extremely active interictal spikes were noted in the post-resection EcoG (arrows). (c) No epileptiform discharges were present over right central cortex after the BCFC procedure.