

## Handle with care, penetrating neurotrauma: Case report and review of literature

Murtaza Rashid MD, Ali Razmkon MD, Ali Reza Ziaei MD, Mosa Taghipour MD  
Department of Neurosurgery, Nemazee Hospital, Shiraz University of Medical Sciences, Shiraz, Iran

**Abstract:** Penetrating brain injuries are among the most challenging areas in neurosurgery. Many of these injuries are caused by industrial accidents or criminal assaults. In this case report we present an unusually rare case of a 23-year old man. The man while driving a tractor skidded off and was thrown on an agricultural instrument lying on a wall. The instrument penetrated his right sub-mandibular region and the patient got hung on it. The instrument was successfully removed by his relatives. Neuroimaging showed a tract traversing up to the right parietal lobe. The patient was managed rigorously by a multidisciplinary team for four weeks and was discharged with follow-up care.

**Keywords:** brain; neuroimaging; penetrating injuries

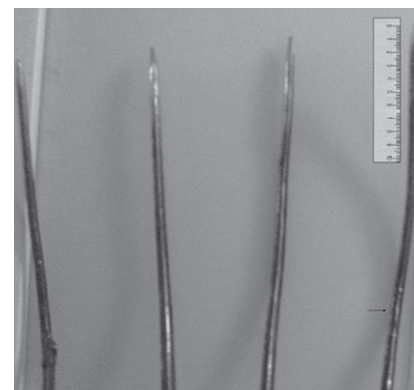
### INTRODUCTION

Intracranial foreign bodies due to non-missile intracranial penetrations are one of the rarely encountered situations in surgery. Most of these penetrating injuries result from industrial accidents, criminal assaults, self-inflicted wounds, etc<sup>1,2,3,4</sup>. Several foreign bodies penetrating the cranium such as knives, nails, pencils, wood pieces, wire, ice picks, keys, chopsticks, umbrella ends, antennae, scissors, paint brushes, crochet hooks, sewing needles, carpet tacks, thumbtacks, automobile bolts, crowbars and fishing harpoons have been described in the literature<sup>1</sup>. Most patients with stabbed heads have had the weapon removed by the assailant before their admission<sup>3</sup>. Blind removal of the penetrating object can be dangerous because it may rock or twist the object resulting in secondary vascular impairment and brain damage<sup>4,5</sup>. The complications which cause mortality in early stage are intra-cerebral hemorrhage, contusion, major vascular injury and meningitis<sup>1</sup>. Infection frequently occurs from the penetration of objects through the air sinuses or oropharyngeal mucosa<sup>3</sup>. A CT scan helps in determining the extent of underlying brain injury and the assessment of operative intervention<sup>6</sup>. To exclude unexpected vascular injuries in patients with penetrating stab wounds to the head, angiography is always

necessary<sup>3</sup>. We present a patient who was referred to our Emergency Department after a penetrating submandibular injury.

### CASE REPORT

A 23-year old man was admitted to our Emergency Department following vertical penetration of a sharp agricultural instrument in the right sub-mandibular region. The patient was working in an agricultural field when he skidded off the tractor and landed himself on an agricultural instrument lying on the wall (Fig. 1). The instrument was successfully pulled out by his relatives after a short while; it was measured to have penetrated 19 cm inside his skull. The patient's level of consciousness was almost normal but he had experienced repeated episodes of vomiting after the removal of the instrument. On admission to Emergency, his vital signs were normal except that his pulse rate was 120/min. His Glasgow coma scale [GCS] score was 12/15. A small 1 cm cut



**Fig. 1:** Sharp agricultural instrument with multiple piercing rods. The one on the right side penetrated the patient up to the arrow mark.

#### Address for correspondence :

Murtaza Rashid  
Department of Neurosurgery,  
Shiraz University of Medical Sciences, Shiraz Iran.  
PO Box: 3481  
Tel: +98 917 910 5372 Fax: +98 711 627 9641  
Email: Dr.MurtazaRashid@gmail.com

was seen below his right mandibular angle. He had mild weakness in the left upper and lower extremities with power of three and four respectively and right-sided ptosis [Fig 2] with fixed pupil of about 6 mm. The left pupil had brisk reaction to light. After admission he had two episodes of vomiting while in the Emergency Department. There was no cerebrospinal fluid rhinorrhea or otorrhea. No vocal-cord paralysis was found. Skull and spine X-rays were normal. Emergency brain CT-scan was also performed which revealed mild signs of subarachnoid hemorrhage [Fig. 3a]. A comprehensive antibiotic coverage with Amikacin, Ceftriaxone and Vancomycin were started besides Heparin and anticonvulsant therapy. On the next day, a brain MRI was performed which revealed right periventricular region hypersignality at T2 with centre of hyposignality; hypersignality in flair with hyposignal focus extended to the right parasagittal region and centrum semiovale. In T1 the lesion was only hyposignal with signal void in centres and no enhancement after contrast injection [Fig. 4a]. In the parasagittal view, a hypointense line probably showing the tract of the instrument was seen [Fig. 4b]. Brain MR Angiography and MR venography did not showed any vascular lesion. Angiography of the carotid arteries revealed nothing abnormal. On the third day, the patient's

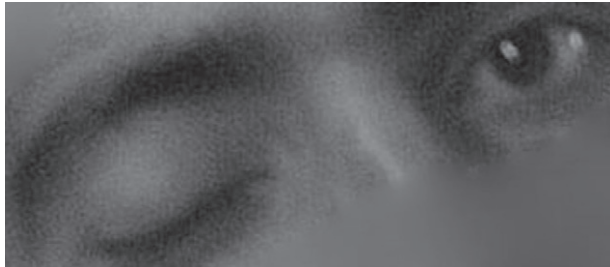


Fig. 2: The sharp instrument which penetrated the right submandibular region vertically led to right sided ptosis which is clearly evident.

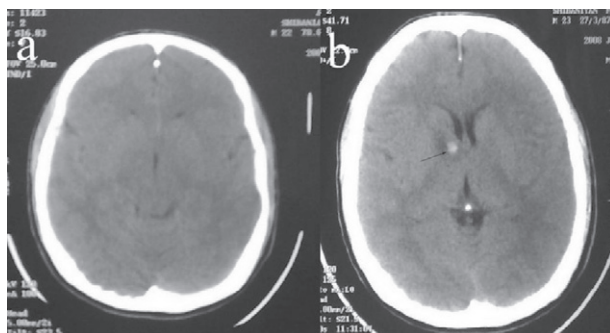


Fig. 3: Unenhanced brain CT scan of the patient on admission [a] and on the following day [b]. Note the evolution of a small contusion at the periventricular region.

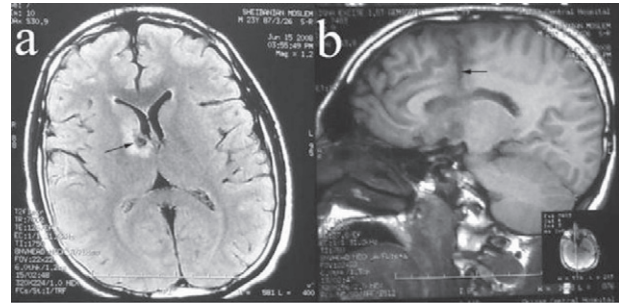


Fig. 4: Unenhanced brain MRI of the patient. [a] Axial view shows a small contusion with surrounding edema. [b] Right parasagittal view shows a hypointense line probably indicative of the tract created by the sharp instrument.

GCS score was measured at 15 and his left upper and lower extremity power was normal. He was able to take oral diet without any nausea or vomiting. On the same day, a brain CT-scan was performed which now clearly revealed a hyperdense area at the right paraventricular region possibly due to the remission of edema [Fig. 3b]. The Visual Evoked Potentials [VEP] of both the eyes was abnormal while the orbital CT-scan was found to be normal. He was put under strict observation for four weeks in the hospital to monitor any abnormal behaviour which he did show later; on the fourth day of his admission, he developed delusional thoughts. During these four weeks, brain angiography was repeated once more and was normal. The patient was discharged with the follow-up care of neurosurgeon, ophthalmologist and a psychiatrist.

## DISCUSSION

On September 13, 1848, while using a tamping iron to pack explosives into a rock, Phineas Gage, a 25-year-old construction foreman, triggered an uncontrolled explosion that propelled the tool [which measured 3 ft 7 in. in length and 1.25 in. in diameter] through his left cheek and head<sup>7</sup>. It has been recently since then that we have seen substantial advancement in neuroradiological imaging which helps us better assess and manage penetrating brain injuries. There are case reports of injury from common household items such as toys, kitchen utensils, writing instruments, hair accessories, metal rod or wire, nail or needle, lawn darts or garden rake, and by bullets or pellets<sup>1,2,4,5,6</sup>. Deeply penetrating head and neck trauma is an uncommon life-threatening injury and a challenging problem. According to the literature most stab wounds of the brain occur through the orbital or the temporal region which may be due to thinness of the bone in these areas. An examination of the neurovascular and systemic physical status is a first

requirement and the decision as to which approach to adopt for the removal of the foreign body is of critical importance<sup>8</sup>. Normally a CT Scan will help determine the extent of underlying brain injury and the need for operative intervention<sup>6</sup>, but in our case the earliest CT Scan [Fig 3a] findings would have been misleading. Therefore, in an emergency setting CT Scan is helpful but not always conclusive. Removing of the penetrating object blindly, as in our case, is often dangerous as it may further impair vascular and neurological deficit; unfortunately, most of the patients come to the hospital after the removal of the penetrating object<sup>3,4,5</sup>.

Taylor considered two groups: those who presented with retained instrument and those who referred after removal<sup>9</sup>. An increased incidence of vascular injury and mortality was found in the first group. This was claimed to be due to the fact that retained objects tend to be more penetrating, and there is higher incidence of petrous bone penetration followed by carotid artery injury. Present information suggests that one third of the patients whose weapon had been removed before admission will have vascular complications, and that a significant proportion of these will be treatable<sup>10,11</sup>. Angiography – an important tool in the assessment of all penetrating brain injuries, can be helpful in the diagnosis. However in this respect controversy exists with regard to its timing. Kieck and de Villiers proposed that angiography should be carried out at the start of the second week after the initial injury<sup>11</sup>. The view that traumatic aneurysms develop and many studies reporting that aneurysms were not visible on an initial angiogram obtained shortly after the injury support this theory<sup>12,13,14,15</sup>. There are, however, many reports in which traumatic aneurysms were identified within a very short time, even a few hours, following the injury<sup>16,17,18,19</sup>. Aneurysms may also rupture any time after formation, and when they do, patient mortality is high<sup>3,11,20,21</sup>. Trevou and Dellen in their comprehensive study suggest cerebral angiography should be performed soon after admission, and where necessary, immediately before emergency surgery<sup>3</sup>. They also recommend that patients with vasospasm or vessel cut-off on angiography should undergo a second angiogram. In the present case cerebral angiography was performed soon after admission and twice again during the following weeks which revealed nothing abnormal. Further studies are needed to evaluate if these patients need further angiogram follow-ups. Last but not the least, changes in the behaviour of these patients is a long-term puzzle which is a subject of further

investigation. The brain lesion that caused the profound personality changes for which Phineas Gage case became famous has been presumed to have damage involving both the left and the right prefrontal cortices in a pattern that, as confirmed by Gage's modern counterparts, causes a defect in rational decision making and the processing of emotion<sup>22</sup>. In our case also the patient started to have delusional thoughts after a few days. The changes in behaviour at large need to be observed closely and carefully in subsequent follow-ups.

#### Acknowledgement

We thank the patient and his relatives for great amount of patience and cooperation.

#### REFERENCES

1. Gokcek C, Erdem Y, Koktekir E, Karatay M, Bayar MA, Edebalı N *et al.* Intracranial foreign body. *Turkish Neurosurgery* 2007; 17:121-4.
2. Al-Mefty O, Holoubi A, Fow JL. Value of angiography in cerebral nail gun injuries. *Am J Neuroradiol* 1986; 7:164-5.
3. de Trevou MD, Van Dellen JR. Penetrating stab wound to the brain: the timing of angiography in patients presenting with the weapon already removed. *Neurosurgery* 1992; 31:905-12.
4. Miller P, Lipschitz R. Transclival penetrating injury. *Neurosurgery* 1984; 21:92-4.
5. Nath FP, Teasdale E, Mendelow AD. Penetrating injury of the tuberculum sellae. *Neurosurgery* 1984; 14:598-600.
6. Kanagarajan A, Sgouros S. Unusual penetrating cranio-cerebral injuries in children from mains plug. *Childs Nerv Syst* 2007; 23:1181-3.
7. Ratiu P, Talos IF. The tale of Phineas Gage, digitally remastered. *N Engl J Med* 2004; 351[23]:e21.
8. Cosan T.E, Arslantas A, Guner A.I, Vural M, Kaya T, Tel E. Injury caused by deeply penetrating knife blade lodged in infratemporal fossa. *Eur J Emer Med* 2001; 8:51-4.
9. Taylor AG, Peter JC. Patients with retained transcranial knife blades: a high-risk group. *J Neurosurg* 1997; 87:512-5.
10. du Trevou M, Bullock R, Teasdale E, Quin RO. False aneurysms of the carotid tree due to unsuspected penetrating injury of the head and neck. *Injury* 1991; 22:237-9.
11. Kieck CF, de Villiers JC. Vascular lesions due to transcranial stab wounds. *J Neurosurg* 1984; 60:42-6.

12. Benoit BG, Wortzman G. Traumatic cerebral aneurysms. Clinical features and natural history. *J Neurol Neurosurg Psychiat* 1973; 36:127-38.
13. Eichler A, Story JL, Bennett DE, Galo MV. Traumatic aneurysms of a cerebral artery. Case report. *J Neurosurg* 1969; 31:72-6.
14. Fleischer AS, Patton JM, Tindall GT. Cerebral aneurysms of traumatic origin. *Surg Neurol* 1975; 4: 233-9.
15. Handa J, Shimizu Y, Matsuda M, Handa H. Traumatic aneurysms of the middle cerebral artery. *AJR* 1970; 109:127-9.
16. Cressman MR, Hayes GJ. Traumatic aneurysm of the anterior choroidal artery. *J Neurosurg* 1966; 24:102-4.
17. Ferry DJ, Kempe LG. False aneurysms secondary to penetration of the brain through orbito-facial wounds. Report of two cases. *J Neurosurg* 1972; 36:503-6.
18. Lukin R, Chambers A. Traumatic aneurysm of peripheral cerebral artery. *Neuroradiology* 1974; 8:1-3.
19. Parkinson D, West M. Traumatic intracranial aneurysms. *J Neurosurg* 1980; 52: 11-20.
20. Acosta C, Williams PE, Clark K. Traumatic aneurysms of the cerebral vessels. *J Neurosurg* 1972; 36:531-6.
21. Asari S, Nakamura S, Yamada O, Beck H, Sugatani H, Higashi T. Traumatic aneurysms of peripheral cerebral arteries: Report of two cases. *J Neurosurg* 1977; 46:795-803.
22. Damasio H, Grabowski T, Frank R, Galaburda AM, Damasio AR. The return of Phineas Gage: clues about the brain from the skull of a famous patient. *Science* 1994; 264:1102-5.