

## Mount Fuji Sign in tension pneumocephalus

Amit Thapa MS, Deepak Agrawal M Ch

Department of Neurosurgery, All India Institute of Medical Sciences, New Delhi

A 64-year-old male reported 36 hours after sustaining injuries to head and face in a road-traffic accident. He was conscious and alert with Glasgow Coma Scale of 15/15. Non-contrast computed tomography (NCCT) head revealed fracture of frontal sinus extending to right orbital roof with pneumocephalus depicting classical Mount Fuji sign (Fig 1). Since patient was neurologically intact and did not have any cerebrospinal fluid leak, he was managed conservatively with decongestants and oxygen by mask. Recovery was uneventful with resolution of pneumocephalus.

Tension pneumocephalus is a neurosurgical emergency, characterized by intracranial subdural air causing mass effect on the brain and. It is seen more often after evacuation of subdural hematoma (2.5- 16% of cases)<sup>1,2</sup>. Tension pneumocephalus forms after air enters via fractured skull base or sinus and gets trapped within the subdural space. A ball-valve mechanism allows for further trapping of air which causes mass effect. With the advent of CT, radiologists attempted to explain the mass effect generated by pneumocephalus on the basis of volume of air trapped inside the cranium. Pop et al described a "peaking sign" of bilateral compression of frontal lobe by subdural air collection without the characteristic separation of frontal lobe<sup>3</sup>. The Mount Fuji sign was further described as bilateral subdural hypoattenuation collections causing compression and separation of frontal lobe (widened inter-hemispheric fissure), with separated frontal lobar tips appearing as symmetrical cone shaped peak of Mount Fuji<sup>1</sup>. As air pressure is greater than the surface tension of CSF between the frontal lobes, they get separated. Ishiwata et al found this sign useful in diagnosing tension pneumocephalus, as it was not seen in any patient with non-tension pneumocephalus<sup>1</sup>.

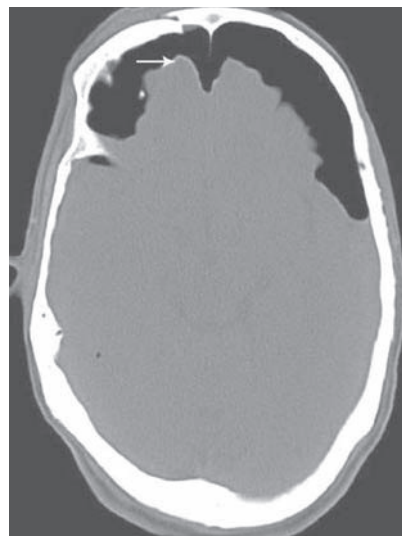


Fig 1 : Non-enhanced CT image of brain showing fracture of frontal bone with bilateral frontal subdural hypoattenuation with compressed and widely separated frontal lobar tips (see arrow)

We however believe that tension pneumocephalus can only be diagnosed when radiographic imaging is coupled with neurological deterioration. Conditions like diffuse cerebral atrophy may not only provide ample space for pneumocephalus to expand but also radiologically give the impression of brain being under mass effect.

Patient should be observed intensively with little threshold for emergent decompression to alleviate pressure on the brain parenchyma. Decompression can be achieved by drilling burr hole, craniotomy, needle aspiration or ventriculostomy. 100% oxygen should be administered and dural defect should be closed if possible<sup>4,5</sup>.

### REFERENCES

1. Ishiwata Y, Fujitsu K, Sekino T, et al. Subdural tension pneumocephalus following surgery for chronic subdural hematoma. *J Neurosurg* 1988; 68:58-61
2. Bremer AM, Nguyen TQ. Tension pneumocephalus after surgical treatment of chronic subdural hematoma: report of three cases. *Neurosurgery* 1982; 11:284-7

*Indian Journal of Neurotrauma (IJNT), Vol. 6, No. 2, 2009*

#### Address for correspondence

Dr Amit Thapa – Senior Resident  
Department of Neurosurgery  
All India Institute of Medical Sciences, Ansari Nagar  
New Delhi- 110029, Phones: 91-9968411005  
Email: dramitthapa@yahoo.com

3. Pop PM, Thompson JR, Kinke DE, et al. Tension pneumocephalus.  
*J Comput Assist Tomogr* 1982; 6:894-901.
4. Campanelli J, Odland R. Management of tension pneumocephalus caused by endoscopic sinus surgery.  
*Otolaryngol Head Neck Surg* 1997; 116:247-50
5. Artru AA. Nitrous oxides play a direct role in the development of tension pneumocephalus intraoperatively.  
*Anesthesiology* 1982; 57:59-61.