

Coronal fracture of cervical spine

Harjinder S Bhatoe M Ch

Department of Neurosurgery, Army Hospital (R & R)
Delhi Cantt 110010. New Delhi

A 28-year-old male fell from a two-wheeler and was admitted with constant neck pain and restriction of cervical spine movements. There was no neurological deficit. Cervical spine radiograph and CT cervical spine revealed vertical coronal fracture of the C4 vertebral body (Figs 1 & 2), with anterior displacement of the fractured fragment. Posterior cortex and spinal canal were uninvolved. He also had fracture of spinous process of C4 vertebra.

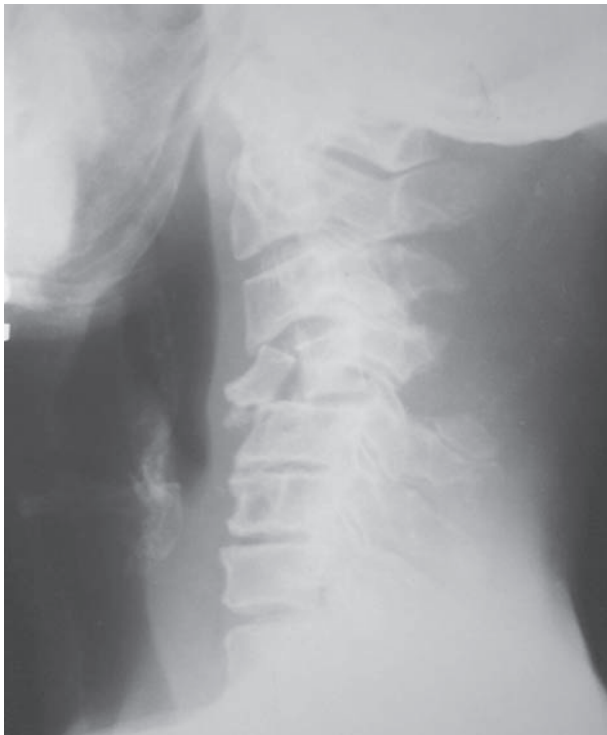

Fig 1: X-ray cervical spine showing C4 fracture

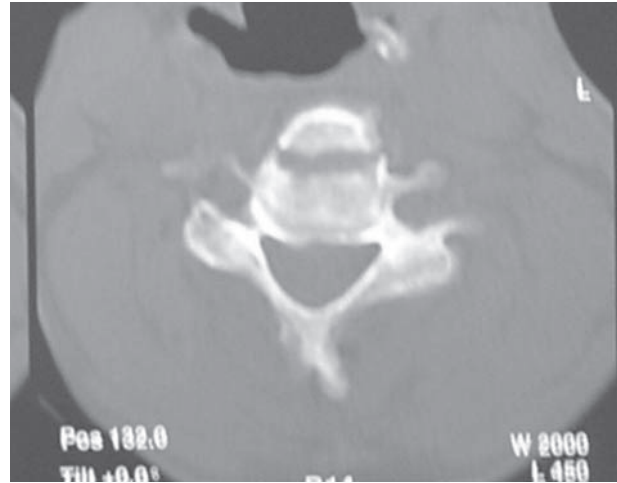


Fig 2: CT showing coronal fracture C4

He was managed at a peripheral hospital conservatively with analgesics and cervical spine brace for 12 weeks. When reviewed nine months later, he was pain-free but had restriction in neck movements.

The fracture depicts the direction taken by vectors from flexion strain to the cervical spine. Though not fitting into any conventional classification schema, the fracture is unique since with such severe stress, the middle column of the spine was intact with injury to posterior elements as well as anterior column, and neither spinal canal nor spinal stability was compromised.

Address for Correspondence:

Harjinder S Bhatoe M Ch
Department of Neurosurgery
Army Hospital (R & R), Delhi Cantt 110010. New Delhi