

Spontaneous bullet migration- uncommon sequelae of firearm injury to the brain

Raj Kumar M Ch, Pallav Garg M S, Vijendra Maurya M S, Rabi Narayan Sahu M Ch, A K Mahapatra M Ch

Department of Neurosurgery
Sanjay Gandhi Postgraduate Institute of Medical Sciences, Lucknow - 226014

An important though uncommon complication of retained missiles is that of spontaneous migration. A 22 years young man presented to us with alleged firearm injury to head. The bullet migration was evident on the third day after injury when it was seen lying in the left posterior occipital region as compared to previous posterior frontal location. Softening of contused cerebrum along the missile tract and free weight of the bullet due to gravity were probably responsible for the bullet migration in this case. The patient underwent surgical exploration and progressively recovered. This case report emphasizes the fact that spontaneous migration of a foreign body inside the cranium should be watched for, resulting in damage to vital structures producing significant neurological damage. The presence of migration should be considered to be an urgent indication for surgical intervention.

INTRODUCTION

With continuously increasing episodes of violence around the world the frequency of firearm injuries involving the brain are on an ever increasing trend¹. Bullet injuries to head need special attention in view of the ballistics and requirement of prompt decisions regarding surgical removal. The neurological status at time of presentation and the location of the bullet often dictates the decision regarding surgical removal. However an important though uncommon complication of retained missiles is that of spontaneous migration. We report a case of spontaneous migration of bullet injury and review the relevant literature.

CASE REPORT

A 22-year-old male presented with alleged firearm injury to the head. There was a single stitched entry wound in the left occipital region. Brain tissue was seen through the open wound. GCS of the patient at time admission was E3V1M5 with spontaneous movements seen in left sided limbs. Extensor response to pain was present in right upper limb with no movement in the lower limb. Pupils were equal reacting, and vitals were stable. CT brain showed the bullet in left posterior frontal region

and small hematomas seen in the frontal and parietal lobes (Fig-1). Fracture could be seen at site of entry in the left occipital region. The entry wound was debrided and stitched. Patient was treated conservatively with antibiotics, antiepileptics and anti edema measures. On this aggressive anti edema therapy patient showed initial improvement but on 4th day, repeat scan showed migration of the bullet to the posterior left occipital region with thin streak of bleed along the suspected track of migration (Figs - 2a and 2b). On fifth day of admission the patient had worsening of neurological status, following which a CT was done. This time the bullet had migrated further posteriorly to lie at the site of entry of the firearm wound (Fig-3). The edema and midline shift had increased. Patient was taken up for surgery. Intraoperatively the bullet's location was confirmed with fluoroscopic guidance after positioning of the patient. Surgery was performed in two steps: first the site of gunshot was explored. The fractured bony segments were

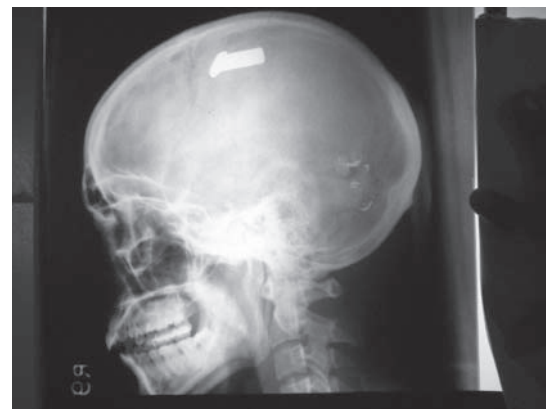

Fig1: Plain x-ray skull showing Bullet in frontal lobe

Address for correspondence:

Raj Kumar
Professor, Department of Neurosurgery
Sanjay Gandhi Post Graduate Institute of Medical Sciences
Lucknow - 226014, U.P.
Phone No. 0522-2668700, 2668800 Ext. 2157 (C), 2158 (R),
2107 (OT), 2741 (O), Fax No.: 91(522) 2668129 & 2668017
e-mail: rajkumar@sgpgi.ac.in, rajkumar1959@gmail.com

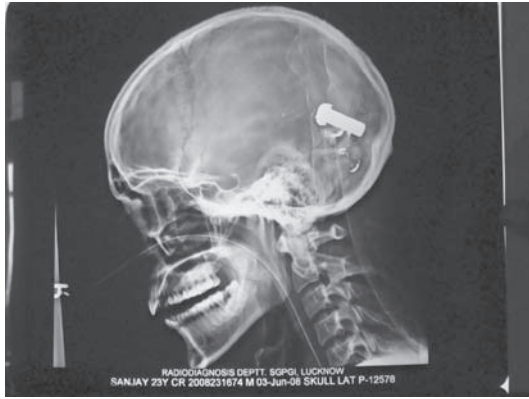

Fig 2A: Plain x-ray skull showing bullet migration to occipital lobe.

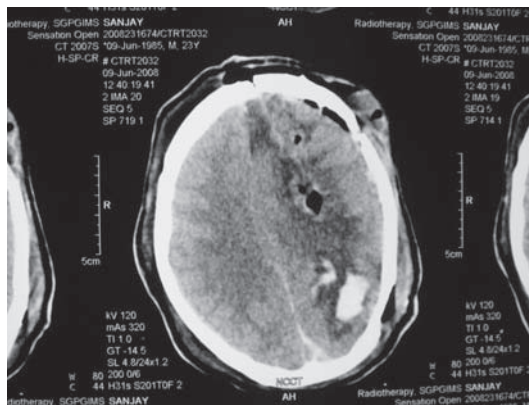


Fig 2B: CT scan brain axial section showing bullet migration path.

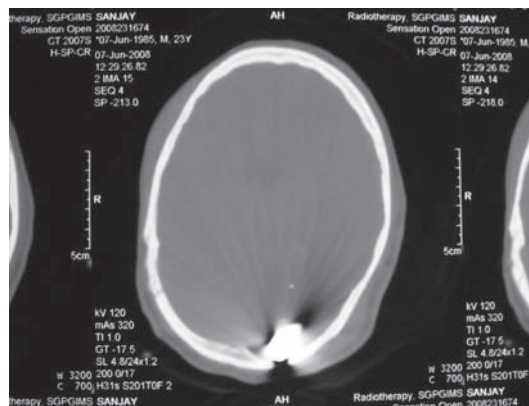


Fig 3: Plain CT scan brain axial cuts showing bullet at the site of entry in occipital lobe

removed, decompression of the contused brain was done and the bullet was retrieved with blunt instruments. Then a left frontal craniotomy was done and the hematoma was evacuated. Brain was seen pulsating well at the end of hematoma evacuation. Postoperative CT showed decrease in edema and midline shift. In the post operative period the patient showed gradual recovery and was

verbalizing and accepting food orally. E4V4M6 was the GCS at time of discharge. The right-sided weakness was persistent.

DISCUSSION

Firearm injuries have become much more common with ready availability of the firearms in the society. The management of these injuries needs to be studied in detail in order to intervene during the course of the treatment at the right moment. The cases need to be treated on individual basis with few basic guidelines. Most of the decisions are dependent upon the course of the recovery within the hospital. Removal of the bullet should be done for patients undergoing surgery for wound debridement or evacuation of intra or extra axial fluid collection provided the bullet is in the vicinity and easily accessible and removal of which should not lead to further deterioration in the neurological status due to its proximity to vital structures³. Secondary sequelae such as abscess formation, ventriculitis, focal seizures or migration are further indications warranting surgical intervention.

Spontaneous migration of the projectile in the cerebral parenchyma is an uncommon complication of bullet injuries. Various theories have been put forward regarding the same. Gravitational factor has been suggested to be a cause for the caudal migration especially in the absence of significant cranial swelling and minimal increase in intracranial pressure⁴. Cerebral softening has also been mentioned as a cause which permits the migration. Some authors have suggested the ventricular system to be the ferry for transportation of the bullet from one area of the brain to the other⁵.

Rengachary et al described spontaneous posterior migration of the bullet to more dependent position⁶. Interestingly enough, the orientation of the bullet however remained unchanged. G.Alessi et al have described spontaneous version and anterior migration of the bullet again with the orientation of the bullet remaining unchanged². Ross D et al have reported two cases of spontaneous migration of retained bullets⁷. Both these patients showed neurological deterioration and CT scans revealed migration of the bullets. The patients underwent immediate surgical removal of the bullet following which the patients demonstrated significant functional recovery. In our case bullet migration was evident on the third day after injury when it was seen lying in the left posterior occipital region as compared to previous posterior frontal

location. The streak of hematoma going posteriorly was suggestive of the track the bullet had taken to traverse the parenchyma. No transventricular evidence of migration was seen. Hence in our case cerebral softening with gravity were probably responsible for the bullet migration. The bullet migration continued till on the seventh day the bullet was seen lying at the entry wound making the bullet easily accessible. The decision to operate was taken due to the easily accessibility of the bullet as suggested by the CT and due to progressively increasing edema with midline shift and worsening neurological status. It was important to confirm the location of the bullet just before the incision after the final positioning of the patient which was duly done with fluoroscopic guidance. Patient significantly improved following the surgery.

Surgical treatment of bullet injuries needs be decided on individual basis with intraoperative localization being essential. Spontaneous migration though uncommon should be watched for as it may be responsible for damage to vital structures producing significant neurological damage. The presence of migration should be considered to be an urgent indication for surgical intervention.

REFERENCES

1. Karabagali Hakan. Spontaneous movements of bullets in the interhemispheric region.
Ped Neurosurg; 41: 148-50.
2. G Alessi, S Aiyer, N Nathoo. Home made gun injury: spontaneous version and anterior migration of bullet.
Br J Neurosurg 2002;16:381-4.
3. Hammon WM. Analysis of 2187 consecutive penetrating wounds of the brain.
J Neurosurg 1971; 34:142-4.
4. RappLG, Arce CA, McKenzie R. Incidence of intracranial bullet fragment migration.
Neuro Res 1999; 21: 475-80.
5. Salvati M, Cervoni L, Rocchi G, Rastelli E, Delfini R. Spontaneous movement of metallic foreign bodies.
J Neurosurg Sci 1997; 41: 423-25.
6. Rengachary SS, Carey M, Templer J. The sinking bullet.
Neurosurgery 1992; 30: 291-5.
7. Ross D, Zafonte DO, Thomas Watanabe, Nancy R. Mann. Moving bullet syndrome: A complication of penetrating head injury.
Arch Phys Med Rehab 1998; 79:1469-72.