

Fatal penetrating orbitocerebral injury by bicycle brake handle

M S Gopalakrishnan M Ch, B Indira Devi M Ch*

Neurosurgery division

Jawaharlal Institute of Postgraduate Medical Education and Research [JIPMER] Pondicherry &

*Department of Neurosurgery, NIMHANS, Bangalore

Abstract: Accidental penetrating head injuries are rare but significant cause of morbidity in children. We report a case of a nine-year-old who sustained a fatal trans-orbital penetrating injury following a fall from bicycle. The plastic sheath of the metal brake handle was lodged intracranially, injuring the brainstem. The CT scan features and autopsy findings are described.

Keywords: head injury, penetrating head trauma, traumatic subarachnoid hemorrhage

INTRODUCTION

Although head injuries are a common cause of accidental trauma in children, penetrating head trauma is rare. Children are vulnerable to penetrating head trauma during falls. We report a case of a nine-year-old who sustained penetrating injury by a bicycle brake handle.

Case report

A nine-year-old boy was brought to the emergency room with history of fall from a bicycle three hours before. He was decerebrating to pain with no verbal response or eye opening. There was a small lacerated wound measuring 3 X 1 cm on the left cheek which was oozing blood and his left eye was black and swollen. Right pupil was widely dilated and was not reacting to light. He had stable hemodynamics at admission.

He was immediately intubated and ventilated. An emergency CT scan was done which revealed the true extent of the injury (Fig 1). A linear hyperdense foreign body was found lodged intracranially which appeared to penetrate the left orbit, ethmoid and sphenoid sinuses. Its distal end had penetrated through the right side of the cerebral peduncle reaching the tentorial hiatus. There was thick diffuse basal subarachnoid bleed and an established right posterior cerebral artery territory infarct. 3D reformatted images showed the trajectory of the foreign body. Child expired within two hours.

Address for Correspondence:

B Indira Devi M Ch
Department of Neurosurgery,
National Institute of Mental Health and Neurological Sciences,
Bangalore 560029(Karnataka)
Email: bindira@nimhans.kar.nic.in

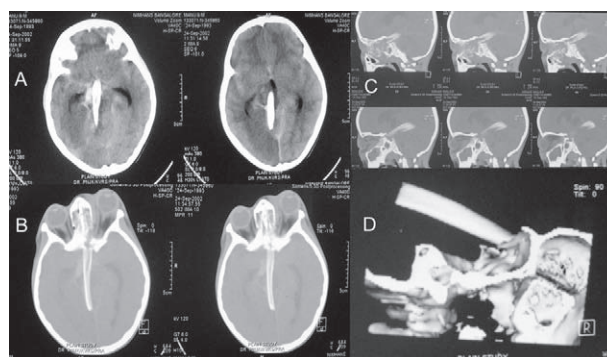


Fig 1A: Plain Ct scan showing the hyperdense intracranial foreign body. Notice the thick subarachnoid bleed and established posterior cerebral artery territory infarct. B- bone window showing fractured ethmoid bone and proptosed left eye. C- sagittal reconstruction shows the trajectory of the object D- 3D rendering of the base of skull in relation to the foreign body.

Autopsy examination revealed that the foreign body was the green plastic sheath of the metal brake handle of the bicycle (Fig 2). The brake handle had penetrated through the cheek, traversed the orbital cavity, ethmoid and sphenoid sinuses and had lacerated through the cerebral peduncle injuring the posterior cerebral artery on the right side. The handle had come out after injuring the brain during the fall leaving its plastic sheath behind.

DISCUSSION

Penetrating head injuries have higher mortality and morbidity than blunt trauma even in civilian set up. Case fatality rates are higher for penetrating than closed injuries for all GCS, gender, age, and cause of injury categories¹. Most common sites for entry wound are the temporal area and orbit where the bone is thin². Penetrating intracranial injury due to bicycle hand brake has been reported in two cases^{3,4} previously and one of them had

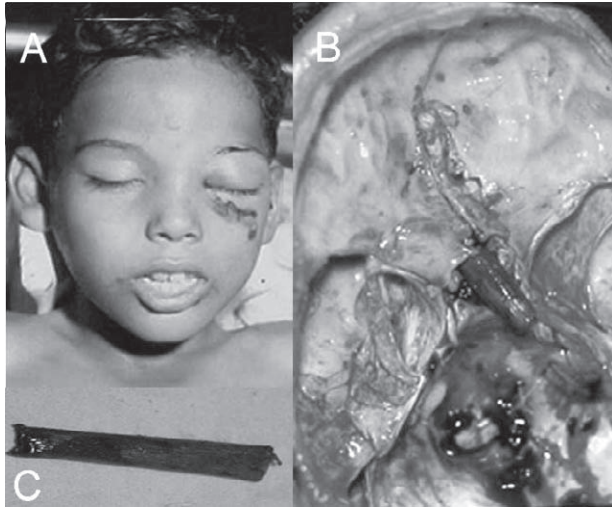


Fig 2A: Site of injury by the bicycle handle below the black proptosed eye. B- Position of the foreign body at autopsy. C – The foreign body was the green plastic sheath of bicycle brake handle.

brainstem injury with fatal consequence³. The poor neurological status at presentation and the nature of injuries precluded any hope for salvage which would have required further investigation with CT angiogram and operative extraction of the foreign body or extraction under CT imaging guidance as previously reported for successful removal of an intracranial pencil⁵. Diffuse subarachnoid hemorrhage was seen in our case and is known to be associated with a poor outcome⁶. Safer design of bicycles and other toys used by children, avoiding sharp ends, goes a long way in preventing such devastating injuries. CT scan with reconstructed images and CT angiogram help in planning operative approach for extracting intracranial foreign bodies.

CONCLUSION

Penetrating injuries are rare in children in a civilian setting. This is the third reported case of bicycle brake handle causing deep penetrating orbitocerebral injury during a fall. Imaging and autopsy findings reveal the true extent of the intracranial injury. Safer design of bicycles and other toys help prevent such injuries.

REFERENCES

1. Peek-Asa C, McArthur D, Hovda D, Kraus J. Early predictors of mortality in penetrating compared with closed brain injury. *Brain Inj* 2001;15:801-10.
2. Faraji M, Ashrafzadeh, Farah. Penetrating Head Injuries in Children. *Neurosurgery Quarterly* 2005;15:160-3.
3. Ahmad FU, Suri A, Mahapatra AK. Fatal penetrating brainstem injury caused by bicycle brake handle. *Pediatr Neurosurg* 2005;41:226-8.
4. Ng JD, Payner TD, Holck DE, Martin RT, Nunery WT. Orbital trauma caused by bicycle hand brakes. *Ophthal Plast Reconstr Surg* 2004;20:60-63.
5. Ildan F, Bagdatoglu H, Boyar B, Doganay M, Cetinalp E, Karadayi A. The nonsurgical management of a penetrating orbitocranial injury reaching the brain stem: case report. *J Trauma* 1994;36:116-8.
6. Levy ML, Rezai A, Masri LS, Litofsky SN, Giannotta SL, Apuzzo ML, Weiss MH. The significance of subarachnoid hemorrhage after penetrating craniocerebral injury: correlations with angiography and outcome in a civilian population. *Neurosurgery* 1993;32:532-40.