

# The DREZ Surgical Treatment of chronic pain in traumatic paraplegia

Milan Spaic M.D.\* , Ph.D., Nada Markovic\*\* , Dusan Mikicic\*\*\* ,  
Srbislav Ilic M.D.# , Ph.D, Ivica Milosavljevic M.D.#.

\*Department of Neurosurgery, Military Medical Academy, Belgrade, Serbia and Montenegro

\*\*Institute for Mental Health and Military Psychology, Military Medical Academy, Belgrade, Serbia and Montenegro

\*\*\*Institute for Fluid Mechanics, Electronic Faculty, University of Belgrade, Serbia and Montenegro

#Institute of Pathology, Military Medical Academy, Belgrade, Serbia and Montenegro

**Abstract:** The Microsurgical DREZotomy, as a curative surgery in treating paraplegic pain, has been established on the basis of the functional anatomy of the Dorsal Root Entry Zone (DREZ) and aims at a lesion of the dorsal-most layers of the dorsal horn of the deafferented cord segments, shown to be involved in pain generating. According to the postulate that the long-term result of the DREZ surgery for the paraplegic pain depends on the accuracy, size and completeness of the dorsal horn lesion, we developed the lesioning technique based on the natural differences in mechanical properties between the white and gray cord substances, that allowed for the selective and safe suctioning of the dorsal horn gray substance under the visual microsurgical control. The utility, selectivity and safety of the dorsal horn suction technique has been provided by the natural mechanical properties of the cord tissue itself. The comparative results of treating paraplegic pain using two lesioning techniques are reported.

The total of 38 patients with chronic neuropathic pain as the sequela of the spinal gunshot war injuries were treated using DREZ - lesioning. Twenty four of these patients were operated on using the Sindou's Microsurgical DREZotomy technique (MDT), while 14 were operated on using the MDT modified with the dorsal horn suction as a lesioning method. A long term success in treating pain was achieved in 77 % patients operated on using the standard Microsurgical DREZotomy. A successful long-term pain relief was achieved in 85% patients operated on using the dorsal horn suctioning. Our results implied that the size and the shape, i.e. the completeness of the DREZ lesion might play an important role in providing the better long-term result of the DREZ surgery for the paraplegic pain treatment. Intermittent rhythm and defined unilateral or bilateral pain territory were the most significant features of the pain syndrome that was successfully cured by the DREZ surgery.

**Keywords:** dorsal horn suction, DREZ surgery, spinal injury, neuropathic pain

## INTRODUCTION

Paraplegia due to spinal cord trauma is one of the most devastating injuries in human pathology<sup>1</sup>. Even more severe than the paraplegia itself is the syndrome of persistent, incapacitating, posttraumatic neuropathic chronic pain that occurs in 10-30% of the injured<sup>2, 3</sup>. Comparing to the physiologic, nociceptive pain that is caused by the activation of nociceptors in otherwise intact central nervous system - neuropathic pain is produced by the injury or illness of the central nervous system<sup>4</sup>.

Hence, chronic neuropathic pain appears as an illness by itself without any awareness or protective significance that characterizes the role of nociceptive pain in the human

physiology. The final mechanism underlying paraplegic pain phenomenon is the result of deafferentiation that leads to the permanent neurochemical changes in the dorsal horn neurons, thus producing spontaneous discharges of central nociceptive neurons resulting in chronic pain<sup>5</sup>. Chronic neuropathic pain following spine injuries could have different forms of expression. There are several classifications of paraplegic pain based either on its topography (as segmental/at level pain, end-zone pain, diffuse/below level pain), quality (burning, shooting or electrical) or its proposed different neurogenic mechanisms (steady, intermittent, evoked)<sup>6-10</sup>. Pain is the major reason for the failure of rehabilitation after spinal cord injury<sup>11</sup>. Chronic disability associated with chronic intractable pain, as a rule, leads to secondary psychiatric disorders. A successful pain relief remains the essential therapeutic goal aiming to help an individual to reestablish functional life in the posttraumatic period and to prevent psychological deterioration caused by chronic pain.

*Address for Correspondence:* Milan Spaic, M.D., Ph.D. Department of Neurosurgery Military Medical Academy, Crnotravska 17 Belgrade 11000, Serbia and Montenegro  
Fax No + 381 11 666 164, Email : spaicmil@yahoo.com

The Dorsal Root Entry Zone lesion (DREZ) operation is considered to be a curative procedure in treating this pain syndrome. The DREZ lesioning interrupts the mechanism of paraplegic pain through the ablation of the anatomical structure involved in pain generating, i.e. the *dorsal horn* of deafferented cord segments<sup>12</sup>.

The DREZ surgery has been performed by using different technical modalities such as radiofrequency (RF), laser, ultrasound, microsurgical DREZotomy technique (MDT) - creating the size and the shape of the lesion determined by the technical parameters of the respected lesioning technique<sup>12-16</sup>.

We report the results of treating the patients with paraplegic pain caused by war injuries using the two DREZ lesioning techniques, namely: microsurgical DREZotomy and the modality of this surgery, that we developed, with the dorsal horn suction as a lesioning method.

## Patients and Methods

### Patients

In the period April 1997 - May 2003, 38 male patients aged 22-48, mean age 36 years, were operated on using DREZ - lesioning because they suffered from chronic neuropathic pain as the sequela of spinal gunshot war injuries. All the patients were interviewed by using a list of 47 pain descriptors in order to assess sensory structure along with the rhythm of the pain expressed. The topography of the pain was delineated with the pain scheme drawn by the patients. Intensity of the pain was measured by using the Visual Analogue Scale. Actual neurological condition and functional classification of spinal injury was measured according to the American Spinal Injury Impairment Scale. Psychological investigation was performed using the Minnesota Multiphasic Personality Inventory (MMPI).

### Preoperative pain description and assessment

Two distinct qualities of pain were noted: the pain of thermal nature (burning, boiling, baking, warm etc.) and the pain of different qualities of mechanical but not thermal nature (cramping, stabbing, cutting, throbbing, shooting, sharp, incisive, constriction, distraction etc.). The first one was classified as a thermal pain, the second one as a mechanical-nonthermal pain. The pain form consisted of thermal and other mechanical sensory equivalent at the same pain territory was classified as a combined-mechanothermal (m/t) pain syndrome<sup>17</sup>. Based on the pain territory, pain was of either diffuse, (in the whole body below the level of injury) or localized (part of the body and/or extremity) distribution. The patients were considered for the DREZ surgery when the pain lasted for at least six months without relapse, and

was severe enough to disrupt normal daily activities and sleep pattern, requiring routine analgesic and/or narcotic medication.

## The DREZ Operation

### Microsurgical DREZotomy

The MDT technique, introduced by M. Sindou was established on the basis of functional anatomy of the dorsal root entry zone and its sensory modulatory functioning as the first level of the modulation for pain sensation, taking advantage of the spatial segregation of pain from lemniscal fibers in the DREZ that allowed selective interruption of the pain fibers<sup>18</sup>. The MDT technique consists of a typical longitudinal incision of the dorso-lateral cord sulcus (dls) that is 2 mm deep and made at a 45 angle medially and ventrally designed to selectively destroy the nociceptive fibers grouped in the lateral bundle of the dorsal rootlet and the medial, excitatory part of the Lissauer's tract. Subsequent bipolar coagulation inside the incision was performed by using sharp bipolar insulated microforceps, aimed at a lesion of the dorsalmost layers of the dorsal horn. The later is recognized under the surgical microscope by its brown-gray color<sup>16</sup>. Twenty four patients was treated by employing this technique.

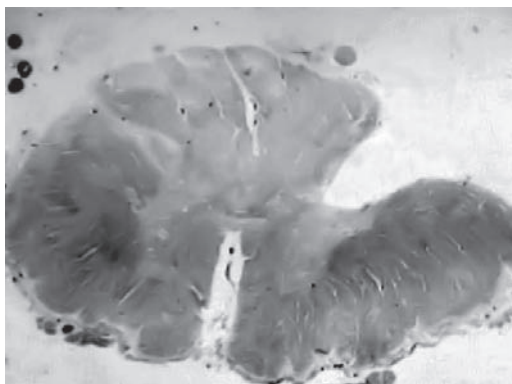
### Development of the dorsal horn suction technique

The MDT aims at a partial lesion of the dorsal horn that includes the dorsalmost layers of the dorsal horn<sup>10, 16</sup>. Considering that the neuropathic mechanism of paraplegic pain has been shown to be generated in the dorsal horn of the deafferented cord segments, we conclude that the more extensive lesion of the dorsal horn including not only dorsalmost layers but its full extent down to its base in the V1 Rexed layer, should provide better results in treating pain, particularly in the long term period. A new lesioning technique has been developed based on the natural biological difference in tissue elasticity between the white and gray substance of the spinal cord. Our experimental investigation and measurements of the mechanical properties of the human cadaveric cord tissue revealed that the white cord substance with longitudinal fiber structure had four time higher dynamical viscosity than the gray substance of the local neuronal network structure (150 Pascal/second (PaS) versus 37.5 PaS)<sup>19</sup>. Thereafter, the MDT technique has been modified in such a way that the suction of the dorsal horn gray substance has been performed, under the visual microsurgical control, instead of the bipolar coagulation (MDT-DHS)<sup>20</sup> (Table 1). The differences in tissue elasticity of the spinal cord gray and white matter allowed for the selective and safe suctioning

**Table 1. The Microsurgical DREZotomy: the two DREZ lesioning techniques**

Microsurgical DREZotomy	Microsurgical DREZotomy-Dorsal horn suction
1. Incision of the dls	1. Incision of the dls
2. Bipolar coagulation of the dorsal horn dls-dorsolateral cord sulcus	2. Dorsal horn suction

of the gray matter of the dorsal horn. The histological findings revealed that the suction of the dorsal horn gray substance provided the complete and reliable DREZ lesion (Fig 1). The application of the dorsal horn suction technique on humans has been approved by the Institutional Ethics Committee. We operated on 14 patients by using this technique.



**FIGURE 1:** The DREZ lesion achieved using the dorsal horn suctioning - the cadaveric cord specimen

### The surgical technique

The microsurgical DREZ lesioning was performed on the cord segments corresponding to the territory of the pain in the cases of localized pain topography. In cases of diffuse pain below the level of the spinal lesion the DREZotomy was performed from the one cord level above the site of injury along to the S1 cord segment bilaterally. Mobilization of the roots fascicles to provide the access to the ventral aspect of the DREZ was sometimes very tedious, particularly on the territory of gunshot cord injuries, due to the arachnoidal gelatinous thickening and firm adherence of rootlets to cord surface, making preservation of vascular network of the dorsal cord surface as a significant technical challenge. However, it was possible to have access to dorsolateral sulcus in all the cases by employing the microsurgical technique under the high magnification. The final stage of the surgery was a longitudinal incision along dorsolateral sulcus (dls) at the selected cord segments. In the cases operated on using the microsurgical DREZotomy technique, following incision of the dls, coagulation was performed

by using a sharp bipolar insulated microforceps directed toward the dorsal horn gray substance in the opened incision sulcus. In the cases operated on using the dorsal horn suction lesioning, the suction of the dorsal horn gray substance was performed under the visual control in the opened incision sulcus instead of the bipolar coagulation.

During the lesioning procedure, the suction tip measured 0.8 mm followed the dorsal horn appearing as the band of the gray substance, reaching gradually the massive portion of the central gray substance, which could be noted under 20 times microscopic magnification in each of the operated on cases. After the cord surgery, the wound was closed in layers without epidural drainage, in order to prevent the development of the CSF fistula.

### Success in treating pain

Pain relief as a result of DREZ surgery was assessed by the patients themselves using the Visual Analogue Scale as a percent of the residual pain compared with the preoperative pain level. In the postoperative period, all the patients were followed up clinically by the outpatient review. The success in pain treatment has been defined as the patient who experienced a 50% or a higher reduction in pain after the surgery, so that the pain no longer interferes with his activities of daily living and sleeping pattern and no longer requires routine analgesic/narcotic pain medication<sup>17</sup>.

### Statistical analysis

Statistical analysis included Fishers exact test and Chi square test. Differences were considered significant at  $p < 0.05$ .

## RESULTS

There were 21 patients with ASIA grade A, 8 patients with grade B, and 9 with grade C.

For the last follow-up review the two patients from the group operated on using the MDT were lost. The MMPI interview revealed more or less higher level of the anxiety, hypochondriasis and depression scale for all the patients interviewed. Initial pain relief was reported by 22 (91 %), and the long-term pain relief was reported by 17 (77%) patients operated on using the standard MDT technique. All of the 14 patients operated on using the MDT-DHS reported initial, while 12 (85%) of them reported a satisfactory pain relief in a long-term period.

Complete long-term pain relief was reported in 9 (64%) patients operated using the MDT-DHS comparing to that in 11 (50%) of the patients operated on using the MDT.

Considering the pain characteristics, the results were as follow: initial pain relief was achieved in all the 17 patients

with the combined m/t pain, while 13(76%) patients reported a long-term pain relief. None of the two patients with the steady thermal diffuse pain reported a satisfactory initial pain relief. Nineteen (19) (100%) patients with mechanical pain reported the initial, while 16 (84%) patients from this group experienced a long-term pain relief (Table 2). Twenty nine (80%) patients of the whole group experienced a successful long-term pain relief.

**Table 2. Long term pain relief: pain nature and the DREZ lesioning technique**

Pain nature	Overall long term pain relief			MDT* long term pain relief			MDT-DHS long term pain relief		
	100%	50%	failed	100%	50%	failed	100%	50%	failed
Mechanical (19)	12	4	1	5/8 (62%)	2	1	7/9 (78%)		2
Mechano thermal (17)	8	5	4	6/12 (50%)	4	2	2/5 (40%)		1 2
Thermal (2)		2			2				
Pain relief > 50%	80%			77%			85%		
Complete pain relief	55%			50%			64%		

MDT- Microsurgical DREZotomy

MDT-DHS - Microsurgical DREZotomy with dorsal horn suction

\* two patients were lost from the follow up

### Treatment-related morbidity

There was no mortality, or surgical complications regarding infection. Cerebrospinal fluid leakage occurred in the 4, and wound dehiscence in 2 patients. Sensations were completely lost in the dermatomes which corresponded to the operated cord segments in 4 (23%) out of 17 patients, who had presented preoperatively with incomplete sensory loss. In 2 (22%) out of 9 patients there was worsening of motor deficit. These side effects were distributed between the two lesioning techniques as follow: sensory loss: MDT- 2 patients, MDT-DHS - 2 patients, motoric loss: MDT-2 patients.

However, two of our patients who presented with incomplete sensory loss preoperatively improved sensibility after the operation. This might be addressed to the radiculolysis and removal of the arachnoidal scarring that we routinely done in the operated spinal cord segments.

## DISCUSSION

### Pain characteristics and results of the DREZ operation

Level of injury probably has a bearing on the incidence of posttraumatic pain. The pain syndrome is seen more often in thoracic (2/38 or 5% of our patients) or thoracolumbar cord/conus injury (36/38 or 95% of our patients). Ninety five percent patients of the whole group developed intense pain after such injuries that might be explained by the fact that the gray substance of the dorsal horn of lumbar intumescentia was the most voluminous so that the capacity

of convulsive discharges from deafferentated neurons is the greatest the injuries involving conus and cauda and cauda equina<sup>21</sup>.

The level of conus and cauda, i.e. the vertebral level of T10-L5 gunshot injuries, was the predilectional level of the injury for the development of the intensive neuropathic pain in our series. At the same time, this level of injury was associated with the pain patterns that were most responsive on the DREZ surgical treatment - that pain had intermittent or fluctuating rhythm, confined territory and mechanical or combined mechanothermal sensory nature. Of the patients, 36(100%) suffered from that form of the pain experienced initially and 29 (80%) reported a long-term pain relief. None of our two patients with the steady thermal diffuse pain reported a satisfactory initial pain relief. The significantly better results were obtained in the patients with the intermittent pain compared to the patients with continuous pain, as well as in the patients with the defined territory of pain compared to the patients with the diffuse topography of pain. We believe that this fact could be related to the underlying neuropathic mechanism of the pain. Intermittent rhythm, as well as a segmental topography implies the segmentally related and convulsive nature of the underlying neuropathic mechanism. The convulsive, intermittent discharges already recorded from deafferentated dorsal horn neurons seem to be the main underlying neuropathic mechanism of the intermittent pain in the confined territory. In other words, the pain form underlined by the segmental neurogenic mechanism was the most favorable for the segmentally-based surgical procedure such as the DREZ surgery. The fact that pain relief by the DREZ surgery could be expected predominantly for the patients with the intermittent pain, has already been reported<sup>21, 22</sup>. The effectiveness of the DREZ surgery was reported by Sindou et al. to be related to the intrinsic characteristics of the pain, such as described by the patients. In the series of 44 patients, only 26% of them with burning pain had a good pain relief compared with 83% of those suffering from paroxysmal attacks and with 90% of those who had two components of pain<sup>23</sup>. Friedman and Nashold<sup>24</sup> in their series of 56 patients using radiofrequency DREZ lesioning, noted that 74% of the patients with localized pain had a good pain relief, while Rath et al<sup>25</sup> in the group of 16 patients had a good pain reduction in 11(69%). Two of our patients with the steady thermal diffuse pain developed such a pain after the thoracic gunshot cord injuries. The DREZ surgery failed to obtain pain relief in these patients although there was some pain reduction initially in one of these patients. The fact of failed segmental surgery in treating this pain form, that was confirmed by other authors also, implying its supraspinal neuropathic mechanism.



It is likely that posttraumatic functional adaptation of the dynamic interactive system of sensory transmission and integration caused by the massive traumatic sensory loss has the capacity to produce subjective equivalents of steady diffuse thermal pain.

Clinical features of the pain expressed seem to be determined by the level and/or nature of the posttraumatic neurobiological changes serving as the underlying neurogenic pain mechanism, so that the segmental/intermittent pain has been underlied by the segmental convulsive dorsal horn neurons discharges while the steady diffuse thermal pain has been related to the permanent disturbance of the central sensory transmission/integration system<sup>17</sup>.

### The DREZ lesioning techniques and results of surgery

The better results achieved using the dorsal horn suction as a DREZ lesioning (85% versus 77%) ( $p>0.05$ ), with respect to the complete pain relief in particular (64% versus 50%) ( $p>0.05$ ), seemed to be in a logical relation with the mechanism of pain shown to be generated by deafferented dorsal horn neurons. The smaller the residual volume of the dorsal horn gray substance, the less likely the reestablishment of the pain mechanism was.

The completeness of the DREZ lesion as an important factor for achieving pain relief was pointed out by Falci et al., who developed a technique for intramedullary electrical neurophysiological guidance in order to perform a complete dorsal horn lesioning<sup>26</sup>.

The utility, selectivity and safety of the dorsal horn suction technique has been provided by the natural mechanical properties of the cord tissue itself. In other words, compared with other DREZ lesioning techniques, the method utilizes the biological principle in the DREZ lesioning. It is doubtful whether the shorter follow-up period for the group operated on using the DREZ lesioning with the MDT-DHS contributed to the better results achieved in treating pain. However, we believe that the more extensive lesion of the dorsal horn, as a pain generating anatomical structure, created with the dorsal horn suction technique accounted for the better results achieved in treating pain.

### CONCLUSION

The DREZ surgery proved to be a causative and efficacious procedure in treating the chronic pain of traumatic paraplegia. The pain of intermittent rhythm and the defined unilateral or bilateral pain territory were the most significant features of pain syndrome successfully cured by the DREZ surgery. Our results imply that the size and the shape i.e. completeness of the DREZ lesion might play an important

role in providing the better long-term result of the DREZ surgery for the treatment of paraplegic pain.

### REFERENCES:

1. Nashold BS. Paraplegia and pain. In: Nashold BS, Ovelmen-Levitt J, eds. Deafferentation pain syndromes: patophysiology and treatment. *Advances in pain research and therapy*, Vol 19, Raven Press Ltd, New York(1991), pp 301-330
2. Botterell EH, Callaghan JC, Jousse AT. Pain in paraplegia. Clinical management and surgical treatment. *Proc R Soc Med* 1954; 47:281-8.
3. Tasker RR, De Carvalho GTC. Central pain of spinal cord origin. In: North BR, Levy RM (editors) *Neurosurgical Management of Pain*. New York. Springer-Verlag 1997: 110-117.
4. Bowsher D. Central pain of spinal origin. *Spinal Cord* 1996; 34: 707-10.
5. Ovelmen-Levitt J. The neurobiology of the Spinal Cord Dorsal Horn and Patophysiology of Neuropathic Pain. In: Nashold BS, Pearlstein RD (eds) *The DREZ Operation*. Illinois, Park Ridge: American Association of Neurological Surgeons 1996, pp 13-27
6. Bullitt E, Friedman AH. DREZ lesions in the treatment of pain following spinal cord injury. In: Nashold BS et al (eds) *The DREZ Operation*. The American Association of Neurological Surgeons, Parke Ridge, Illinois 1996; pp 125-37.
7. Friedman AH, Nashold BS. DREZ lesions for relief of pain related to spinal cord injury. In: Youmans Y. (ed) *Neurological Surgery*, Vol 6, WB Saunders, Philadelphia, 1990; pp 3950-9.
8. Nashold BS, Friedman A, Bullitt E. The status of Dorsal Root Entry Zone Lesions in 1987. *Clin Neurosurg* 1989;35: 422-8.
9. Sidall PJ, Taylor DA, Cousins MJ. Classification of pain following spinal cord injury. *Spinal Cord* 1997; 35: 69-75.
10. Gorecki JP. Dorsal Root Entry Zone and Brainstem Ablative Procedures. In: Winn RH (editor) *Youmans Neurological Surgery*, fifth edition, Philadelphia; Saunders, 2004, pp. 3045-58.
11. Mariano AJ. Chronic Pain and Spinal Cord Injury. *Clin J Pain* 1992; 8: 87-92.
12. Nashold BS. Clinical Applications of the DREZ Operation: General Introduction In: Nashold BS, Pearlstein RD (eds) *The DREZ Operation*. Park Ridge, Illinois: American Association of Neurological Surgeons 1996, pp 47-73.
13. Dreval ON. Ultrasonic DREZ-Operations for Treatment of Pain Due to Brachial Plexus Avulsion. *Acta Neurochir (Wien)* 1993; 122: 76-81.
14. Powers SK, Adams JE, Edwards SB, Boggan JE, Hosobuchi Y. Pain relief from dorsal root entry zone lesions made with argon and carbon dioxide microsurgical lasers. *J Neurosurg* 1984; 61: 841-7.
15. Young RE. Clinical experience with radiofrequency and laser DREZ-lesions. *J Neurosurg* 1990; 71: 715-20.

16. Sindou M. Microsurgical DREZotomy for pain, spasticity and hyperactive bladder: rationale, surgical technique and indications. *Neurosurgery* 1997; 16: 74-83.
17. Spaic M, Markovic N, Tadic R Microsurgical DREZotomy for Pain of Spinal Cord and Cauda Equina Injury Origin: Clinical Characteristics of Pain and Implications for Surgery in a Series of 26 Patients. *Acta Neurochir (Wien)* 2002; 144: 453-62.
18. Sindou M, Quoex C, Baleyrier C. Fiber organization at the posterior spinal cord-rootlet junction in man. *J Comp Neurol* 1974; 153: 15-26.
19. Mikicic D, Spaic M. Biomechanical Characteristic of the Spinal Cord. *Bulletins for Applied & Computer Mathematics* 2002; XCIX: 168-74.
20. Spaic M, Mikicic D, Ilic S, Milosavljevic I, Ivanovic S, Slavik E, Antic B. Biomechanical Properties of the Spinal Cord Tissue - Biological Basis for the Modified Technique of the DREZ Operation. *Acta Chirurgica Iugoslavica ACI* Vol. LI, 2004; 59-65 (in Serbian)
21. Jeanmonod D, Sindou M. Somatosensory function following dorsal root entry zone lesions in patients with neurogenic pain and spasticity. *J Neurosurg* 1991; 74: 916-32.
22. Tasker RR, De Carvalho GTC, Dolan EJ. Intractable pain of spinal cord origin: Clinical features and implications for surgery. *J Neurosurg* 1992; 77: 373-8.
23. Sindou M, Mertens P, Wael M. Microsurgical DREZotomy for pain due to spinal cord and/or cauda equina injuries: long-term results in a series of 44 patients. *Pain* 2001; 92:152-71.
24. Fredman AH, Nashold BS. DREZ lesions for relief of pain related to spinal cord injury. *J Neurosurg* 1986; 65: 465-9.
25. Rath SA, Braun V, Soliman N, Antoniadis G, Richter HP. Results of DREZ coagulations for pain related to plexus lesions, spinal cord injuries and postherpetic neuralgia. *Acta Neurochir (Wien)* 1996; 138: 364-9.
26. Falci S, Best L, Bayles R, Lammertse D, Starnes C. Dorsal root entry zone microcoagulation for spinal cord injury-related central pain: Operative intramedullary electrophysiological guidance and clinical outcome. *J Neurosurg (Spine 2)* 2002; 97: 193-200.