

Is fascicular selection by nerve stimulation techniques a necessity in selective nerve transfers targeted at restoration of elbow flexion in upper brachial plexus injuries?

PS Bhandari MCh, HS Bhatoe MCh

Department of Plastic and Reconstructive Surgery and Neurosurgery,
Army Hospital(R&R) Delhi Cantt and Command Hospital(Western Command) Chandimandir

Abstract: In the restoration of elbow flexion nerve transfers have proven to be superior to muscle or tendon transfers. Biceps and brachialis muscles, the prime elbow flexors, are innervated by musculocutaneous nerve, taking its origin from the lateral cord of brachial plexus. A variety of donor nerves of both intraplexal and extraplexal sources have been used in the neurotization of this nerve. We prefer transfer of two fascicles, one each from ulnar nerve and median nerve, directly to the biceps and brachialis motor branches. Contrary to the previous reports now we do not use nerve stimulation while selecting the ulnar and median nerve fascicles. Twenty two patients with upper plexus (C5 and C6) injuries were treated with bifascicular nerve transfer in the period between Jan 2006 and Aug 2007. All of the patients were males in the age group 18 to 35 years and motor cycle accident was the main cause of injury. The denervation period (time interval between injury and nerve surgery) averaged 5 months. Twenty one patients restored full elbow flexion (140°); one could achieve 110° of antigravity flexion. In MRC grade 16 scored M4 while 6 scored M3. Patients with good results could lift 8 kilograms of weights. In our experience, bifascicular nerve transfer using ulnar and median nerves as donor nerves is the most reliable method of restoring elbow flexion in upper brachial plexus injuries and there is no need of fascicular selection with a nerve stimulator prior to transfer.

Keywords: elbow flexion; fascicular nerve transfer; nerve stimulator

INTRODUCTION

In upper brachial plexus injury reconstructive goals are aimed at restoration of shoulder abduction, external rotation and elbow flexion, and out of these the elbow flexion takes a priority. When upper roots are avulsed or there is irreparable injury to the upper plexus, anatomical reconstruction using nerve grafts is not feasible. In such situations nerve transfers have proven to be superior to muscle or tendon transfers¹.

In the restoration of elbow flexion, a variety of donor nerves of both intraplexal^{2,3} and extraplexal^{4,5,6,7,8,9,10,11} sources have been used with success rates ranging between 15%³ and 100%^{12,13}. In 1994 C Oberlin introduced a new technique of nerve transfer using one or two fascicles of ulnar nerve to the biceps motor branch of musculocutaneous nerve¹⁴. This technique gained lot

of popularity because of its simplicity and achievement of good results. In 1997 Loy et al published a report of 18 patients treated with this technique¹⁵. Most of the cases in this series obtained good elbow flexion with MRC grade 3 to 4, but 5 patients required an additional Steindler flexorplasty to achieve satisfactory elbow flexion. Results were even less satisfactory when there was an associated C7 root injury. Hence the original Oberlin transfer was supplemented with reinnervation of brachialis muscle using a fascicle from the adjacent median nerve^{15,16}. At present, most reports are in favor of double fascicular transfer in regaining elbow flexion in C5, C6 root avulsion injuries^{16,17,18}. However all studies stress on the careful selection of ulnar and median nerve fascicles prior to transfer^{14,15,16,17,18}. Contrary to this we raise a fascicle from the visible surface of the donor nerve which is mobilized to the recipient motor branch without much of inter fascicular dissection. In this article we present our experience with 22 consecutive patients of upper brachial plexus injuries treated by bifascicular transfer wherein fascicular selection was independent of nerve stimulation techniques.

Address for correspondence :

PS Bhandari, Senior Adviser
Department of Plastic and Reconstructive Microsurgery
Army Hospital (Research and Referral), Delhi
Tele : 91-9560295002 Email : doctorbhandari@hotmail.com

PATIENTS AND METHODS

This is a prospective study of 22 consecutive cases of upper brachial plexus injuries presented at our centre in the period between Jan 2006 and Aug 2007. These patients (Figs 1 & 2) were having either C5,C6 root avulsion injuries (8 cases) or irreparable injuries with doubtful viability of the originating roots or upper trunk (14 cases). Most (15) of patients were the victims of motor cycle accidents and all of them were males in the age group 18 to 35 years (average age 24 years). The denervation period averaged 5 months. All patients were subjected to a detailed preoperative assessment which included a methodical clinical examination, electrophysiological studies and 3D MR myelography. Preoperative clinical photographs and video films were obtained as baseline in all patients.

Brachial plexus exploration was done under general anaesthesia. The technique details are mentioned in one of our article¹. The additional nerve transfers targeted towards shoulder included, transfer of distal spinal accessory nerve to suprascapular nerve¹⁹ and long head triceps branch of radial nerve to the anterior branch of

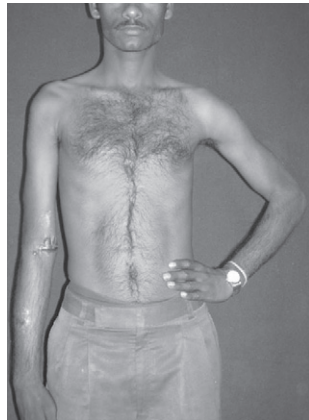

Fig 1: Right sided upper brachial plexus palsy

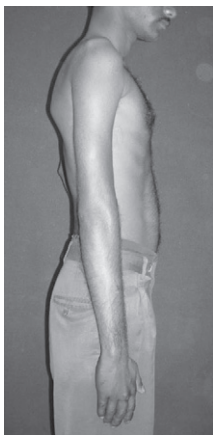


Fig 2: Wasting of shoulder and arm muscles

axillary nerve²⁰. For ulnar and median nerve fascicular transfer, the intermuscular course of musculocutaneous nerve was dissected through a 15 to 20 cm longitudinal incision along the anteromedial aspect of the arm. The branches to biceps and brachialis muscles were identified (Fig 3) and looped in a vascular sling. A longitudinal epineurotomy was made in the ulnar nerve. In earlier cases we used to perform electrical stimulation to isolate a fascicle carrying motor fibers to flexor carpi ulnaris. In subsequent cases any fascicle which was in close vicinity and required minimal interfascicular dissection was flipped to the recipient nerve. Similar methodology was adopted in median nerve fascicular transfer to brachialis muscle (Fig 4). With experience we found that there was no significant donor nerve related morbidity and results in elbow functions were comparable to electrically tested nerves. There was reduction in the operating time and unnecessary dissection of fascicles could be avoided.

POSTOPERATIVE PROTOCOL

Postoperatively the flexed arm was strapped to the chest at 100° flexion for 4 weeks. There after the arm was supported in a cuff-and-collar sling. Passive movements of elbow were started at 4 weeks. With the initiation of flexion movements supination exercises were begun.

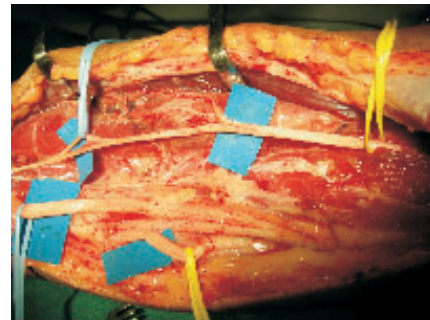


Fig 3: Target nerves (motor nerves to the biceps and brachialis muscles, and ulnar and median nerves) are depicted

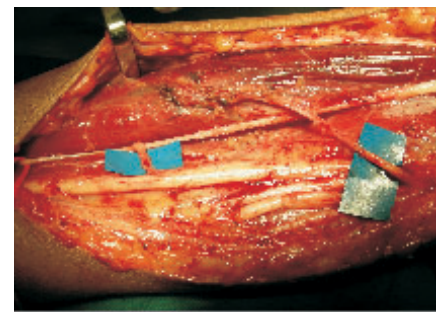


Fig 4: Oberlin transfers; no attempts made to select donor nerve fascicles by nerve stimulation

EVALUATION

Patients were initially evaluated at monthly and subsequently at 3 monthly intervals. The elbow flexion strength was measured using British Medical Research Council grading system (Table 1).

Table 1 : British Medical Research Council grading system

Observation	Muscle Grade
No contraction	0
Flicker or trace of contraction	1
Active movement, with gravity eliminated	2
Active movement against gravity	3
Active movement against gravity & resistance	4
Normal power	5

The ability of the patient to lift weights with shoulder adducted and elbow flexed at 90° were recorded. A complete neurological assessment of hand was also done. Grip strength was measured with a dynamometer.

RESULTS

The study results are depicted in Table 2. The relevant clinical results are shown in Figures 5 and 6.

The mean recovery time for biceps and brachialis muscles were 2.5 months (range 2 to 5) and 3 months (range 3 to 5) respectively. Three patients experienced transient paresthesias in the little and index fingers, which resolved in 2 to 3 months time. Patients with excellent results could lift 8 kilograms of weight with shoulder adducted and elbow flexed at 90°.

DISCUSSION

In C5 and C6 root avulsion injuries since anatomical repair is not possible, reconstruction is aimed at restoration of basic shoulder and elbow functions using nerve transfer techniques. There is a general agreement that nerve transfers offer far superior results than muscle or tendon transfers²¹. In musculocutaneous neurotization fascicular transfers of ulnar and median nerves to the target branches have consistently given good results. While describing the transfer technique most authors still stress on careful selection of donor fascicle(s), mainly with aim of avoiding sensory dominant or more important motor fascicles^{14,15,16,17,18}. This evaluation is best done using a 2-mA nerve stimulator. We also adopted the same technique in initial cases but subsequently found that

Table 2 : Results of bifascicular nerve transfer

Patient	Age	Sex	Surgical delay (In months)	Follow up period (In months)	MRC grade	Elbow Flexion strength(Kg)
1.	20	M	4	24	4	8
2.	21	M	6	26	3	6
3.	33	M	3	23	4	7
4.	19	M	5	25	4	5
5.	30	M	6	24	4	5
6.	18	M	7	28	3	6
7.	35	M	4	24	4	5
8.	20	M	5	28	4	6
9.	26	M	9	26	3	3
10.	29	M	4	24	4	7
11.	30	M	5	23	4	6
12.	29	M	6	27	3	4
13.	21	M	4	24	4	6
14.	19	M	5	26	4	8
15.	23	M	7	24	3	3
16.	21	M	4	26	4	7
17.	20	M	5	24	4	5
18.	18	M	4	26	4	6
19.	27	M	6	24	3	3
20.	29	M	4	28	4	5
21.	20	M	5	24	4	5
22.	19	M	4	26	4	6

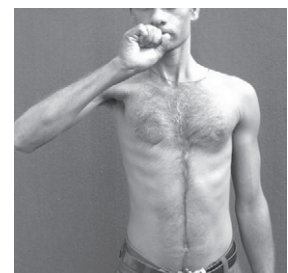


Fig 5: Full range of elbow flexion at 25 months follow up




Fig 6: Elbow flexion strength of 5 kg at 25 months follow up

ultimate functional results and donor nerve related problems were not dependent on fascicular selection by electrical stimulation. Hence we have abandoned the use of nerve stimulator while performing ulnar and median nerve fascicular transfers. This has not only reduced the operating time but also made the procedure more simple. This method of fascicular transfer may be explained by the complexity of the intraneural anatomy of the brachial plexus as described in the beginning of last century by an anatomist Abraham Kerr²². In the arm the fascicular arrangement in relation to the ulnar and median nerves is not constant and changes at every 5mm^{23,24}. Also the fascicles containing mixed motor and sensory fibers are much more common than either pure motor or pure sensory fascicles^{25,26}. These anatomic findings and clinical results support our view point that it is impractical to isolate a pure motor or sensory fascicle in the arm using a hand held nerve stimulator and the functional results and donor nerve related morbidity are independent of fascicular selection.

CONCLUSION

Because of constant intertwining of motor and sensory fibers and a changing fascicular pattern over a short distances in the arm, it is impractical to isolate a pure motor or sensory fascicle(s) by nerve stimulation technique. In our experience functional results and donor nerve related morbidity have no bearing with fascicular identification by electrical stimulation. Hence we have abandoned this technique. This has made bifascicular nerve transfer further simple and a quicker procedure.

REFERENCES

1. Bhandari PS, Sadhotra LP, Bhargava P, et al. Surgical outcomes following nerve transfers in upper brachial plexus injuries. *Indian J Plast Surg* 2009; 42:150-60.
2. Samardzic M, Grujicic D, Rasulic L, Bacetic D. Transfer of the medial pectoral nerve : Myth or reality? *Neurosurgery* 2002; 50:1277 –82.
3. Dai S-Y, Lin D-X, Han Z, Zhoug S-Z. Transfer of thoracodorsal nerve to musculocutaneous or axillary nerve in old traumatic injury. *J Hand Surg* 1990; 15A:36-7.
4. Krakauer JD, Wood MD. Intercostal nerve transfer for brachial plexopathy. *J Hand Surg* 1994; 19A:829 –35.
5. Chuang D C C, Yeh M C, Wei F C. Intercostal nerve transfer of the musculocutaneous nerve in avulsed brachial plexus injuries: Evaluation of 66 patients. *J Hand Surg* 1992; 17A:822 –8.
6. Minami M, Ishii S. Satisfactory elbow flexion in complete (preganglionic) brachial plexus injuries; produced by suture of third and fourth intercostals nerves to musculocutaneous nerve. *J Hand Surg* 1987; 12A:1114–8.
7. Nagano A, Tsuyama N, Ochiai N, Hara T, Takshashi M. Direct nerve crossing with the intercostals nerve to treat avulsion injuries of the brachial plexus. *J Hand Surg* 1989; 14A:980–5.
8. Ogino T, Naito T. Intercostal nerve crossing to restore elbow flexion and sensibility of the hand for a root avulsion type of brachial plexus injury. *Microsurgery* 1995; 16:57 –7.
9. Gu YD, Wu MM, Zheng YL, et al. Phrenic nerve transfer to treat root avulsion of brachial plexus. *Chin Hand Surg* 1989; 5:1-3.
10. Gu YD, Wu MM, Zheng YL, et al. Phrenic nerve transfer for brachial plexus motor neurotization. *Microsurgery* 1989; 10: 287–9.
11. Allieu Y, Cenac AP. Neurotization via the spinal accessory nerve in complete paralysis due to multiple avulsion injuries of the brachial plexus. *Clin Orthop* 1988; 237: 67–74.
12. Songcharoen P, Mahaisavariya B, Chotigavanich C. Spinal accessory neurotization for restoration of elbow flexion in avulsion injuries of the brachial plexus. *J Hand Surg* 1996; 21A: 87–90.
13. Chuang DCC, Epstein MD, Yeh MC, Wei FC. Functional restoration of elbow flexion in brachial plexus injuries : results in 167 patients (excluding obstetric brachial plexus injury). *J Hand Surg* 1993; 18A:285–91.
14. Oberlin C, Beal D, Leechavengvongs S, Salon A, Dauge MC, Saruj J J. Nerve transfers to biceps muscle using part of ulnar nerve for C5 – C6 avulsion of the brachial plexus; anatomical study and report of four cases. *J Hand Surg* 1994; 19A:232-73.
15. Loy S, Bhatia A, Asfazadourian H, Oberlin C. Ulnar nerve fascicle transfer on to the biceps muscle nerve in C5-C6 or C5-C6-C7 avulsions of the brachial plexus: Eighteen cases. *Ann Chir Main Memb Super* 1997; 16:275–84.
16. Mackinnon SE, Novak CV, Myckatyn TM, Tung TH. Results of reinnervation of the biceps and brachialis muscles with a double fascicular transfer for elbow flexion. *J Hand Surg* 2005; 30A:978–85.
17. Liverneaux PA, Diaz LC, Beaulieu JY, Durand S, Oberlin C. Preliminary results of double nerve transfer to restore elbow flexion in upper type brachial plexus palsies. *Plast Reconstr Surg* 2006; 117:915–9.
18. Goubier J, Teboul F. Technique of the double nerve transfer to recover elbow flexion in C5, C6 or C5–C7 brachial plexus palsy. *Techniques In Hand And Upper Extremity Surgery* 2007; 1(1): 15- 7.

19. Chuang DCC, Lee GW, Hashem F, Wei FC. Restoration of shoulder abduction by nerve transfer in avulsed brachial plexus injury: Evaluation of 99 patients with various nerve transfers. *Plast Reconstr Surg* 1995; 96:122–8.
20. Leechavengvong S, Witoonchart K, Uerpaiojkit C, Thuvasethakul P. Nerve transfer to deltoid muscles using the nerve to long head of triceps, part 2: A report of 7 cases. *J Hand Surg* 2003; 28A:633–8.
21. Bhandari PS, Sadhotra LP, Bhargava P, et al. Multiple nerve transfers for the reanimation of shoulder and elbow functions in irreparable C5, C6 and upper truncal lesions of the brachial plexus. *Ind J Neurotrauma* 2008; 5:95–104.
22. Kerr AT. The brachial plexus of nerves in man – the variations in its formation and its branches. *Am J Anat* 1918; 23:285–395.
23. Chow JA, Van Beek AL, Bilos ZJ, et al. Anatomical basis for repair of ulnar and median nerves in the distal part of the forearm by group fascicular suture and nerve grafting. *J Bone Joint Surg* 1986; 68A:273–80.
24. Jabaley ME, Wallace WH, Heckler FR. Internal topography of major nerves of the forearm and hand: A current view. *J Hand Surg* 1980; 5A:1–18.
25. Sunderland S. The intraneural topography of the radial, median, and ulnar nerves. *Brain* 1945; 68:243–99.
26. Slingluff CI, Terzis JK, Edgerton MT. The quantitative microanatomy of the brachial plexus in man. Reconstructive relevance. In Terzis JK ed: *Microreconstruction of nerve injuries*. WB Saunders, Philadelphia. 1987; 285–324.