

Minimally invasive spine surgery in acute dorsolumbar trauma: An experience of 14 cases

Avijit Sarkari MS, Deepak Gupta M Ch, Sumit Sinha M Ch, Ashok Kumar Mahapatra M Ch
Dept of Neurosurgery, JPN Apex Trauma Centre, All India Institute of Medical Sciences, New Delhi 110029.

Abstract: This study evaluates the effectiveness of minimally invasive treatment of dorso-lumbar fractures by percutaneous pedicle screw fixation. Patients of acute traumatic single level dorso-lumbar and spine fractures requiring surgical intervention were included in this study. Fourteen patients (10 male, 4 female), age range 17-47 years (mean 30.1 ± 7.9 yrs) with dorso-lumbar fractures (D9:1, D12:3, L1:9, L4:1) with TLICS score >4 were studied (Feb 2009-Feb 2011). Total of 60 screws were put of which 2 screws were malpositioned (3.3%). Open conversion was done in two cases (15.3%) due to difficulty in rod positioning. In one case, screw pull out was noted intraoperatively during ligamentotaxis and rod manipulation. No patient had post-operative neurological deterioration. Mean post-operative hospital stay was 3.8 days. Follow-up scans showed satisfactory correction of deformity. Good to excellent outcome was present in 84.6%. We conclude that percutaneous pedicle screws fixation is a safe, reliable, cost effective technique with favorable results in acute polytrauma cases requiring standalone ligamentotaxis. Complex biomechanics/physics of instrumentation, lack of adequate fusion and steep learning curve during initial cases with increased radiation exposure limits its application in all cases.

Keywords: dorsolumbar fractures; minimally invasive; pedicle screws; percutaneous

INTRODUCTION

The use of pedicle screws for spinal stabilization is a safe and effective procedure popular worldwide. Prospective randomized trials and community clinical experience have demonstrated increasing fusion rates^{1,2}. Pedicle screw systems engage all three columns of the spine and can resist motion in all planes. Conventional techniques of open lumbar pedicle screw fixation involve a single midline or bilateral paramedian incisions, extending above and below the instrumented levels^{1,2}. Muscle tendon detachment from bone and muscle retraction are necessary and these without question, are source of post-operative pain, muscle atrophy and scar formation^{1,2}. Magerl introduced the technique of percutaneous pedicle screw placement for external fixation of spine in treatment of fractures and osteomyelitis in 1977³. Later much sophisticated minimally invasive instrumentation technique developed as described by Foley in 2002⁴.

Dorso-lumbar spine fractures with or without neurologic deficits are frequent. Present study evaluates the effectiveness of minimally invasive treatment of

dorso-lumbar fractures by percutaneous pedicle screw fixation.

MATERIAL AND METHODS

The present prospective study was conducted at Jai Prakash Narayan Apex Trauma Centre, All India Institute of Medical Sciences, New Delhi from February 2009 to February 2011.

Patients of acute traumatic single level dorso-lumbar spine fractures requiring surgical intervention were included in the study on the basis of thoracolumbar injury classification and severity score (TLICS)⁵. Fourteen patients (10 male, 4 female), age range 17-47 years (mean 30.1 ± 7.9 yrs) with TLICS score of >4 (5.2 ± 0.6) underwent percutaneous instrumentation. NCCT scan of dorsolumbar spine with sagittal, axial and coronal reconstruction was done in all patients. Besides classifying the fracture and canal compromise, it helped in assessing the diameter and angles of pedicle.

Fall from height / staircase was the most common mode of injury in 9 patients followed by road traffic accidents in 4 and in one case the injury occurred by a car jack slipping and falling of vehicle over the back while patient was repairing it from below.

Two patients did not have any weakness in lower limbs and their main complaint was radiculopathy. One patient

Address for correspondence:

Dr Deepak Kumar Gupta
Department of Neurosurgery
JPN Apex Trauma Centre, AIIMS
New Delhi 110029.

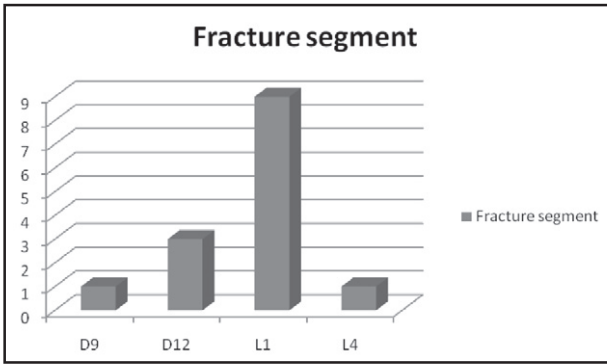


Fig 1: Fracture segment for which surgery was done.

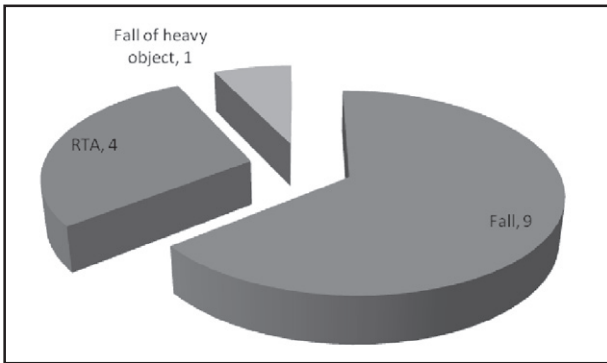


Fig 2: The mode of injury

with D9 fracture had complete paraplegia. Rest 11 cases had power of 4/5 (MRC grading). According to modified Frankel neurological performance scale (ASIA)⁶, the number of cases in Grade A, D and E were 1, 11 and 2 respectively.

The time duration between injury and surgery ranged from 1–18 days (mean 5.5 ± S.D 4.3 days). For intraoperative image guidance, C-arm fluoroscope was used in 12 patients and in 2 cases computer assisted virtual fluoroscopic system O-arm was used. The latter's ability to virtually “extend” the tips of various instruments from the skin surface down to the spine was more helpful.

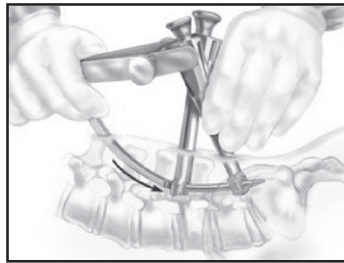
Technique: About 1.5 cm incisions were made after locating the site of screw placement which is a groove at the medial most part of transverse process and its junction with the superior facet process. Polyaxial pedicle screws were placed in the adjacent vertebrae after the trocar, threaded pin, dilators and graduated screw tab. This polyaxial screw is attached to a long arm that will cross the distance between posterior part of pedicle and skin. A locking screw is preloaded into chamber of screw extender; the outer end of latter is attached to the Sextant™ device. After placing two screws, the ends of screw extenders are snapped together. The Sextant device is then attached to the end of screw extender complex with a detachable trochar. The arm is rotated down to skin surface so as to mark the site of a small stab incision. The trocar passes through the stab incision to adipose layer, fascia and bluntly through the muscles to the heads of multi-axial screws. The arm is then rotated back out. Prebent lordotic rod is then attached to the arm and delivered through same fixed arc into side openings of multi-axial screws.

The fixed geometry of screw extender system provides for consistent accurate placement of rod; however it is recommended that a fluoroscopic image should be taken for confirmation. Distractive reduction maneuver of ligamentotaxis are performed, the locking screws previously loaded into screw extender chambers are tightened over the rod to appropriate torque tension. The rod is then detached from the delivery arm and then the arc removed. The whole device is then removed and subcuticular sutures taken. Procedure is repeated on the opposite side.


Details of the symptoms, neurological deficits, operative procedure, intraoperative events, pre-operative and post-operative NCCT scans and X-rays of dorsolumbar spine were noted.



3a. Guide tubes are inserted and screws are placed into the pedicles above and below the level to be fused



3b. Contoured rod is pushed through the skin and advanced through the heads of both pedicle screws.



3c. Intraoperative image of prebent rod with distraction and ligamentotaxis being done.

Fig 3: Important intraoperative steps

Pain was evaluated with the visual analogue scale (VAS). Clinical outcome was classified according to modified Macnab criteria⁴.

Table 1: Modified McNab criteria used to grade overall clinical outcome after spinal surgery

Grade	Definition
Excellent	Complete resolution of all symptoms and free of pain; no restriction of mobility; able to return to normal work and activities
Good	Marked reduction of pain with the patient generally satisfied, returning to work or usual daytime activities, and taking analgesics seldom or not at all
Fair	Some improved functional capacity; still handicapped and/or unemployed
Poor	Continued objective symptoms of root involvement; additional operative intervention needed at index level, irrespective of repeated operations or length of post-op FU
Worse	Clinical symptoms considered worse than before receiving procedure

Improvement in vertebral kyphosis (VK), vertebral height index (VHI: Ratio of height of the anterior side of vertebral body to that of adjacent vertebra) and canal area (CA) along with the fusion rates were assessed in follow-up CT scans performed immediately post-op and at 6 months and 12 months follow-up. Surgimap Spine™ medical imaging software was applied for the radiological evaluation.

RESULTS

Fourteen patients underwent percutaneous instrumentation for single level dorsolumbar spine fracture performed by two specialist spine surgeons at our centre. The operating time ranged from 65-195 minutes (mean 95.7 ± 34 minutes), however it is to be

mentioned that the procedure time drastically decreased in subsequent surgeries performed by surgeon. The procedure was converted to open in a 45 year female with osteoporosis in which screw pull-out was noted during ligamentotaxis and rod manipulation. In another patient the procedure was converted to open because of difficulty in rod positioning. The intraoperative blood loss ranged from 50 to 150 ml (mean 94 ± 16 ml).

Total of 60 screws were put in 12 cases (in whom complete procedure was successfully done percutaneously). Two screws breached the cortex of medial pedicle, thus the malposition rate was 3.3%. In one patient it was 6mm and in the other 3 mm making them Grade D and C respectively⁷. Both the patients were asymptomatic and we made no attempt to reposition the screws.

One patient had post-op wound infection managed by antibiotics. Post-operative hospital stay ranged from 1-15 days (mean 3.8 ± 2.3 days). There was no neurological deterioration in any of our patients in immediate post-op period.

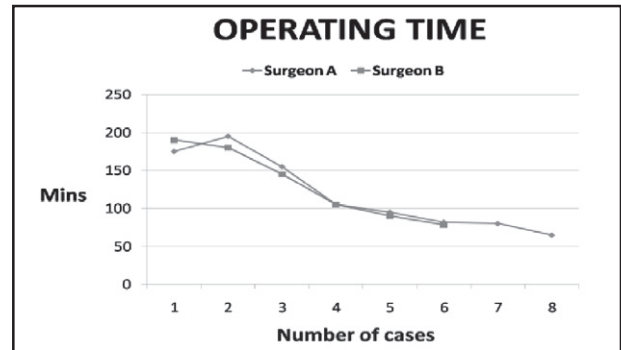
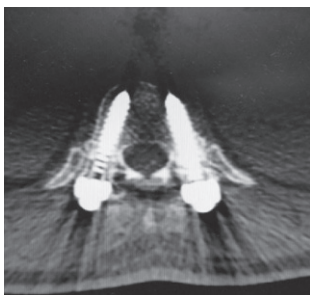
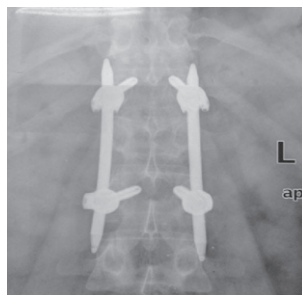

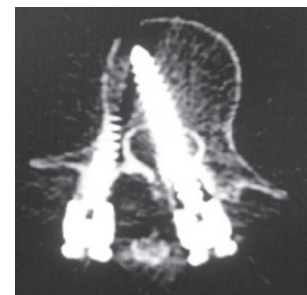
Fig 4: Operating time in individual case by each surgeon. Note the drastic decrease in operating time in subsequent surgeries.



5a. Post-op CT showing pedicle screws in-situ



5b. Post-op X-ray showing implant in position with gain in vertebral body height



5c. Grade D malpositioned screw in post-op CT scan: patient was asymptomatic

Preoperative pain was high in all patients, with the mean visual analogue scale value of 7.9/10 (range 6-10). It decreased to 2.2 at time of discharge (range 0-7) and to 0.7 at the last follow-up (range 0-2). The only patient with complete paraplegia, having D9 fracture was lost to follow-up.

There were improvements in the vertebral kyphosis, vertebral height index and canal area in immediate post-op CT scans which persisted on last follow-up (varying from 6 to 12 months).

Table 2: Mean vertebral kyphosis in degrees

Level	n	Pre-op	Post-op	At last follow-up
D 9	1	9	3	–
D 12	3	20.5	9.3	9.8
L 1	7	29.2	11.4	13.2
L 4	1	13	5	–

Table 3: Mean Vertebral Height Index (VHI)

Level	n	Pre-op	Post-op	At last follow-up
D 9	1	62	87	–
D 12	3	58	86	84
L 1	9	66	89	85
L 4	1	75	91	–

Table 4: Mean canal area in mm²

Level	n	Pre-op	Post-op	At last follow-up
D 9	1	168.20	181.73	–
D 12	3	182.34	211.33	207.51
L 1	7	177.42	207.94	205.30
L 4	1	189.3	204.22	–

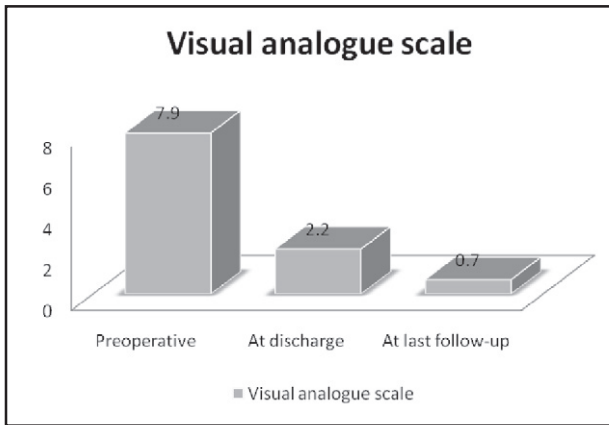
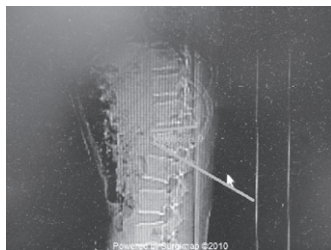
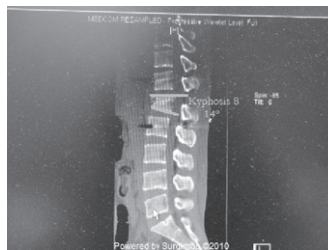
Fig 6: Mean visual analogue scale score of patients

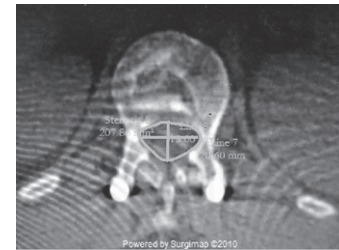
Clinical outcome as per the modified Macnab criteria was excellent in seven patients, good in four, fair in one and poor in one case.



7a. Pre-op kyphosis 36 degrees

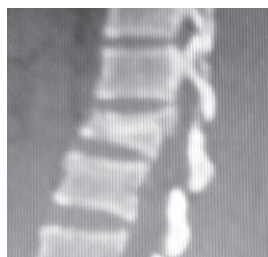

7b. Post-op kyphosis 14 degrees

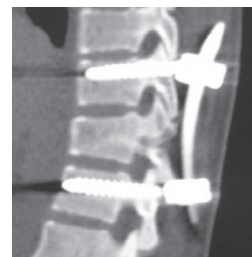

7c. Post-op canal area measurement

Fig 7 : Radiological evaluation of kyphosis correction and canal area by Surgimap Spine™ medical imaging software



8a. Pre-operative scan of 25 years old female with wedge compression fracture of L1 vertebra



8b. 12 months follow-up scan showing maintained kyphosis correction and body fusion

Fig 8: Preoperative and postoperative scans showing in gain vertebral height index (VHI) maintained at 1 year follow-up and fusion of body fracture.

DISCUSSION

Dorso-lumbar spine fractures with or without neurologic deficits are frequent. Management especially of the latter is not well codified. The chances of successful lumbar spinal fusion are increased significantly by the addition of a rigid fixation device. In a prospective randomized study of 124 patients undergoing lumbar or lumbosacral fusion, Zdeblick⁸ showed that rigid fixation in which instrumentation was used resulted in successful fusion in 95% of patients, compared with a rate of only 65% in patients without rigid fixation.

Surgery via the posterior approach with short term osteosynthesis has been superior for this type of fracture^{5,9}. By fusion, two or more vertebral segments are joined together, eliminating movement in the joints and thus reducing pain caused by movement and compression of the nerve roots. Combined approaches via both anterior and posterior stabilization have high risk with longer hospital stay and are not warranted¹⁰.

Conventional techniques of open lumbar pedicle screw fixation involve a single midline or bilateral paramedian incisions, extending above and below the instrumented levels allowing lateral retraction of the soft tissue to visualize the pedicle screw entry points at the intersection of the transverse process and facet complexes. The percutaneous technique eliminates the need of large incision as both the pedicle screws and contoured rods are placed by stab incision, with blunt splitting of paraspinous muscles leading to shorter duration of hospital stay and recovery. The need of blood transfusion is decreased and none of our patients required it.

Our incidence of pedicle breach of 3.3% confirmed on CT scan is comparable to study of Wiesner's¹² having 6.6%. Schwender et al¹³ described their technique of mini-PLIF. The mean blood loss of 140 ml and mean hospital stay of 1.9 days in their series is comparable to that of 94 ml and 3.8 days respectively in our study. The good to excellent clinical outcome in our study of 84.6% is similar to that of 89.4 % of Schwender¹³ and 91.1% of Foley⁴.

Experience and good fluoroscopic techniques are both extremely important to perform the procedure safely. Perfect lateral and AP images are needed to place screws safely. Spending extra time to eliminate obliquity on fluoroscopic images is justified¹⁴. The procedure time drastically decreased in subsequent surgeries (from about 195 minutes to 80 minutes), emphasizing the early

learning curve involved with the complex biomechanics/physics of instrumentation technique.

If there is concern over landmarks or possible screw breakout, the threshold for conversion to open procedure should be low. In such scenario the small paraspinous incisions should be closed and a midline exposure should be made¹⁴. In our series two patients required open conversion for reasons already described.

CONCLUSIONS

Percutaneous pedicle screw fixation technique is minimally invasive with potential benefits of less damage to muscle and skin, less blood loss, less post-operative pain, shorter hospital stay, quicker return to normal activities, easier rehabilitation and smaller scars. It is safe and efficacious in the setting of acute polytrauma with spinal fracture requiring ligamentotaxis. Complex biomechanics/physics of instrumentation, lack of adequate fusion and steep learning curve with increased radiation exposure limits its application in all cases.

REFERENCES

1. Gaines RW. The use of pedicle-screw internal fixation for the operative treatment of spinal disorders. *J Bone Joint Surg Am* 2000; 82-A:1458–76.
2. Yuan HA, Garfin SR, Dickman CA, et al. A historical cohort study of pedicle screw fixation in thoracic, lumbar, and sacral spine fusions. *Spine* 1994; 19 (Suppl 20):2279S–96S.
3. Magerl FP. Stabilization of the lower thoracic and lumbar spine with external skeletal fixation. *Clin Orthop Relat Res* 1984; 189:125–41.
4. Foley KT, Gupta SK. Percutaneous pedicle screw fixation of the lumbar spine: preliminary clinical results. *J Neurosurg* 2002; 97:7–12.
5. Vaccaro AR, Lehman RA Jr, Hurlbert RJ, et al. A new classification of thoracolumbar injuries: The importance of injury morphology, the integrity of posterior ligamentous complex, and neurologic status. *Spine* 2005; 30:2325–33.
6. American Spinal Injury Association. International standards for neurological classification of spinal cord injuries, revised 2000, 6th ed. American Spinal Injury Association, Chicago, IL, 2000.
7. Grützner PA, Beutler T, Wendl K, et al. Navigation an der Brust-und Lendenwirbelsäule mit dem 3D-Bildwandler. *Chirurg* 2004; 75:967–75.
8. Zdeblick TA. A prospective, randomized study of lumbar fusion. Preliminary results. *Spine* 1993; 18: 983–91.

9. Siebenga J, Leverink VJ, Segers MJ, et al. Treatment of traumatic thoraco-lumbar spine fractures: a multicenter prospective randomized study of operative versus nonsurgical treatment. *Spine* 2006; 31:2881-90.
10. Gelb D, Ludwig S, Karp JE, et al. Successful treatment of thoraco-lumbar fracture with short- segment pedicle instrumentation. *J Spinal Disord Tech* 2010; 23:293-301.
11. Knop C, Kranabetter T, Reinhold M, Blauth M. Combined postero-anterior stabilization of thoraco-lumbar injuries utilizing a vertebral body replacing implant. *Eur Spin J* 2009; 18:949-63.
12. Wiesner L, Kothe R, Schulitz KP, et al. Clinical evaluation and computerized tomography scan analysis of screw tracts after percutaneous insertion of pedicle screws in lumbar spine. *Spine* 2000; 25:615-21.
13. Schwender JD, Holly LT, Rouben DP, Foley KT. Minimally invasive transforaminal lumbar interbody fusion (TLIF); technical feasibility and initial results. *J Spinal Disord Tech* 2005; 18 (suppl):S1-6.
14. Fassett DR, Brodke DS. Percutaneous lumbar pedicle screws. In *Minimally invasive spine surgery*. Vaccaro AR, Bono CM (Eds). Informa healthcare, New York. 2007: pp 229-235.
15. Haid KW Jr, Subach BR, Rodts GE, Jr. Advances in spinal stabilization. *Prog Neurol Surg* 2003; 16:204-12.