

Risk factor prognosticating single centre outcome study of 75 cases of cervicodorsal fracture dislocations

Kanwaljeet Garg MBBS, Deepak Gupta M Ch, Noufal Basheer MBBS,
Ashok Kumar Mahapatra M Ch, G D Sathiyarathi M Ch, Deepak Aggarwal M Ch, Sumit Sinha M Ch
Department of Neurosurgery, Jai Prakash Narayan Trauma Center, AIIMS, New Delhi 110029

Abstract: Acute traumatic fracture-dislocations at the cervicothoracic junction are rare, accounting for 9% in cervical injuries. Presented herewith is a prospective cum retrospective study of 75 patients with C6 to D2 traumatic fracture dislocation operated over two year period at a level 1 apex trauma centre in India. Mean age at presentation of 38.5 years (range 6 -80 years). In 34% of patients injury resulted from high velocity trauma, whereas 66% suffered from low velocity trauma. Complete cord injury was seen in 53 patients (70.7%) while the rest 22 patients (29.3%) had incomplete cord injury. MRI signal change was noted in 67% cases. Mean pre operative Frankel score was 1.84 and mean post operative Frankel score was 2.07. Mean Sub-axial injury Classification score (Vackaro) was 6.22. Most of the patients (89%) were operated by anterior approach. About two thirds of all patients were ventilator dependent on prolonged follow up. There was improvement in motor function in post operative period in 10 % (n= 8) patients whereas 1 patient had deterioration. Mortality rate during hospital stay was 17 % (n=13). Low velocity trauma is the most common cause of cervicodorsal fracture with significant social impact as the young population is mostly involved and cervicodorsal injury resulted in significant deficits. Anterior surgical approach is safe and effective.

Keywords: cervicodorsal junction; instability; spine

INTRODUCTION

Cervicodorsal injuries are an important cause of traumatic paraparesis or paraplegia. As the young part of society is most commonly affected, it presents a significant economic burden to the family and society. Nichols et al¹ reported a 9% incidence of cervicothoracic injury, defined as fracture of the neural arch or vertebral body or true fracture-subluxation, in their cervical spine-injured population. Evans² in 1983 studied 14 cases identified from 587 cervical spinal cord injuries (SCIs) over a 26-year period, giving an incidence of 2.4% of cervical SCIs. The literature is sparse in relation to the detailed imaging findings of cervicothoracic junction injuries. The purpose of this study is to present a detailed analysis of clinical features and imaging findings of traumatic fracture dislocation in the region of the sixth cervical to the second thoracic vertebrae and to discuss treatment methods and outcomes in patients managed at an apex trauma centre.

MATERIALS

We performed a prospective cum retrospective review of traumatic spine injury patients managed at our centre,

Address for correspondence:

Dr Deepak Gupta

Department of Neurosurgery, Jai Prakash Narayan Trauma Center, AIIMS, New Delhi 110029

a level 1 apex trauma centre, over a two year period. Out of all cervical spine injuries, we identified seventy five cervicothoracic fracture-dislocations (fracture dislocation in the region of the sixth cervical to the second thoracic vertebrae). The notes and imaging findings were reviewed with particular attention to the age at presentation, gender, mode of injury, neurologic status at presentation, associated head injury, imaging features, treatment, and outcome. Neurologic status at presentation and final follow-up was assessed using the Frankel classification as follows –

- A. Absent motor and sensory function
- B. Sensation present, motor function absent
- C. Sensation present, motor function active but not useful (grade 2—3/5)
- D. Sensation present, motor function active and useful (grade 4/5)
- E. Normal motor and sensory function

Available imaging included radiographs, computed tomography (CT) studies, and magnetic resonance imaging (MRI) studies. All patients were operated and fixation with fusion was done. Post operatively patients underwent either X-ray or CT and were examined for construct placement, spinal canal decompression. Regular physiotherapy was done in all patients after the surgery. Analysis was done using SPSS 17 for windows.

RESULTS

Epidemiology: Our patients ranged from 6 yrs to 80 yrs (Mean ± SD 31.5± 12.15) with 88 % (n = 66) males and 12 % (n = 9) females. Most importantly majority (43%) of them belonged to age group of 20- 39 (Figure 1). 3 patients were less than 18 years of age. Most common mode of injury was fall from height (65 %). Road traffic accidents accounted for 34.7%, out of which almost all were due to either because of running over by the vehicle or due to high speed acceleration deceleration injury. One patient had fracture due to assault.

Clinical Profile: Majority of our patient (65%) belonged to Frankel grade A, i.e., complete motor and sensory loss below the injury. Only 20 % of the patients had some useful motor sensory function (Frankel D or E). Fifty five patients (73%) had bowel bladder involvement. Majority of the patients (96%) had some neurological deficit. Complete cord injury was seen in 53 patients (70.7%) while the rest 22 patients (29.3%) had incomplete cord injury. Mean Sub-axial injury Classification score (Vackaro)³ was 6.22. Eleven patients (14.3%) had associated head injury. Nineteen patients (25 %) had multiple level vertebral fractures.

Radiology: Most common vertebra involved was C 6, in 65 % of patients (Table 1). On MR imaging 33 patients (64%) showed cord signal changes with 18 (36%) showing normal cord.

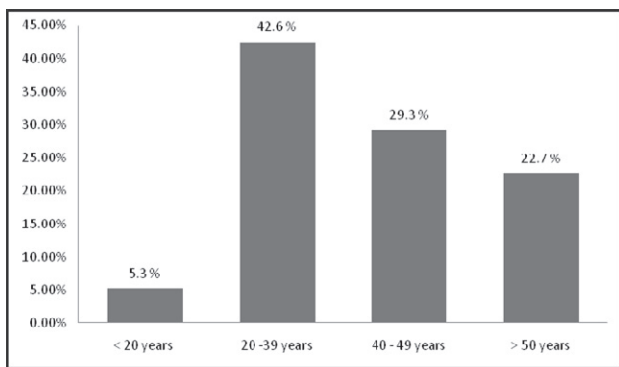


Fig 1: Age distribution of patients

Table 1 : Different vertebral level involvement

Vertebrae	Frequency	Percent of patients
C 6	49	65.3 %
C 6, 7	14	18.7 %
C 7	9	12 %
C 7, D1	3	4 %

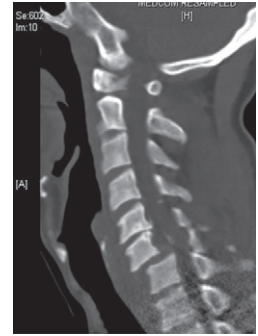


Fig 2a : NCCT C spine of a patient showing C6 C7 fracture dislocation

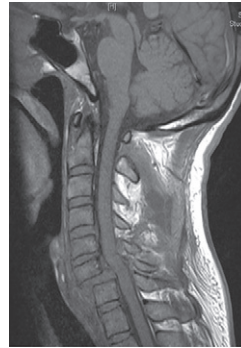

Fig 2b : MRI of the same patient

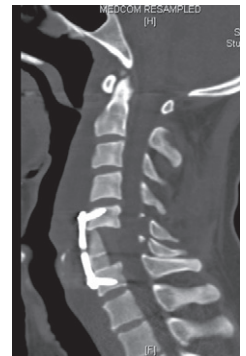

Fig 2 c : Postoperative NCCT C spine of the same patient

Surgical Management: Mean duration from injury to surgery was 11 ± 5.6 days. Majority of them (89.3%) were approached anteriorly. Four patients (5.3%) were operated through posterior approach. Combined anterior and posterior approach was used in 2 patients.

Post operative Complications: Most common complication was chest infection (30.67%). Seventeen patients developed septicaemia (Table 2). 16 % of patients developed bedsores. Thirteen patients (17.8%) died during their hospital stay.

Early Outcome: Immediate outcome was measured using Frankel grading on post operative day 7. There was deterioration in power in 1 patient after surgery. Overall 10 patients had improvement. But there was no statistical significance (p value 0.5) of the preoperative Frankel grade in predicting the improvement of the patient (Table 3). The surprising findings were 4 patients of Frankel grade A also showed improvement in their neurological status. Four out of 28 (14.3 %) patients

who were operated within 7 days of injury showed improvement compared to 3 out of 36 who were operated after 7 days of injury (Table 4). This figures show that early surgery is beneficial in neurological recovery of these patients. But the p value was not statistically significant (p = 0. 6). Our study also showed that there was no correlation of outcome with with the surgical approach (anterior or posterior), head injury or hypotension (Tables 5 & 6).

Final Outcome: Final outcome was measured at last follow up visit. Mean follow up was 13.1 ± 6 months (range - 4 to 23 months). Out of 75 patients 34 patients were available for follow up. Mortality was 33.3 % (n=25). Out of 34 available for follow up 14 patients (41.6%) showed some improvement. The only factor which was significant in deciding the outcome was pre operative Frankel score. None of the other factors such as age, time of surgery, pre operative hypotension, or associated head injury showed significant association with final outcome.

Table 2 : Incidence of complications

Complication	No of patients	Percentage of patients
Pneumonia	23	30.67 %
Septicemia	17	22.67 %
Renal failure	2	2.67 %
Bed sore	12	16 %

Table 3 : Correlation of pre operative Frankel score with improvement following surgery

Frenkel	Improvement Following surgery	No improvement	deterioration
A	4	45	0
B/C	3	7	1
D	1	11	0
E	0	3	0

Table 4 : Correlation with timing of surgery

Interval between trauma & surgery	< 7 days	7-30 days	> 30 days
Improvement	4 (14.3%)	3 (7.7%)	1 (14.3%)
No improvement	23	36	7
Deterioration	1	0	0

Table 5 : Correlation of improvement with approach of surgery

Surgical approach	n	Improve-ment	same	Deterio-ration	P value
Anterior	69	8	58	1	.5
Posterior	2	0	2	0	
Combined	4	0	4	0	

Table 6 : Other prognostic factors

	Improved	Same	P value
Age group			
< 20	0	5	.47
20-40	3	35	
> 40	5	26	
Head injury			
Yes	1	10	.8
No	7	56	
Mechanism of injury			
Fall from height	5	42	
RTA	3	23	
Assault	0	1	
Hypotension			
N = 15	3 (20%)	12(80%)	.4
MRI signal change			
Cord change	3	30	.3
No change	6	12	

DISCUSSION

Acute traumatic fracture – dislocation at the cervicothoracic junction is a rare event. Nichols et al¹ reported a 9% incidence of cervicothoracic injury, defined as fracture of the neural arch or vertebral body or true fracture–subluxation, in their cervical spine–injured population. Evans² in 1983 studied 14 cases identified from 587 cervical spinal cord injuries (SCIs) over a 26-year period, giving an incidence of 2.4% of cervical SCIs.

The cervicothoracic junction is a complex anatomical region^{4,5}. Injuries in this area are associated with serious clinical problems regarding anatomical diagnosis of the lesion, the choice of surgical treatment to perform, and the clinical outcome. Diagnosis is often difficult to make. Common reasons include poor visualization of the

cervicothoracic region on standard lateral cervical spine radiographs, particularly in the trauma scenario and in the muscular or obese patient. X-rays provide little help because the cervicothoracic junction is often difficult to see; therefore, CT scan or MRI imaging is needed. It is not always easy to diagnose spinal fractures. Diagnosis is even more difficult when the subjects are suffering from multiple trauma, are unconscious or sedated. CT scan with sagittal reconstruction is the essential radiological examination. Jelly et al⁷ reported results of a study of 73 intubated patients, victims of multiple trauma, who were given a systematic CT scan of the cervicothoracic junction. In this group, 20 spinal fractures were detected, including 12 fractures of the cervicothoracic junction (one C7 fracture of the transverse processes, 1 fracture of C7 pedicles, and 5 fractures of the posterior arch of the first and second ribs). In 7 of 12 cases, standard X-rays did not reveal these lesions. CT sections must investigate the cervical spine and upper thoracic section as far as T6. Further examination using MRI is necessary in some cases because MRI provides information on the state of the spinal cord and reveals discal lesions. A thoracic CT scan reveals pulmonary and vascular trunk lesions, which require emergency treatment, and defers spinal surgery.

A postoperative lateral standard X-ray examination provides insufficient information regarding the achieved correction obtained and the position of the implants in the cervicothoracic junction. We checked the reduction and spinal cord decompression using CT scans either one or a few days immediately after surgery. Our study, with a 33% death rate, confirmed the severe prognosis of this type of injury.

Neurologic sequelae following cervicothoracic junction injuries are common. This relates to the relatively small canal size of the upper thoracic spine,

although vascular insufficiency through the tenuous blood supply of the lower cervical cord makes it more prone to ischemic injury. The cervicothoracic junction can be potentially unstable following injury, and surgical outcome in those with complete cord injury, although not leading to neurologic recovery, often results in an improvement in the quality of life. It is for these reasons that surgical treatment of unstable cervical spine injuries is now generally accepted as the treatment of choice for the restoration of spinal stability. It is also our policy to offer open reduction and stabilization as the treatment of choice for fractures–dislocations. Even in the setting of complete cord injury, this may reduce the chances of posttraumatic syrinx formation.

CONCLUSION

Low velocity trauma is the most common cause of cervicodorsal fracture with significant social impact and cervicodorsal injury resulted in significant deficits. Anterior surgical approach is safe and effective.

REFERENCES

1. Nichols CG, Young DH, Schiller WR. Evaluation of cervicothoracic junction injury. *Ann Emerg Med* 1987; 16:640-2
2. Evans DK. Dislocations at the cervicothoracic junction. *J Bone Joint Surg Br* 1983; 65:124-7.
3. Alexander R Vaccaro, R John Hulbert, Alpesh A Patel, et al. The Subaxial Cervical Spine Injury Classification System. *Spine* 2007; 32:2365–74.
4. Vanden Hoek T, Propp D. Cervicothoracic junction injury. *Am J Emerg Med* 1990; 8:30-3.
5. Wang VY, Chou D. The cervicothoracic junction. *Neurosurg Clin N Am* 2007; 18:365-71. Review
6. Jelly LM, Evans DR, Easty MJ Coats TJ, Chan O. Radiography versus spiral CT in evaluation of cervicothoracic junction injuries in polytrauma patients who have undergone intubation. *Radiographics* 2000; 20:S 251-9.