

Traumatic spinal extradural hematoma following epidural anesthesia

P K Nayak M S, M Ch*, G Das M S**, L Parhi M D, D M***

A K Mahapatra M S, DNB, M Ch****

*Consultant Neurosurgeon, **Consultant Surgeon, ***Consultant Neurologist, Neelachal Hospital, Bhubaneswar.

****Prof of Neurosurgery and Director, Sanjay Gandhi postgraduate Institute, Lucknow.

Twenty-three years old female underwent Cesarean section under epidural anesthesia. She developed acute onset paraplegia following epidural anesthesia. On examination, power was grade 0/5, with sensory level at L1. The needle mark for epidural anesthesia was at L2/L3 level. Her coagulation profile was normal.

MRI of lumbo-sacral spine revealed, well-defined, oval tissue with heterogeneous signal intensity; of size 3.0/1.4/1.5 cu.cms, seen abutting the posterior aspect of thecal sac, with a cranio-caudal extension from L2 to L3. The lesion appears iso to hyper intense in T1W images and deeply hypo intense in T2W/TRIM images. The lesion was seen in sagittal and para sagittal location causing mass effect in the form of antero-lateral displacement of the thecal sac. (Fig: 1-2) Mild heterogeneous enhancement was noted in post Gadolinium scans. MR myelography revealed complete

signal loss at L2 to L3 levels. (Fig 3)

During surgery, with standard midline approach, L1 and L2 laminectomy was performed. The hematoma was defined in the extradural space, causing mass effect and displacing the spinal cord to the right (Fig 4). The hematoma was evacuated and hemostasis was achieved. Good pulsation of thecal sac was observed, at the end of surgery. Following surgery patient had a good neurological recovery.

Bleeding into the extradural space in the spine may cause extradural haematoma. Symptomatic spinal extradural hematoma (SEH) is rare¹. A description by Jackson, in 1869, is credited as the first official record of an SEH. Since that time, several hundred cases of SEH with various etiologies have been reported in the literature. Most are the result of trauma, anticoagulation therapy, vascular anomalies and blood dyscrasias or occur following spinal epidural procedures and rarely following spinal surgery^{2,3}. Simultaneous traumatic and hemorrhagic punctures may favour the development of

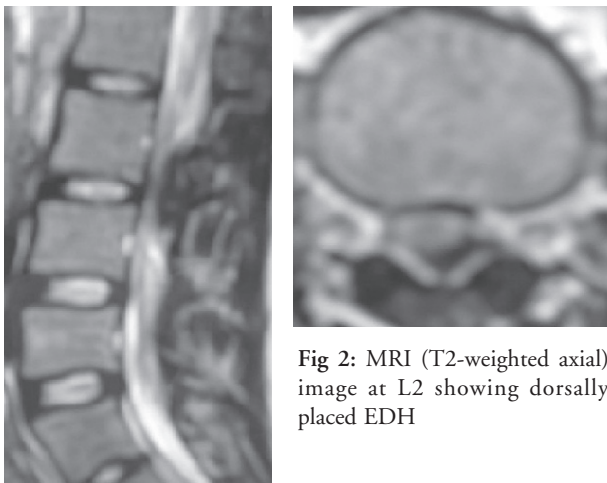


Fig 1: MRI (T2-weighted sagittal) image showing dorsally placed EDH

Fig 2: MRI (T2-weighted axial) image at L2 showing dorsally placed EDH

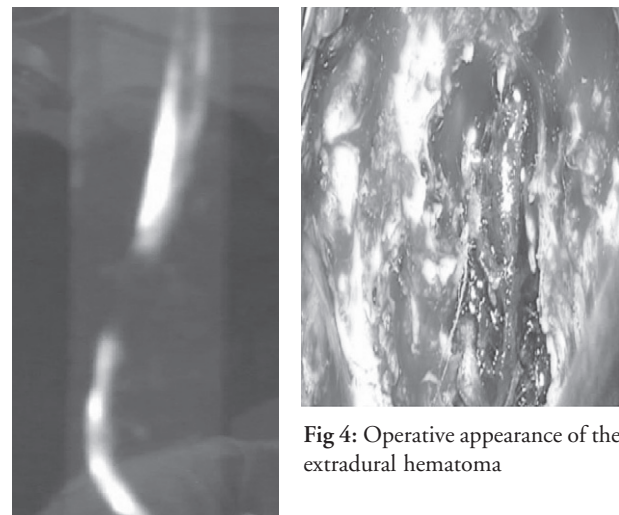


Fig 3: MR Myelogram showing spinal block

Fig 4: Operative appearance of the extradural hematoma

Address for correspondence:

Dr. P. K. Nayak

B-4, Gunjan Appt., Cuttack Road, Bhubaneswar - 751010

E-mail-drmichaelpn@rediffmail.com

a hematoma^{4,5}. Complications like SEH after spinal or epidural anesthesia is rare⁶. The incidence of extradural hematoma following epidural anesthesia is extremely difficult to determine. Estimated incidence varies from 1 per 10,000 to 1 per 100,000 following epidural anesthesia. The anatomy of the epidural space means that spinal extradural hematoma has a different profile from cranial extradural hematoma. In the spine, the epidural space contains loose fatty tissue, and the epidural venous plexus, a network of large, thin-walled veins, hence the hematoma is likely to be venous in origin. Anatomical abnormalities and coagulopathy makes these lesions more likely. Bleeding from Batson's plexus of veins is also postulated as a cause of SEH⁷. Tewari and Pandey had suggested that the rupture of valve less veins in the internal vertebral plexus, even by the slightest change of posture during sleep, turning or coughing, or due to Valsalva's maneuver, can cause epidural bleeding⁸.

SEH may cause pressure on the spinal cord or cauda equina, presenting as back pain, muscle weakness, or bladder and bowel dysfunction. Extradural hematoma complicating central blocks are rare but serious complications that can lead to permanent neurological deficits⁹. The diagnosis may be made on clinical appearance and time course of symptoms and mainly depends on magnetic resonance imaging¹⁰. Treatment is surgical decompression. SEH constitutes a rare complication of spinal anesthesia and need to be recognized in time, as its evacuation is associated with good prognosis.

REFERENCES

1. Boukobza M, Guichard JP, Boissonet M et al. Spinal epidural haematoma: report of 11 cases and review of the literature. *Neuroradiology* 1994; 36:456-9.
2. Jackson R. Case of spinal apoplexy. *Lancet* 1869; 2:5-6.
3. Tam NLK, Pac S C, Pretorius P M. Epidural haematoma after a combined spinal-epidural anaesthetic in a patient treated with clopidogrel and dalteparin. *Br J Anaesth* 2006; 96: 262-5.
4. Schmidt A, Nolte H. Subdural and epidural haematoma following epidural anesthesia. A literature review. *Anaesthetist* 1992; 41: 276-84.
5. Metzger G, Singbartl G. Spinal epidural hematoma following epidural anesthesia versus spontaneous spinal subdural hematoma. Two case reports. *Acta Anaesthesiol Scand* 1991; 35: 105-7.
6. Stroud C C, Markel D, Sidhu K. Complete paraplegia as a result of regional anesthesia. *J Arthroplasty* 2000; 15: 1064-7.
7. Groen RJ, Ponsen H. The spontaneous spinal epidural hematoma. A study of the etiology. *J Neurol Sci* 1990; 98:121-38.
8. Tewari MK, Pandey AK: Spontaneous spinal extradural haematoma. *Neurol India* 1999; 47:159.
9. Reina MA, Lopez A, Benito LJ, et al. Intracranial and spinal subdural hematoma: a rare complication of epidural and subarachnoid anesthesia. *Rev ESP Anesthesiol Reanim* 2004; 51: 28-39.
10. Kuker W, Thiex R, Friese S, et al. Spinal subdural and epidural haematomas: diagnostic and therapeutic aspects in acute and subacute cases. *Acta Neurochir* 2000; 142: 777-85.