

## Air in the transverse sinus

Harjinder S Bhatoe M Ch

Department of Neurosurgery, Command Hospital (SC) & Armed Forces Medical College,  
Pune 411040. Maharashtra

Post-traumatic pneumocephalus can be seen in the subdural, extradural, subarachnoid, intraventricular, intracerebral or intravascular locations. Air in the intravascular compartments is extremely rare, and only a few case reports on the subject are available<sup>1-5</sup>.

A 40-year-old female patient was admitted with history of having sustained closed head injury in a road-traffic accident. She had transient loss of consciousness followed by recovery. There was slight ear-bleed from the left side. Clinically, Glasgow Coma Score was 15/15, and there was no neurological deficit. CT brain showed fracture of the petrous temporal (Fig 1) and air within the left transverse sinus (Fig 2). She was managed conservatively, and was discharged 72 hours later, with no neurological deficit.

The mechanism of intravascular pneumocephalus is uncertain. It is likely that bony fracture overlies a sinus,

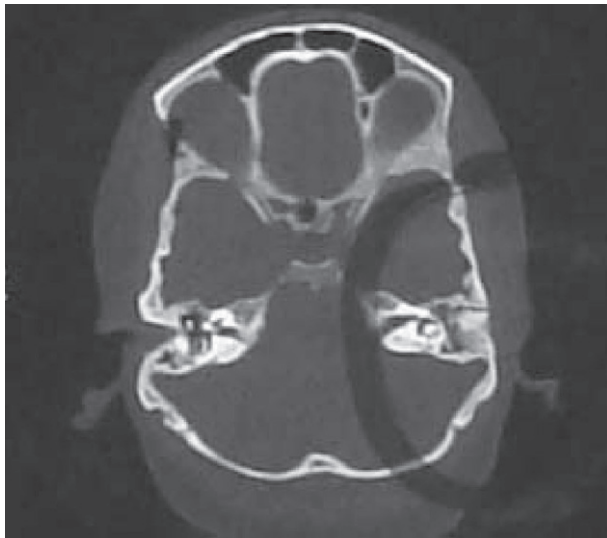


Fig 1: High resolution CT of skull base showing fracture through the left petrous

## Address for correspondence:

Col Harjinder S Bhatoe M Ch  
Professor & Head  
Department of Neurosurgery  
Command Hospital (SC) & AFMC  
Pune 411040. Maharashtra  
E-mail: hsbhatoe@gmail.com; harjinderbhatoe@yahoo.co.in

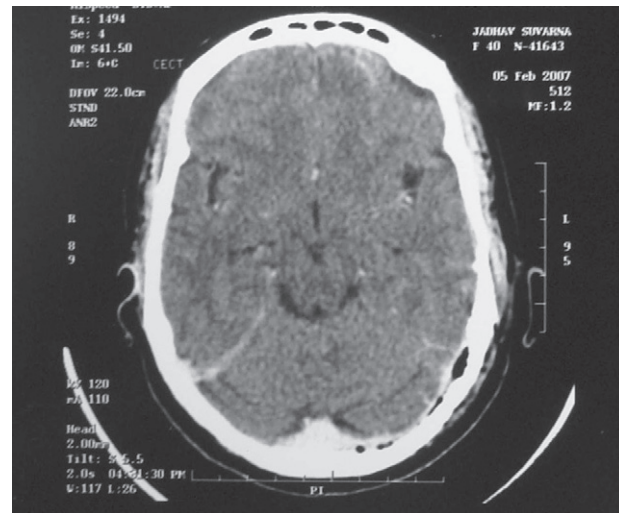


Fig 2: NCCT brain showing air within the left transverse sinus

which is also torn at the time of injury, and the negative intravascular pressure sucks in air at the time of injury or later with change in head position<sup>5</sup>. Air can also migrate from injury to a distant sinus<sup>5</sup>. Air may last few minutes, to two days after injury, and its CT demonstration depends upon the timing of the scan. The condition is self-limiting, with no untoward sequelae reported.

## REFERENCES

1. Haddad FS, Fahl M. Superior sagittal sinus following penetrating craniocerebral trauma. *Surg Neurol* 1986; 26: 599.
2. Crone KR, Lee KS, Moody DM, Kelly DL, Jr. Superior sagittal sinus air after penetrating craniocerebral trauma. *Surg Neurol* 1986;25:276-8.
3. Peled N, Blaser SI, Moore A, Harwood-Nash D. Computerized tomography appearance of accidental infusion of air into the venous sinus. *Pediatr Neurosurg* 1991;17:251-3.
4. Rao DG, Lyons PR. Post-traumatic venous sinus air embolism. *J Neurol Neurosurg Psychiatry* 1998;64:770.
5. Cihangiroglu M, Ozdemir Huseyin, Kalender Omar, Ozveren Faik, Kabaalioglu Adnan. Transverse sinus air after cranial trauma. *Eur J Radiol* 2003; 48:171-4