

## Coronal fracture -Anterior tear drop flexion injury cervical spine

SK Verma M Ch, MN Swamy M Ch

Department of Neurosurgery, Command Hospital (Central Command), Lucknow- 226002

### INTRODUCTION

An uncommon variant of cervical vertebral fracture which is indicative of the direction of vectors from flexion injury to the spine<sup>1</sup>. The uniqueness of this type of injury is that the middle column of spine remained intact, with disruption of both anterior & posterior column, along with compromise of stability.

### CASE REPORT

An 88-year-old male presented with history of fall from bed 12 days back resulting in acute flexion injury to the neck. The patient developed weakness of all 4 limbs, urinary retention along with pain cervical region following the injury. Clinically, he had spastic quadriplegia with power both upper limbs being 2/5 and lower limbs 1/5. Plantars were extensor.

Cervical spine radiograph showed hyperlordotic curve. MRI cervical spine showed evidence of cord contusion, canal compromise and fracture fifth cervical vertebral body. CT cervical spine showed of anterior tear-drop fracture of fifth cervical vertebral body.

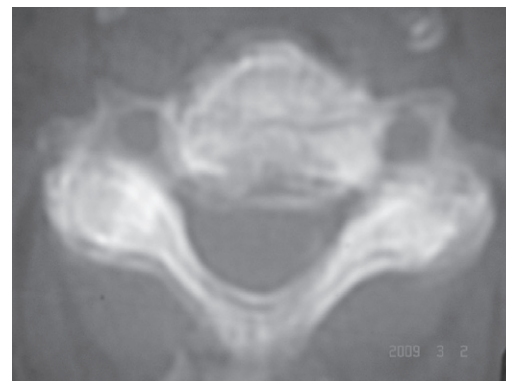
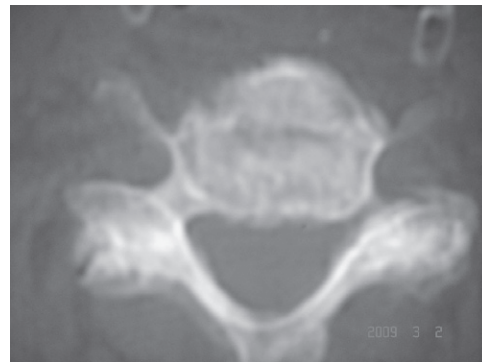
Patient underwent median corpectomy CV5, cage placement and CV4-6 plating. At the time of discharge after 9<sup>th</sup> post op day the patient was ambulant on wheel chair with persisting spastic quadriplegia with power in both upper limbs being 4/5, power both lower limbs 3/5. His grip had improved to nearly 30 % of normal.

### DISCUSSION

Schneider and Kahn<sup>2</sup> were the first to draw attention to the fracture of the anterior inferior corner of the vertebral body, and to assess the neurological implications of this lesion. They described the mechanism as one of acute flexion. Since then, a number of experimental studies have been performed; teardrop fractures have been found

in shallow-water diving accidents where the crown of the victim's head hits the bottom of the pool; tackling accidents of American football players, involving head-on axial impact, have been retrospectively analyzed from game films<sup>3</sup>. The evidence thus obtained indicates that the typical C-spine lesion is produced by axial compression that is suddenly exerted on a spine that is flexed to a greater or lesser extent. Schneider and Kahn did not mention the bony, vertebral body lesions shown by tomography and, later, by CT; equally, nothing was said about the damage to discs and ligaments that has been demonstrated by French authors<sup>4,5</sup>.

Teardrop lesions may comprise a number of features. In the vertebral body, a small triangular fragment is detached from the anteroinferior corner of the body; however, the fragment remains attached to the anterior

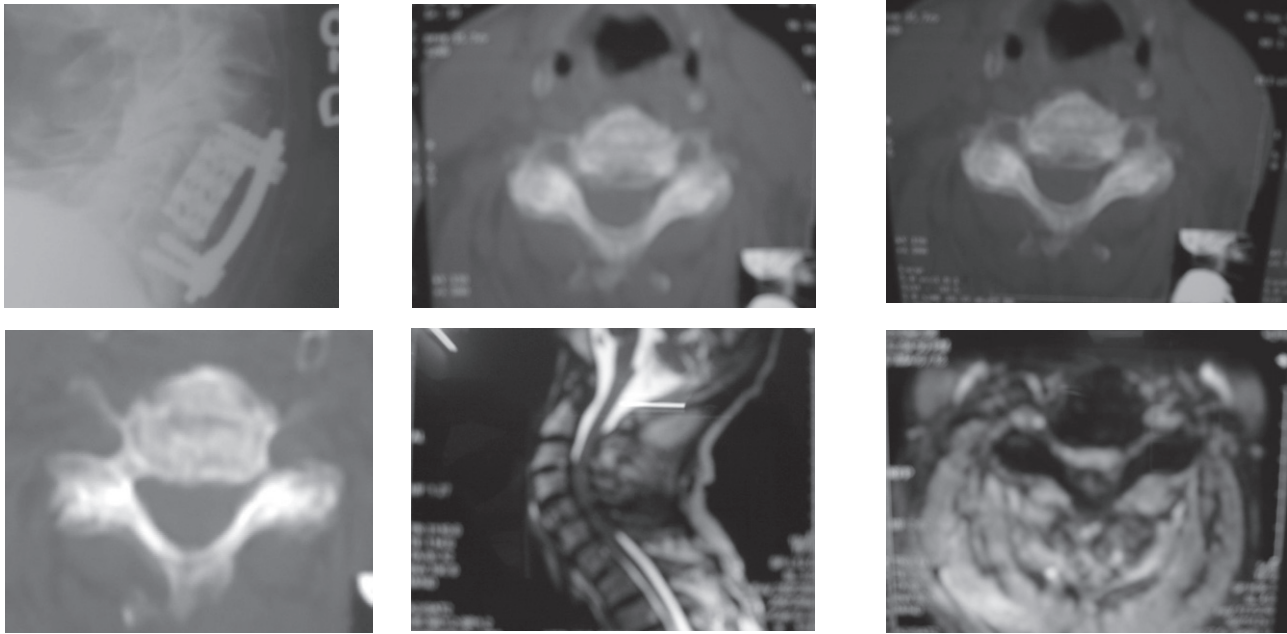


*Address for correspondence:*

Col MN Swamy

Senior Adviser Neurosurgery

Command Hospital (CC), Lucknow 226002 (UP)



corner of the subjacent disc. The fragment very rarely involved the full height of the anterior border of the vertebral body. The characteristic feature of the teardrop fracture is the detached bone fragment (regardless of size). A sagittal fracture line running through the vertebral body, as described by Fuentès<sup>6</sup>. This pattern has been seen more frequently since the advent of CT. In 1% of the cases, the suprajacent vertebra was also seen to have a sagittal fracture line. Its detection is of the utmost importance: If it is missed, anterior plating with only 1 midline screw would give poor stability, since (without the surgeon realizing it) the screw would be in the fracture line.

A lesion of the disc and of the PLL, which would be suggested by the lateral film, on which the posterior part of the vertebral body is seen to be displaced backwards.

Damage to the posterior ligamentous structures produces a number of patterns: Involvement of the facet joint capsules leads to the facets no longer being parallel; while damage to the supra/interspinous ligaments makes the spines gape. Instead of the ligamentous lesions, there may be a fracture of the neural arch (seen in 15% of the cases)

In conclusion, the analysis of the different lesions involved in teardrop injuries allows the injury to be classified as a "half-way" lesion, produced by compression associated with a greater or lesser degree of flexion. Where there is much flexion, discoligamentous injuries will predominate; where the compressive force exceeds that of flexion, the pattern will be mainly one of bony trauma. This dual nature of teardrop injuries accounts for the different opinions expressed in the literature as to the

stability of such lesions. Where there is discoligamentous disruption of the middle and posterior columns, as shown by retropulsion of the posterior wall, displacement of the facet joints, and interspinous gapping, the lesion should be considered to be unstable, and surgical treatment would be mandatory. This goes for the overwhelming majority of teardrop fractures, the most typical of which is undoubtedly that sustained when diving head first into shallow water. In that case, the fracture usually involves the C5 vertebra; & the neuro-logical status may be aggravated by the respiratory complications produced by near-drowning. On the other hand, some chiefly bony teardrop lesions, such as a sagittal fracture line running through the vertebral body, or a neural arch fracture, may be considered to be stable and should heal with properly conducted conservative treatment.

## REFERENCES

1. Bhatie HS. Coronal Fracture of Cervical Spine. *Ind J Neurotrauma* 2008;5:1:55.
2. Schneider RC, Kahn : The syndrome of acute central cervical spinal cord followed by chronic anterior cervical cord injury (or compression) syndrome. *J Bone Joint Surg* 1960; 42A : 253-60.
3. Torg JS, Pavlov H, O'Neill MJ, Nichols CE, Senett B : The axial load tear drop fracture. *Am J Sports Med* 1991; 19: 355-64.
4. Louis R: Traumatismes du rachis cervical I Entorses et hernies discales. *Press. Méd* 1979; 22: 1843-9.
5. Roy-Camille R et coll: Rachis cervical traumatique non neurologique. 1ères Journées de la Pitié, Masson Ed., 1979, Paris.
6. Fuentes JM, Bloncourt J, Vlahovitch B : La tear drop fracture. *Neurochirurgie* 1975; 29: 50-58.