

## Extravasation of contrast medium resembling hematoma following iatrogenic vascular trauma: Case report

Anita Jagetia M Ch, Sanjay Gupta M Ch, Pankaj Sarda MS, Daljit Singh M Ch, Sanjiv Sinha M Ch  
Department of Neurosurgery, G.B. Pant Hospital and associated Maulana Azad Medical College, New Delhi 110002

**Abstract:** The complication rate of cerebral angiography is 0.4 to 12.2% and stroke patients are at increased risk. Non-contrast CT head done for deterioration following angiographic procedures may show hyperdensity. This hyperdensity usually suggests the presence of a procedure induced hematoma. Rarely, it may be due to contrast extravasation. A high index of suspicion is needed in the latter group of patients to avoid unnecessary surgery. Two cases showing hyperdense lesions on non-contrast CT following iatrogenic vascular trauma during angiography and related procedures are presented with special emphasis on features which help to differentiate contrast extravasation from procedure induced hematoma.

### INTRODUCTION

A non-enhanced CT scan head performed following diagnostic or intervention angiography may show hyperdensity<sup>1,2</sup>. Hyperdensity on non-contrast CT image with some procedure related complication may be mistaken as hematoma. We are presenting two cases of hyperdense lesions mimicking hematoma on non-enhanced CT head following iatrogenic trauma to cerebral vessels during cerebral angiography and related procedures. All lesions giving impression of blood may not require surgery and surgery may be avoided in these cases.

### CASE 1

A fifty-year-old-hypertensive woman, with history of transient ischemic attack, presented with sudden onset weakness of left half of body with facial asymmetry of 15 days duration. Clinically, she had left hemiplegia with upper motor neuron type of left facial nerve palsy. Contrast CT of brain showed right hemispheric cerebral infarct. Doppler study of carotid vessels was suggestive of 90% block of bilateral carotid arteries (Fig- 1 a, b). Four-vessel cerebral angiography via femoral route showed a near 100% block of right internal carotid artery at its origin. However, following the initial injection into the common carotid artery, there was catheter induced trauma to the vessel wall which led to carotid artery dissection in the neck extending to supraclinoid segment

#### Address for correspondence:

Dr Anita Jagetia  
J-71, Vijaylakshmi Appts, I. P. Extension,  
Patparganj, New Delhi 110092  
Email ID: [anitajagetia@gmail.com](mailto:anitajagetia@gmail.com),  
Tel : 011-22725525

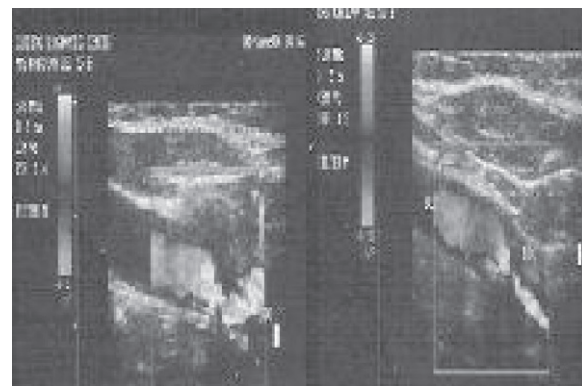


Fig 1 a,b: Doppler right (a) and left (b) suggestive of 90% block of bilateral internal carotid artery

of artery with extravasation of contrast medium in the right frontal region (Fig 1 c,d). Patient became drowsy following the procedure. A non-contrast CT head was done and it revealed right hemispheric infarct and hyperdense areas in right frontal, caudate nucleus, basal ganglia, tentorium mimicking acute hematoma with effacement of ipsilateral frontal horn (Fig 1 - e, f). Patient

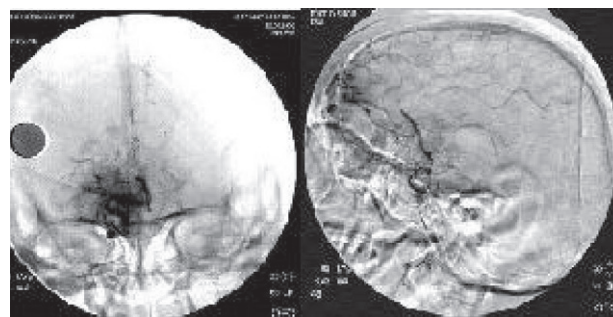


Fig 1 c,d: AP and lateral views of right carotid and cerebral angiography showing extravasation of contrast material in right frontal region.

was taken up for an emergency evacuation of hematoma. However, surgical exploration did not reveal a hematoma - brain was found to be soft and necrotic and was biopsied. Histopathology was suggestive of edematous gray, white matter and ischemic axons with no evidence of red blood cells (Fig 1g). Plain CT head, eight hours post-surgery showed persisting infarct and residual hyper-density (Fig 1-h, i). At discharge she was, obeying commands with persisting left hemiplegia.

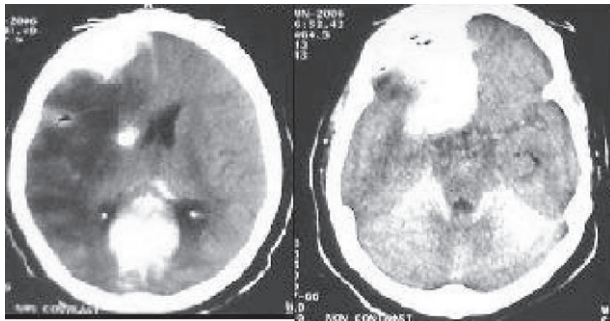


Fig 1 e,f: Non-contrast CT head showing hyper-density in right frontal, tentorial and interhemispheric region.

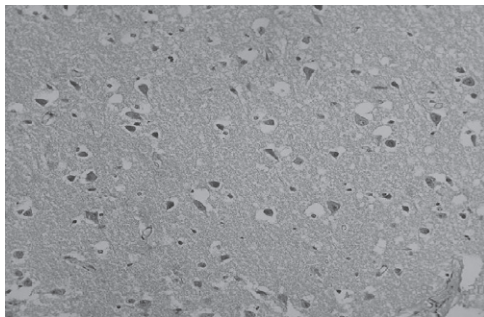


Fig 1 g: Histopathological image showing edematous gray, white matter.

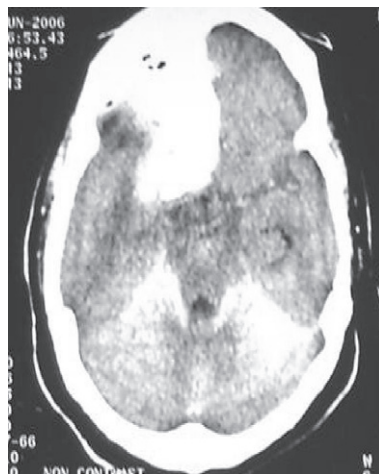

Fig 1 h,i: Post-operative non-contrast CT head done after 48 hours showing residual contrast material.

## CASE 2

Fifty-year-old-hypertensive woman presented with sudden onset severe headache four days before being seen at our institute. Clinical examination revealed GCS of 13/15 without any focal neurological deficit. Non-contrast CT head revealed blood in all the basal cisterns (Fig 2a) and cerebral angiography demonstrated basilar top aneurysm (Fig 2b). A repeat CT head done before coiling of aneurysm showed resolution of cisternal blood (Fig 2c). During intervention, there was re-bleed from the aneurysm and all vessels including vertebral artery went into severe vasospasm, therefore the procedure could not be completed. Patient showed clinical features of raised intracranial pressure. Plain CT head was repeated and it showed hyperdensity in all the basal cisterns and ventricles with ventricular dilatation (Fig - 2d). Hounsfield unit of the hyper-dense areas was 87 to 120 HU. A ventricular drain was inserted to

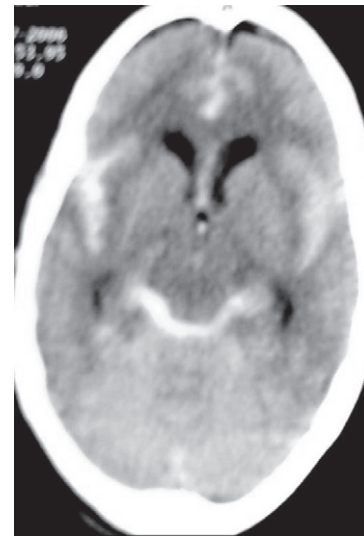


Fig 2a: Non-contrast CT head showing blood in all the basal cisterns

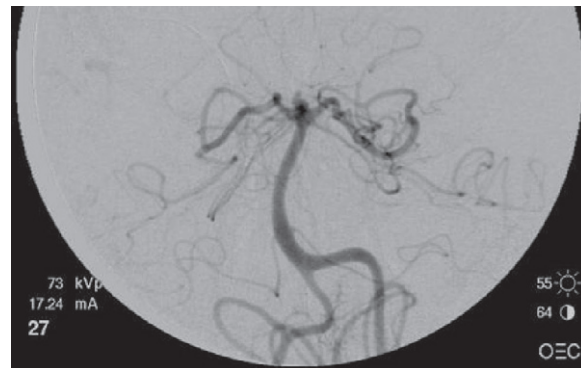

Fig 2 b: Right vertebral angiogram AP view showing basilar top aneurysm.

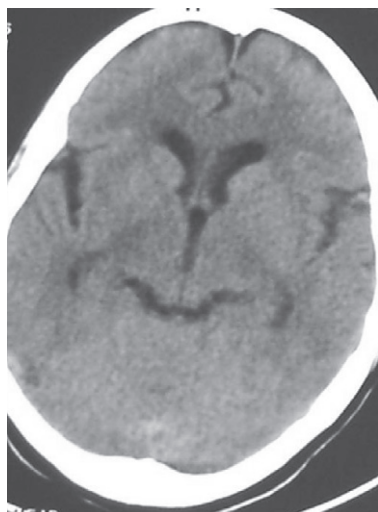


Fig 2c: Non-contrast CT head showing resolution of sub-arachnoid blood before subjecting patient for intervention.

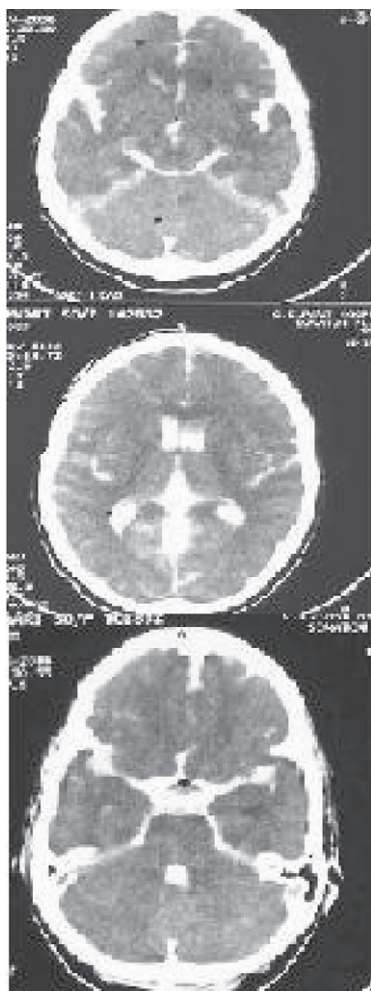


Fig 2d: Non-contrast CT head showing hyper-density in all the cisterns and ventricles.

manage the acute hydrocephalus - CSF was clear. This patient did not survive.

## DISCUSSION

Trauma caused to the vessels by catheter or guide wire leading to arterial dissections occurs in 0.1-0.6% of cases<sup>2</sup>. There are scanty of reports regarding dissection as a complication of the angiographic procedure. Olivercrona<sup>3</sup> reported this complication in 3 out of 3978 angiograms, Huckman et al<sup>4</sup> reported 2 out of 361, Vitek<sup>5</sup> reported 7 cases out of 2000 angiograms and Cloft et al<sup>6</sup> found 12 cases of internal carotid artery dissection out of 3112 angiograms. In case 1, catheter must have trapped into vessel wall close to the plaque and the pressure of the dye injection would have created a false lumen in completely blocked artery. The dissected vessel was carrying contrast manifested angiographically as contrast extravasation. Contrast material in CT head without measuring the HU unit of lesion may give the impression of hematoma as in the case 1. To rule out blood from contrast, there should be a high degree of suspicion. The HU of the lesion should be measured to differentiate blood from contrast material. The HU unit of contrast material is >90 contrary to acute blood which is 50-70 HU. Contrast would be denser than acute blood and would match with the density of bone.

In case 2, there was rupture of aneurysm during intervention and dye must have extravasated into ventricles and subarachnoid spaces, however there was no residual contrast on repeat CT within 24 hours. External ventricular catheter was placed considering the increased size of ventricle from previous scan. Yoon et al<sup>1</sup> defined contrast enhancement on non-contrast CT as hyperdensity which disappears within 24 hours without leaving a hematoma cavity or a mass effect, as compared to contrast extravasation which persists on 24 hour-follow-up scan. Leptomeningeal or thalamic CT contrast enhancement has been reported following stenting of the artery or thrombolytic therapy<sup>2,7</sup>. The proposed mechanism is injury to the blood brain barrier (BBB), which leads to gradual accumulation of contrast. In contrast enhancement only the blood barrier is disrupted, whereas in contrast extravasation both the BBB and the basal lamina of vessel get disrupted. Basal lamina is an anatomical barrier and BBB is a physiological barrier for any drug to enter into the brain<sup>8</sup>. According to Yoon's definition, case 2 should be considered as contrast enhancement as dye got resolved within 24 hours. There was clear angiographic evidence of re-bleed

of aneurysm with extravasation of dye from disrupted anatomical barrier too and perhaps the reason case 2 is also placed in the category of dye extravasation contrary to early resolution of contrast. In case 1 there was dissection of the vessel wall i.e. break down of anatomical and physiological barriers both.

### CONCLUSION

All hyperdense blood looking lesions on non-contrast CT head are not blood. There should be suspicious of contrast material in a patient subjected to angiography or related procedure in non-contrast CT and should be differentiated from blood, this may avoid unnecessary surgery and related morbidity.

### REFERENCES

1. Yoon W, Seo JJ, Kim JK, Cho KH, Park JG, Kang HK. Contrast enhancement and contrast extravasation on computed tomography after intra-arterial thrombolysis in patients with acute ischemic stroke. *Stroke* 2004; 35: 876-81.
2. Yoon W, Seo JJ, Kang HK. Bilateral paramedian thalamic contrast enhancement on CT after intra-arterial thrombolysis. *Korean J Radiol* 2005; 6: 41-3.
3. Olivercrona H. Complications of cerebral angiography. *Neuroradiology* 1977; 77: 175-81.
4. HuckmanMs, Shenk GI, Neems RL, Tinor T. Trans-femoral cerebral angiography versus direct percutaneous carotid and brachial arteriography: a comparison of complication rates. *Radiology* 1979; 132: 93-7.
5. Vitek JJ. Femoro-cerebral angiography: analysis of 2000 consecutive examinations, special emphasis on carotid catheterization in older patients. *Am J Roentgenol* 1973; 10: 1097-110.
6. Cloft HJ, Jensen ME, Kallmes, Dion JE. Arterial dissections complicating cerebral angiography and cerebrovascular intervention. *AJNR* 2000; 21: 541-5.
7. Wilkinson ID, Griffiths PD, Hoggard N, et al. Unilateral leptomeningeal enhancement after carotid stent insertion detected by magnetic resonance imaging. *Stroke* 2000; 31: 848-51.
8. GJ del Zoppo, R von Kummer, GF Hamann. Ischemic damage of brain microvessels: inherent risks for thrombolytic treatment in stroke. *J Neurol Neurosurg Psychiat* 1998; 65:1-9.