

Accidental human bite injury leading to compound depressed fracture of skull: Report of an unusual case.

Gurpreet Singh M S, BK Ojha M Ch, Anil Chandra M Ch,
Vashdev Chandwani M S, Nagesh Chandra M S

Department of Neurosurgery, King George's Medical University, Lucknow 226003 (UP)

Abstract: Human bites consist of a range of injuries. We present here a 6 year-old-child who suffered a compound depressed fracture of his skull from an accidentally impacted incisor of his father into his head.

INTRODUCTION

Human bites consist of a range of injuries. They can be either quite serious or relatively harmless. As human teeth are not particularly sharp, most human bites cause a bruise and only a shallow tear (laceration), if any. Exceptions are on fleshy appendages, such as the ears, nose, and penis, which may be severed. There have been unusual mechanisms reported of head injuries, some due to fan blade injuries, some due to fanblade¹, some due to stones flicked by tires of moving vehicles, etc. we encountered an unusual case of head injury that occurred as a result of accidental human bite injury and led to compound depressed fracture of skull. To the best of our knowledge human bite injury as a cause of depressed fracture skull has been reported only once².

CASE REPORT

A 6-year-old-male child presented to the trauma centre of King George's Medical University with history of accidental injury to his head while he was riding on the tank of a motorcycle with his father. After sudden stopping of the motorcycle the father's jaw thrust into the child's head. In the process the father lost his central and lateral incisors of the upper jaw bilaterally. The child had no history of loss of consciousness, vomiting or seizure. Clinically, the child was found to have a 2cm X 3cm contused lacerated wound over the right frontal bone with a piece of bone protruding out like an iceberg. Plain CT scan of head revealed a depressed fracture of the right frontal bone with no obvious underlying intraparenchymal injury (Figs 1 and 2).

Address for Correspondence:

Dr. Gurpreet Singh
Senior Resident Year III, Department of Neurosurgery
King Georges Medical University, Lucknow 226003 India
Phone: 91-9336829735.

The child was subjected to surgery to elevate the depressed segment, debridement and for dural repair. After the wound was opened the protruding bone was found to be an intact adult central incisor, which was later confirmed to be of the child's father, comparing it with the staining of the remaining teeth. Debridement craniectomy and primary dural repair was achieved. The child had an uneventful postoperative course and was discharged asymptomatic on the seventh postoperative day.

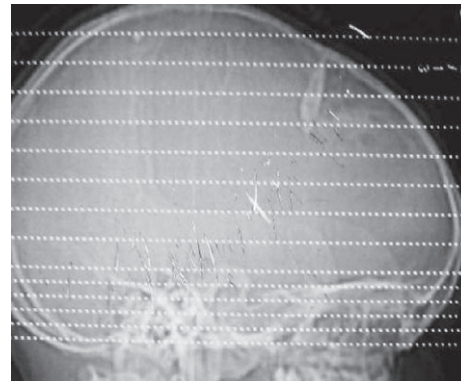


Fig 1: Scout film of CT head showing the impacted incisor.

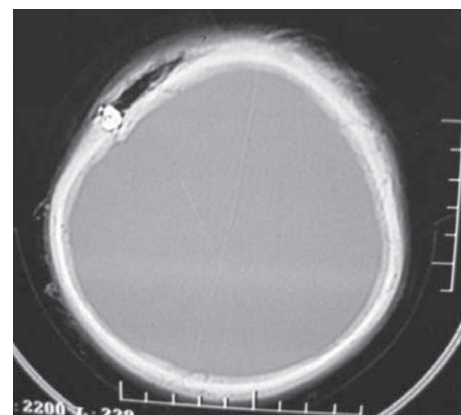

Fig 2: Bone window of CT head showing the depressed bone segment.

DISCUSSION

Human bites consist of a range of injuries. They include intentionally inflicted bites but also any injury caused by coming in contact with the teeth. Intentional bite injury happens during fights and seemingly intentional bites may occur among very young children and among people who are mentally handicapped. Accidental bites mostly occur due to closed fist injuries when someone punches another person in the mouth or, occasionally, accidentally strikes another in the mouth during sports or horseplay. These bites can cause damaging hand injuries and can be very serious if not properly cared for. Accidental bites to head or other body part occur when clashing with

someone else's tooth. These can be minor or, in the case of a head wound in young children, very serious. Possibility of contamination by oropharyngeal flora necessitates prompt and meticulous treatment in such cases.

REFERENCE

1. Singh Gurpreet, Kaif Mohammad, Husain Mazhar, Ojha B.K., Chandra Anil: Winnowing fan blade head injury: case report. *Ind J Neurotrauma* 2008; 5: 49-50.
2. Singh Deepak Kumar, Gupta Vishnu, Chopra Sanjeev, Gupta Pankaj, Bagaria H. Teeth in the brain. An unusual presentation of penetrating head injury. *Ind J Neurotrauma* 2008; 5:117-8.