

Bilateral pupil-sparing oculomotor nerve paralysis with multiple cranial nerve palsies and hormonal imbalance following head trauma. Report of a rare case with clinicopathologic correlation

Vineet Saggar M Ch, RS Mittal M Ch

Department Neurosurgery, S.M.S Medical College, Jaipur (Rajasthan)

Abstract : Isolated third nerve palsy alone or in combination with other cranial nerve palsies is a known phenomenon following moderate to severe closed head injuries. Isolated or combined third nerve palsy is almost always associated with pupillary involvement. A twenty-five-year-old male was admitted following head trauma at a private hospital where he remained unconscious for few hours. On recovery, he had bilateral ptosis with third nerve paralysis, bilateral sixth nerve paralysis, infranuclear facial palsy on left side and sensory impairment over right side of face. Initial CT head showed pneumocephalus in basal cisterns. MRI brain showed fluid in pituitary fossa and sphenoid sinus with contusion of optic chiasma. Hormonal profile revealed decreased T3, T4 and TSH levels and gonadotropin levels. We suggest spiral CT and MRI along with hormonal assessment of all the cases for accurate assessment of bony and neurological involvement in patients of head trauma with multiple cranial nerve palsies and injury in the region of sphenoid sinus.

Keywords: cranial nerves, head trauma, oculomotor nerve palsy.

INTRODUCTION

Isolated third nerve or in combination with other cranial nerve palsies following head trauma is not rare. It is usually associated with severe head trauma resulting in skull base fractures^{1,2,3}. These fractures are often under diagnosed because they are generally of no immediate consequences to the management of acute head injury patients. Though signs like raccoon eyes, Battle sign may point towards sites of probable fractures but fractures of clival region are generally missed because of lack of sign and symptoms. Clival fracture is suggested by multiple cranial nerve palsies, and an association is found with basilar artery injury and bilateral inter nuclear ophthalmoplegia^{4,5,6}. We report a rare case of bilateral complete external ophthalmoplegia and multiple cranial nerve palsies with endocrinal abnormalities following head trauma in the absence of fractures in clival region.

Address for correspondence:

Dr Vineet Saggar
Room No. 208, R.D. Hostel,
S.M.S Medical College, Jaipur (Rajasthan)
E-mail: memymyselfus@yahoo.co.in.
Tel no.0091-9828915338,0091-9982689164
E-mail: dr_mittal@hotmail.com .
Tel.No. 0091-1412566484. Fax:+91-141-2571317

CASE REPORT

A 25-year-old-young male presented in our department with history of head injury sustained in a road traffic accident. He was initially admitted to a private hospital in a state of altered sensorium. He had CSF otorrhea from the left side. When he regained consciousness he had bilateral third and sixth nerve paralysis for which he was referred to our institution. A thorough clinical examination revealed that vision in both the eyes 6/6, bilateral pupil-sparing third and sixth nerve paralysis, sensory involvement of fifth nerve on right side and lower motor neuron type of facial weakness on the left side. Rest of the cranial nerves were normal. CT scans revealed pneumocephalus with air in basal cisterns and intraventricular system, and air-fluid level in sphenoid sinus and left maxillary sinus. Bony window revealed fracture of body of sphenoid bone and fracture of maxilla on left side. There was no injury to the clivus. MRI brain revealed contusion in optic chiasma on left side with fluid in pituitary fossa as well blood in sphenoid sinuses and left maxillary sinus. Perimetry for visual fields revealed incongruent bitemporal hemianopia. Serum endocrine profile revealed decreased T3, T4 and TSH values and gonadotropin levels. He was kept on conservative treatment and his ptosis improved on right side. He was discharged on hormonal replacement and was advised regular follow-up.

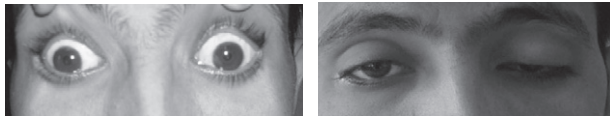

Fig 1: Normal pupillary size. Fig 2: Bilateral ptosis Rt.>Lt.

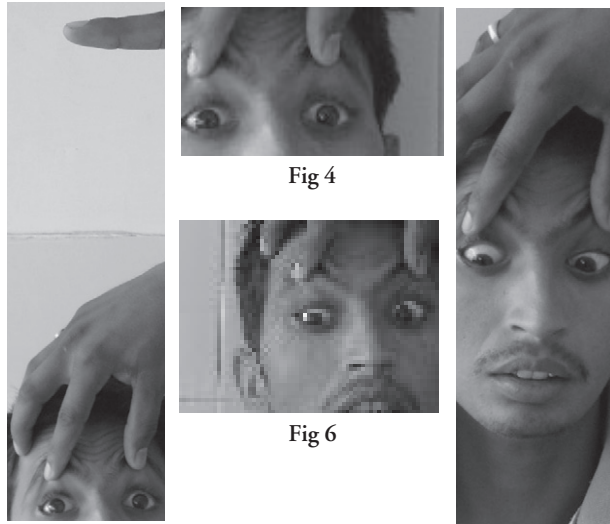


Fig 3-6 : Lack of eyeball movements in all directions except downwards (Fig.5)

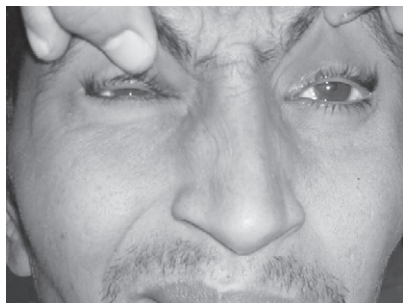

Fig 7: Facial palsy left side.

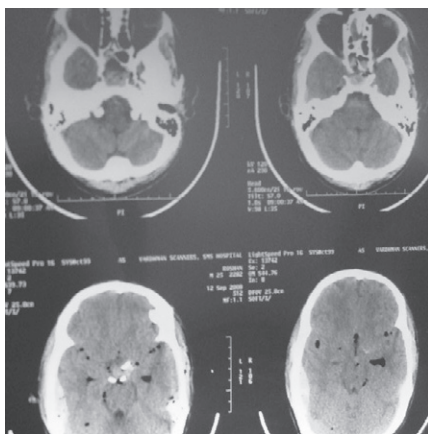


Fig 8: Showing air in basal cisterns and fluid in sphenoid sinus.

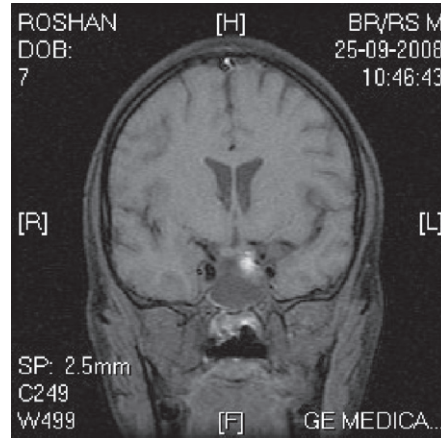


Fig 9: Showing fluid in sphenoid sinus and contusion in optic chiasma.

DISCUSSION

Third nerve is damaged generally in fatal high speed closed head injuries^{7,8}. Oculomotor nerve palsy following closed head trauma may be caused by direct injury of the nerve or by indirect compression of the nerve by an expanding supratentorial hematoma. Direct traumatic oculomotor nerve palsy is uncommon and is usually associated with subarachnoid hemorrhage, skull fractures, aneurysms, carotid-cavernous fistula or midbrain lesions⁸. Brain computerized tomography (CT) is recommended in acutely traumatized patients with the third nerve palsy to rapidly evaluate blood, bone, and supratentorial structures. Cerebral angiography is indicated when a vascular anomaly is the possible etiology. A complete imaging investigation for traumatic oculomotor nerve palsy should include brain magnetic resonance imaging (MRI), because CT may fail to detect midbrain damage and oculomotor nerve root avulsion⁶. Mechanisms of third nerve damage include midbrain contusions, avulsion from mesencephalon, primary contusion necrosis, intra or perineural haemorrhage in sub arachanoid space⁷. It may be associated with damage to visual pathways. Its association with frequently noted palsies of ipsilateral trochlear, trigeminal (sensory) and abducens nerves and anterior visual pathways suggests that damage occurs in anterior end of middle cranial fosse in relation to body and wings of sphenoid bones^{8,9}. The decelerating force is transmitted to this region by frontal and maxillary bones which take the initial impact and are frequently fractured⁸ as was probably the cause in our case since patient had fracture of maxilla on left side with fracture of body sphenoid bone though it could not explain pupillary sparing. Optic nerves lie

immediately above and medial and is vulnerable to trauma in optic canal where it is tethered to bone but in our case chiasma was damaged probably by hemorrhage into its nerve sheath as branches of anterior cerebral artery and anterior communicating artery supplying it get sheared by inertia of cerebral hemispheres moving forward at the time of impact^{8,9}. Similarly hormonal imbalance can also be explained on the basis of direct trauma to pituitary or vascular insult to either pituitary or hypothalamic region. Facial nerve in our case was probably damaged in facial canal as patient had left sided otorrhoea. Prognosis of third nerve palsy isolated or combined remains poor and is complicated by aberrant regeneration syndromes¹⁰⁻¹².

CONCLUSIONS

Third nerve palsy isolated or in combination generally occurs with pupillary involvement though there have been isolated reports of unilateral third nerve palsy with pupillary sparing. Bilateral pupil-sparing third nerve palsy has not been reported earlier. The mechanism of such an injury is poorly understood and may be because of hemorrhage into substance of nerves there by sparing peripherally located pupillary nerve fibres. Since third nerve may be damaged any where from midbrain to orbit we recommend thorough investigation of such patients using spiral CT, MRI and hormonal profile if required to assess extent of damage in such patients.

REFERENCES

1. Chen CC, Pai YM, Wang RF, Wang TL, Chong CF. Isolated oculomotor nerve palsy from minor head trauma. *Br J Sports Med* 2005;39:e34.
2. Solomons DJ, Solomon JC, de Villiers D. Direct traumatic third nerve palsy. *S Afr Med J* 1980;58:109-11.
3. Huges B. Indirect trauma of optic nerves and chiasma. *Johns Hopkins Med J* 1962; 111: 98-126.
4. Antony DC, Atwater SK, Rozear MP, Burger PC. Occlusion of basilar artery within a fracture of clivus. *J Neurosurg* 1987;66: 929-31.
5. Arivazhagan A, Garg N, Indira Devi B, Rose Dawn B, Pandey P. Complete ophthalmoplegia associated with clival fracture following trauma; case report and clinico-anatomical correlation. *Ind J Neurotrauma* 2007;4: 449-52.
6. Sharma BS, Mahajan RK, Bhatia S, Khosla VK. Collet-Sicard syndrome after closed head injury. *Clin Neurol Neurosurg* 1994;96:197-8.
7. Heinz J. Cranial nerve avulsion and other neural injuries in road accidents. *Med J Aust* 1969;56: 1246-51.
8. Elston JS. Traumatic third nerve palsy. *Br J Ophthalmol* 1984;68:538-43.
9. Walsh FB. Pathological-clinical correlations. 1. Indirect trauma to optic nerves and chiasma. *Invest Ophthalmol Visual Sci* 1966;4:433-9.
10. Stanworth A. Defects of oculomotor movement and fusion after head injury. *Br J Ophthalmol* 1974; 58: 266-271.
11. Kerns John, Smith DR, Jaannota FS. Oculomotor nerve regeneration after aneurysm surgery. *Am J Ophthalmol* 1980;98: 225-33.
12. Lepore FE, Glaser JS. Misdirection revisited: a critical appraisal of acquired oculomotor synkinesis. *Arch Ophthalmol* 1980; 98: 2206-9.