

Multiple traumatic extra dural haematoma

SM Noman Khaled Chowdhury M S, MF Elahy M S, E Mahmood Ph D, SS Hossain FCPS

Department of Neurosurgery, Dhaka Medical College Hospital, Dhaka, Bangladesh.

Abstract: Multiple extradural hematoma following head injury is a rare occurrence and carries a poor prognosis. We report one such case, who had a good outcome following timely evacuation of the hematomas.

Keywords: extradural hematoma, head injury

INTRODUCTION

Traumatic extradural haematoma (EDH) is a well recognized surgical complication of head trauma. The incidence of EDH among traumatic brain injury (TBI) patients has been reported to be in the range of 2.7 to 4%¹. Among patients in coma, up to 9% harbored an EDH requiring craniotomy. EDH is rare in extremes of ages^{1,2} and carries a mortality rate of 5-15%³. In surgical series, EDH are more frequently located in the temporoparietal and temporal regions as compared with other locations^{1,2,4}. The natural history of EDH is known to be varied, probably reflecting different origins. Some are arterial, massive life-threatening, and require emergency evacuation. At the other end of the spectrum are small, slow bleeds which are venous or bony in origin⁵. EDH also varies in their clinical presentation. They may be initially asymptomatic and remain so, or when they enlarge they can produce progressive symptoms, even after many days. They may be symptomatic but well tolerated, with subsequent resolution of symptoms as the clot reabsorbs. Radiologically significant EDH is usually treated by urgent craniotomy and evacuation of the epidural blood clot^{5,6}. EDH has been recognized for more than 120 years^{3,7}. Many authors have produced voluminous amount of literature on this subject. But simultaneous presence of triple EDH is extremely rare. We report one such a case

CASE REPORT

A 30-year-old male was referred to Neurosurgery department of Dhaka Medical College Hospital with

Address for correspondence:

Dr Chowdhury Noman Khaled S M, MS.,
Assistant Professor, Department of Neurosurgery,
Dhaka Medical College Hospital, Dhaka, Bangladesh.
Phone +8801819019415, E-mail- nomankhaled@yahoo.com

history of headache and drowsiness following road traffic accident. Patient was free from neurological deficit. CT showed presence of acute extradural haematoma in three separate locations: right frontal, right parietal and left parietal region (Fig 1). Urgent craniotomy under general anesthesia was done for prompt evacuation of haematomas. Postoperative recovery of the patient was uneventful.

DISCUSSION

Extradural hematoma usually occurs unilaterally. They rarely show bilateral localization and consist of 2–10% of all acute epidural hematoma in adults and in the pediatric age group, it is exceedingly rare⁸. Its presence at more than two sites is extremely rare. To the best of our knowledge, there is no report in the literature regarding simultaneous occurrence of triple EDH. It has suggested that a lateral force strips the dura at the site of impact by the inward and outward bending of the skull. While on the opposite side as described by Bell⁵ dural stripping occurs due to motion of the skull, aggravated further by negative intracranial pressure found at the antipode of the compression force of the skull⁹ this present case has several unique features. EDHs occurred

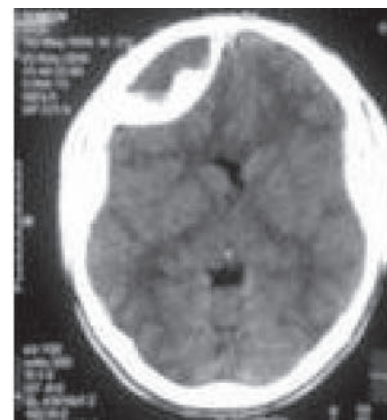


Fig 1: CT showing multiple bilateral epidural hematomas

in multiple sites simultaneously. Patient did not lose consciousness. Source of bleeding could not be delineated. Similarly Dharker et al could not demonstrate active arterial bleeding in their series of bilateral EDH^{9,10}. But in the literature the origin of hemorrhage in bilateral epidural hematoma is thought to be generally venous, as reported by Frank¹¹. High mortality rates (42–100%) have been reported in old series on bilateral epidural hematoma^{8,11}. This rate was 20% in Dharker's series¹⁰ and 15.7% in Görgülü et al's series⁸. EDH is a well recognized and most rewarding neurosurgical emergency^{2,3}. Accordingly, early detection of the lesion is critical. Neuroimaging can reveal not only the location and size of a clot but also identification of additional features that effect the outcome such as midline shift, traumatic subarachnoid hemorrhage, obliteration of the basal cisterns, thickness of blood clot and haematoma volume, cerebral contusion and fracture of skull bone³. This case report stresses all of these and urges intensive monitoring and prompt judicial management of neurotrauma patients.

REFERENCES

1. Bullock MR, Chesnut R, Ghajar J, et al. Surgical Management of acute epidural hematomas. *Neurosurgery* 2006; 58(Supplement): 52-7.
2. Chowdhury Noman Khaled SM, Raihan MZ, Chowdhury FH, Ashadullah ATM, Sarkar MH, Hossain SS. Surgical management of traumatic extradural hematoma: Experiences with 610 patients and prospective analysis. *Ind J Neurotrauma* 2008; 5: 75-9.
3. Jamjoom A. The influence of concomitant intradural pathology on the presentation and outcome of patients with acute traumatic extradural haematoma. *Acta Neurochir (Wien)* 1992;115: 86-9.
4. Bricolo AB, Pasut LM. Extradural hematoma: Toward zero mortality. A prospective study. *Neurosurgery* 1984; 14:8-12.
5. Howard H Kaufman, Joyce Herschberger, Thomaskopitnik, T, Phillip Mcallister, Jeffrey Hoggs, Tim Conner. Chronic extradural haematomas: indications for surgery. *Br J Neurosurg* 1992; 6: 359-64.
6. Knuckey NW, Gelbard S, Epstein MH. The management of "asymptomatic" epidural hematomas. A prospective study. *J Neurosurg* 1989; 70: 392-6.
7. Hutchinson J. Effusion of blood between bone and dura mater. *Lond Hosp Rep* 1867; 4: 51.
8. Görgülü A, Çobanoğlu S, Armagyan S, Karabagly H, Tevrüz M. Bilateral epidural hematoma. *Neurosurg Rev* 2000; 23:30–33.
9. Dwarakanath S M, Gopal S, Satish R, Venkataramana NK. Delayed sequential multiple extradural hematomas – Case Report and Review of Literature. *Ind J Neurotrauma* 2006; 3: 55-7.
10. Dharker SR, Bhargava N. Bilateral epidural hematoma. *Acta Neurochir(Wien)* 1991; 110: 29-31.
11. Frank E, Berger TS, Tew JM Jr. Bilateral epidural hematomas. *Surg Neurol* 1982; 17:218–22.