

Unilateral occipital condylar fracture presenting as neck pain and restriction of neck movements- Report of a case and review of literature

Manoj K Tewari M Ch*, K L Ratnam MD, Vinod K Shiv MD (Radiodiagnosis)
Departments of Neurosurgery* and Radiodiagnosis
Sohar Hospital, Sultanate of Oman

Abstract: Occipital condylar fractures (OCFs) once rare injuries are not so at present. A young male, victim of motor vehicle accident, presented with severe high cervical pain and restriction of neck movements without any focal neurological deficit, with normal cervical spine x-rays and computerized tomography (CT) scans brain. CT scan and magnetic resonance (MR) imaging of the craniovertebral junction (CVJ) area revealed a retro-pulsed segment in the cervical spinal canal with no cord compression or ligament injury. Patient improved with immobilization of neck. Patients with severe high cervical pain and restricted head movements OCF should be suspected and patient should be evaluated further. Majority of stable OCF improve with immobilization only.

Keywords: craniovertebral junction, lower cranial nerve deficit, motor vehicle accident, occipital condylar fractures

INTRODUCTION

Occipital condylar fractures (OCFs) were rare till CT scan came into existence because of the diagnostic difficulties. Only 215 cases have been reported since the first report in 1817[99 reports between 1817 and 1997 {38 postmortem and 61 in survivors} and 116 cases afterwards¹. Still about 1.7% cases may be missed by CT scan and may need MRI^{2,3}. In the present communication diagnosis and management of unilateral OCF presenting with severe high cervical pain is reported and relevant literature reviewed.

CASE REPORT

A 27 years old male presented with severe neck pain and restriction of neck and head movements, following a motor vehicle accident(MVA). His clinical examination, cervical spine x-rays were unremarkable (Fig 1). CT scan of craniovertebral junction (CVJ) showed comminuted fracture of the left occipital condyle (Fig 2) with bone fragment pushed posteriorly without any spinal cord compression. MRI also confirmed that there was neither any cord compression, nor cord or extra neural structures injury (Fig 3). Patient improved to normal with cervical

spine immobilization using a Philadelphia collar.

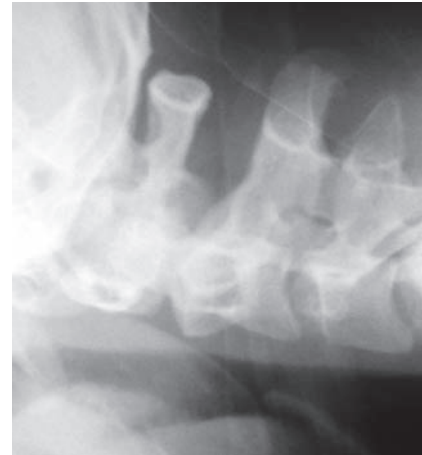

Fig 1: Plain x-ray lateral view of cervical spine showing normal vertebral bodies and soft tissue shadow

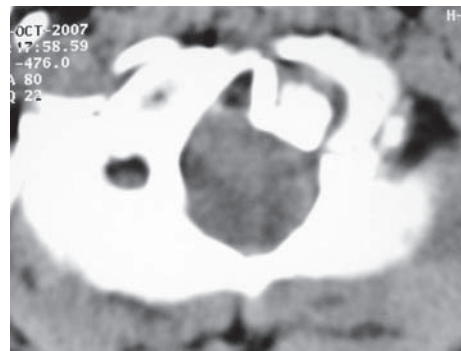


Fig 2 : Axial cuts of non contrast CT of craniovertebral Junction showing retro-pulsed fractured segment without compression of cervical spinal cord.

Address for Correspondence:

Dr. Manoj K Tewari
Senior specialist Neurosurgeon
Sohar Hospital, Sohar, Sultanate of Oman
Post Box 314, Postal Code 321
e-mail: manojktewari@hotmail.com

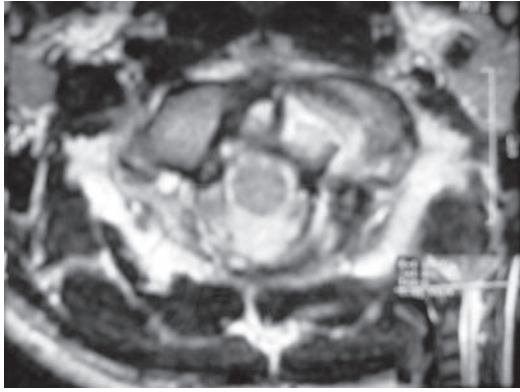


Fig 3: Axial cuts of T1 weighted images of craniovertebral junctions showing normal ligaments without any sign of cord compression.

DISCUSSION

Estimation of the true incidence of OCF is difficult as it is masked by death or concomitant injuries or may be delayed in manifestation. Reported incidence of OCF is 2% on postmortem, 0.1-0.2% amongst severe injuries^{4,5}, 1-16% after CT scans of CVJ region^{6,7,8,9}. This is the only case detected by us after evaluating 900 cases of cranio-cervical trauma. While, young males (20-40 years) are commonly affected, no age or sex is exempt¹. MVA (58-70%), high velocity falls likeskiing accidents (16%), and assaults (8%) are the main causes¹. OCFs can be unilateral (77%) or bilateral (23 %)⁸. Common presentations are loss of consciousness (67%) and lower cranial nerve deficit (LCND) (11-53%). Rarely, these patients present with neck pain and restricted head movements¹⁰. About 53% children present with either neck pain or high cord injury¹¹. LOC always has instantaneous presentation. LCND could be instantaneous (62%) or delayed (38%), solitary or in combination^{1,7,10}. Delayed presentation of LCND is attributed to osseous or fibrous tissue proliferation as a reparative process or possibly secondary to inadequate stabilization of bony fragments¹². Most severe neurological deficits are related to severity of head injury rather than OCF itself. Brainstem and vascular lesions are clinically rare as they are generally fatal. 20% of OCFs have associated cervical spine injury (other than C1 condyle) and thoracic spine injury in 37% cases¹. Associated cervical spine injury (other than C1 condyle) is seen in 20% and thoracic spine injury in 37% cases¹.

Many authors have classified OCFs^{1,5,13,14}. Anderson and Montesano's classification is the most commonly used. It is based on morphology and mechanism of injury

and classifies OCF into three types. Type 1 and 2 are stable fractures resulting from axial compression and type 3 (the most common type) is potentially an unstable fracture. Type 1 is an impacted and undisplaced fracture. Type 2 is linear fracture occurring as a part of basal cranial fracture. Type 3- is usually an infero-medial avulsion fracture resulting in stress and instability of contra lateral alar ligament and tectorial membrane because of lateral bending and rotational injury⁵. Tuli et al's classification¹ considers stability of CVJ region and divides OCF into two groups- stable (Type 1- an undisplaced fracture, and 2A- a displaced fracture) and unstable (type 2B). Hanson et al proposed a modification to Anderson and Montesano's fracture type 3 by dividing it into two subtypes- stable and unstable⁵.

High index of suspicion is required to detect OCF. Cervical spine x-rays, though, inconclusive in 96-98% cases^{1,7}, still it need to be scrutinized carefully for any associated abnormal prevertebral tissue swelling between C1- C3^{12,15}.

Tuli et al recommend CT head upto C2 level with thin slices of CVJ region with bone and soft tissue windows even in minor head injury patients presenting with neck pain or restricted head movements to demonstrate fractures, displacements, alar ligament and tectorial membrane injuries¹. Role of CT in direct demonstration ligamentous injury is controversial^{5,7}. MRI is complimentary to CT, and different MR sequences are necessary to demonstrate the degree of biomechanical and ligamentous injury, intrinsic spinal cord, brain stem injury and for evaluating integrity of transverse atlantal ligaments⁹. Clinical condition of the patient, degree of severity of head injury decides the management and outcome of OCFs⁸. OCFs without neurological deficits have excellent outcome. Results are not so good with neurological deficits [6]. Stable fractures are best treated conservatively and unstable by surgical decompression and fixation⁸. 79% of unilateral OCFs need conservative and only 12% of bilateral OFC require occipito-cervical fusion or Halo vest. There is consensus that conservative therapy is sufficient even in brain stem compression, although few cases having neurological deficit with compression of vertebral artery and/or brainstem compression, without any instability have been operated^{8,16}. Thus a Tuli type 2A OCF requires only hard collar, Tuli type 2 and Anderson and Montesano type 3 need halo brace, others need no immobilization.

CONCLUSION

In patients with severe high cervical pain and restricted head movements OCF should be suspected and patient should be evaluated further.

REFERENCES

1. Tuli S, Tator CH, Fehlings MG, Mackay M. Occipital condyle fractures. *Neurosurgery* 1997; 41: 368-77.
2. Diaz JJ, Gilman C, Morris JS, May AK, Corrillo YM, Guy J. Are five plain films of the cervical spine unreliable? A prospective evaluation in trauma patients with altered mental status. *J Trauma* 2003; 658-664.
3. Mowafi HO, Hickey KS. Occipital condylar fractures in a victim of motor vehicle collision. *J Emer Med* 2006; 31: 259-62.
4. Bucholz RW, Burkhead WZ. The pathological anatomy of fatal atlanto-occipital dislocations. *J Bone Joint Surg(Am)* 1979; 61:248-50.
5. Hanson JA, Diliganis AV, Baxter AB, et al. Radiologic spectrum of occipital condylar fractures: retrospective review of 107 consecutive fractures in 95 patients. *Am J Roentgen* 2002; 178:1261-8.
6. Blacksia MF, Lee HJ. Frequency and significance of fractures of the upper cervical spine detected by CT in patients with severe neck trauma. *Am J Roentgen* 1995; 165:1201-4.
7. Bloom AI, Neeman Z, Slasky BS, et al. Fracture of the occipital condyles and associated craniocervical ligament injury: incidence, CT imaging and implications. *Clin Radiol* 1997; 52:198-202.
8. Leone A, Cerase A, Colosimo C, Lauro L, Puca A, Marano P. Occipital condylar fractures: a review. *Radiology* 2000; 216: 635-44.
9. Noble ER, Smoker WRK. The forgotten condyle: the appearance, morphology, and classification of occipital condyle fractures. *AJNR* 1996; 17:507-13.
10. Stroobants J, Fidlers L, Storms JL, Klaes R, Dua G, Van Hoye M. High cervical pain and impairment of skull mobility as the only symptoms of an occipital condyle fracture: case report. *J Neurosurg* 1994; 81:137-8.
11. Momjian S, Dehdashti AR, Kehrli P, May D, Rillet D. Occipital condylar fractures in children. Case Report. *Ped Neurosurg* 2003; 38:265-70.
12. Acelik I, Manik KS, Sian PS, Khoshneviszadeh SE. Occipital condylar fractures. Review of literature and report of a case. *J Bone Joint Surg [Br]* 2006; 88-B: 665-9.
13. Anderson PA, Montesano PX. Morphology and treatment of occipital condyle fractures. *Spine* 1988; 13:731-736.
14. Saternus KS. Forms of fractures of the occipital condyles [in German]. *Z Rechtsmed* 1987; 99:95-108.
15. Freeman BJ, Behensky JH. Bilateral occipital condyle fracture leading to retropharyngeal hematoma and acute respiratory distress. *Injury* 2005; 36: 207-12.
16. Young WF, Rosenwasser RH, Getch C, Jallo J. Diagnosis and management of occipital condyle fractures. *Neurosurgery* 1994; 34:257-61.
17. Caroli E, Rocchi G, Orlando ER, Delfini FR. Occipital condylar fractures. Report of five cases and literature review. *Eur Spine J* 2005; 14: 487-492.
18. Kapapa T, Tschan CA, Konig K, et al. Fracture of occipital condyle caused by minor trauma in a child. *J Ped Surg* 2006; 41:1774-1746.