

Teeth in the brain: An unusual presentation of penetrating head injury

Deepak Kumar Singh MS, Vishnu Gupta MS, Sanjeev Chopra M Ch, Pankaj Gupta M Ch, H Bagaria M Ch
Department of Neurosurgery
S.M.S. Medical College, Jaipur-302004, Rajasthan

Abstract: Penetrating injuries other than gunshot wounds or low-velocity wounds to the head are extremely rare. We report the case of a 19 year old male who sustained a penetrating craniocerebral trauma following a road traffic accident. Mechanism of injury seems to share characteristics of low velocity projectiles. We discuss the management of this unusual case reviewing the current literature on craniocerebral injuries caused by similar objects.

Keywords: penetrating head injury; intracranial foreign bodies; teeth

INTRODUCTION

Penetrating cerebral injuries caused by foreign bodies are rare occurrences and still rarer are cases involving multiple foreign bodies after vehicular accidents. There are various reports of multiple foreign bodies like pellets and nails due to blast or gunshot injuries. We are presenting a very unusual case of penetrating head injury in which teeth were embedded in cerebral parenchyma

CASE REPORT

A 19 years old male presented as a case of head injury after motorcycle accident. On taking history it was found that patient was driving a motorcycle and a head on collision occurred with other motorcycle. Both the drivers were without their helmets. At the time of admission patient was fully conscious and there was no neurological deficit. Local examination revealed a lacerated wound on left frontal region with underlying depressed fracture. A noncontrast CT scan head showed left frontal depressed fracture with three hyperdense globular structures in a row below the fracture fragment (Fig 1). Patient was taken for emergency surgery. Elevation of depressed fragments revealed dural tear with extrusion of brain matter. Dural margins were defined and through dural opening, three hard, solid non-metallic foreign bodies removed; these turned out to be human teeth (Fig 2). Wound was thoroughly irrigated with isotonic saline, followed by water-tight duroplasty utilizing

pericranium. Postoperative course was uneventful and CT-scan showed removal of all foreign bodies. The embedded teeth were found to be of the person who collided with the patient. Patient was discharged seventh postoperative day on anticonvulsants without any neurological sequelae.

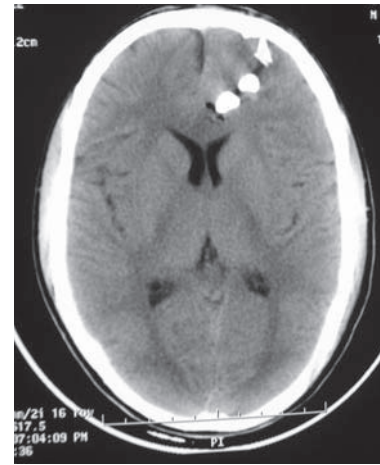


Fig 1: Preop. CT Head showing three globular hyper dense objects in left frontal region

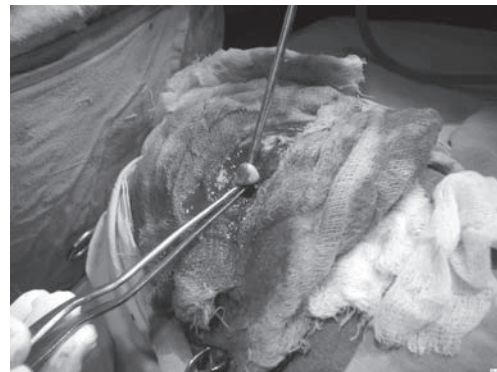


Fig 2: Per operative photograph showing removal of foreign bodies.

Address for correspondence:

Dr. Deepak Kumar Singh
Deptt. Of Neurosurgery
S.M.S. Medical College, Jaipur-302004
Rajasthan
Mobile no. – 091-09352536809, Email: gkp.deepak@gmail.com

DISCUSSION

Penetrating injuries of the brain are very common in warfare injuries but are rarer in civilian head injuries. Missile injuries account for majority of penetrating wounds of brain¹ though brain has been penetrated by almost every conceivable object. There are reports in literature ranging from knife², blades, spoons and even nails³. The major determinant of injury is behavior of penetrating object within the tissue which in turn depends on deformation, yaw (rotation about the long axis) and fragmentation of the projectile. In previous studies, emphasis was given on velocity of penetrating object, differentiating wounds into "low velocity" and "high velocity".

However, velocity is not an independent primary determinant of wounding potential⁴. Three most common types of low velocity penetrating head injuries are seen in industrial accidents, suicidal attempts and as a result of criminal assault⁵. In our case high impact head on collision of the patients head with the other biker resulted in penetration of offenders teeth into patient's brain parenchyma.

Possibility of contamination by oropharyngeal flora necessitates prompt and meticulous management of these cases. Immediate radiological examination is mandatory because small entrance wound does not correspond with the size of foreign body and associated intracranial injury. X-ray skull is useful to delineate the depth and direction of penetration⁶. CT scan head is mandatory in all cases to know the extent of intracranial injuries and is essential in decision-making regarding surgical intervention⁷. However CT scan may need a change of window levels to decrease the metal artifacts. Transcranial wounds should be explored surgically and penetrating foreign body should be removed. In our case the teeth were gently removed along with the depressed wound segments. One has to be very careful not to produce further damage to

the underlying brain by movement of the foreign body and surrounding bone⁵.

These injuries vary in severity from trivial to life threatening but the usual complications are infection and vascular. Penetrating wounds passing through paranasal sinuses or oropharyngeal mucosa before entering cranium have increased chances of wound infection.

The survey of management pattern of these injuries showed a general agreement about CT scan, antibiotics and anticonvulsants⁸. Prompt management resulted in an excellent outcome.

REFERENCES

1. Kaufman HH. Treatment of civilian gunshot wounds to the head. *Neurosurg Clin N Am* 1991; 2:387-397.
2. Davis NL, Kahana T, Hiss J. Souvenir knife: a retained transcranial knife blade. *Am J Forensic Med Pathol* 2004; 25:259-61.
3. Salar G, Costella GB, Mottaran R, Mattana M, Gazzola L, Munari M. Multiple craniocerebral injuries from penetrating nails. *J Neurosurg* 2004; 100:963.
4. Fackler ML. Wound ballistics. A review of common misconceptions. *JAMA* 1988; 259:2730-6.
5. Bakay L, Glausier FE, Grand W. Unusual intracranial foreign bodies. Report of five cases. *Acta Neurochir(Wien)* 1977;39:219-31.
6. Herring CJ, Lumsden AB, Tindall C. Transcranial stab wounds. A report of three cases and suggestions for management. *Neurosurgery* 1988; 23:658-62.
7. Nakayama Y, Tanaka A, Arita T, Kumate S, Yoshinga S. Penetrating head injury caused by weed: Case report. *Brain & Nerve* 1995; 47:1192-94.
8. Kaufman HH, Schwab K., Salazar AM. A national survey of neurosurgical care for penetrating head injury. *Surg Neurol* 1991; 36: 370-7.