

Traumatic ipsilateral acute extradural and subdural hematoma

Rahul Gupta M Ch, Sandeep Mohindra M Ch, FRCS Ed*, Saurabh Kumar Verma M S*

Departments of Neurosurgery, GB Pant Hospital, New Delhi & *Postgraduate Institute of Medical Education and Research, Chandigarh

Abstract: We report a unique case of brain trauma, harboring acute extradural haematoma and subdural haematoma on the same side.

Keywords: extradural hematoma, head injury, ipsilateral, subdural hematoma

INTRODUCTION

Occurrence of simultaneous extradural hematoma (EDH) and acute subdural hematoma (SDH) after single trauma and on the same side is a rare occurrence. Also, it is the SDH that determines the severity of injury and outcome, due to its associated underlying brain injury. In the present communication, we present a unique case of simultaneous occurrence of EDH and SDH, on the same side in a comatose patient, with EDH determining the outcome.

CASE REPORT

A 35-year-old male presented 4 hours after road traffic accident with severe head injury in a decerebrating state. CT scan of head showed two left-sided frontal and parieto-temporal extraparenchymal hematomas with a significant midline shift (Fig 1). Immediate surgery was under-taken and left-sided fronto-parieto-temporal craniotomy was performed. A large extradural hematoma, at parieto-temporal region was evacuated, leaving a lax dura. We did not encounter two separately loculated blood clots, as visible on the CT scan. As the dura was lax and pulsatile, bone-flap was replaced and wound closed. Check CT scan, after 2 hours of surgery, showed complete evacuation of EDH, but 1 cm thick SDH was noted on the same side (Fig 2). Though the mass effect and midline shift disappeared, an ipsilateral PCA infarct had already developed. A subsequent CT scan, 3 days after surgery showed complete disappearance of SDH (Fig 3). The patient was discharged in vegetative state (E3VTM4).

Address for correspondence:

Rahul Gupta M Ch,
Assistant Professor, Department of Neurosurgery,
G B Pant Hospital, JLN Marg, New Delhi 110002
Phone : 9971700389; e-mail : rahulguptaneuro@gmail.com

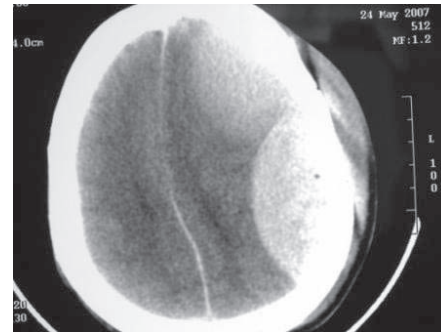


Fig 1: Pre-operative CT scan of head showing two biconvex hyperdense, extra-parenchymal lesions, suggestive of EDH.

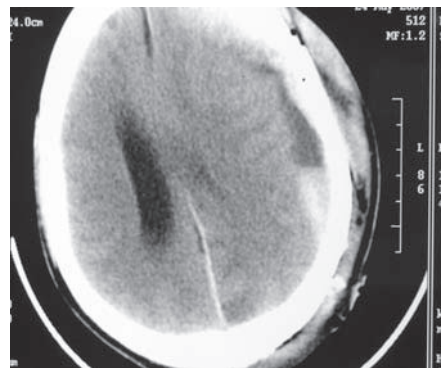


Fig 2: Immediate post-operative CT scan showing evacuation of EDH and redistribution of subdural blood, with blood-CSF level.

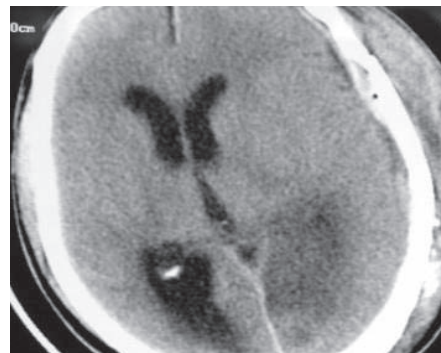


Fig 3: CT scan, 3 days after surgery showing complete resolution of SDH and presence of ipsilateral PCA infarct.

DISCUSSION

Surgical evacuation of the traumatic EDH is one of the most 'cost effective' of all surgical procedures in terms of quality of life and years preserved¹. In spite of advances in modern head trauma management, patients with acute SDH have worse prognosis than any other type of head trauma, with mortality rates reaching as high as 60%².

The mechanism of formation of traumatic EDH and SDH are entirely different. EDH, primarily located in the temporal or temporo-parietal region is due to tear of anterior or posterior divisions of the middle meningeal arteries with an associated linear vault fracture. The skull deformation probably initiates the process of dural stripping. In cases of acute SDH, it is the bleeding from contused, lacerated brain cortex, torn bridging veins, or a torn cortical blood vessel, which leads to subdural hematoma accumulation. Approximately, half of SDH patients have associated traumatic brain lesions including contusions, hematomas or cortical lacerations. It is well established that the primary underlying brain injury dictates the final outcome in SDH patients².

In the present case, the presentation CT scan showed two ipsilateral biconvex extra-parenchymal hematomas suggestive of EDH, indicating incomplete dural stripping at the middle. Intra-operatively, only the parietal clot was appreciated and evacuated. Since there was no discoloration of the dura, and was pulsating, it was not opened. The postoperative CT scan showed complete evacuation of EDH and a hematoma underneath the dura. We propose that there occurred redistribution of the pre-operative SDH after mixing with the CSF³. In

retrospect, careful reading of CT scan (Fig 1) shows well-delineated margins of parietal clot, as compared to hazy outline of frontal region clot, suggesting the presence of both SDH and EDH. Significant reduction of the mass effect and midline shift suggest a negligible role of the notoriety of SDH as compared to EDH. Moreover, the herniation, leading to the PCA territory infarct, in consequence to EDH led on to the vegetative outcome of the index case. Further, the spontaneous resolution of SDH was catalyzed by CSF outflow after subarachnoid breach, indicating minimal primary brain injury³.

CONCLUSION

This is a unique case of head injury where both EDH and SDH occurred simultaneously and the extradural lesion determined the final outcome. The SDH remained a silent bystander and gradually disappeared harmlessly. Further, even in poor grade trauma patient, spontaneous resolution of SDH may occur.

REFERENCES

1. Pickard JD, Bailey S, Sanderson H, Rees M, Garfield JS. Steps towards cost-benefit analysis of regional neurosurgical care. *BMJ* 1990 ; 301 : 629-35.
2. Massaro F, Lanotte M, Faccani G, Triolo C. One hundred and twenty-seven cases of acute subdural haematoma operated on. Correlation between CT scan findings and outcome. *Acta Neurochir (Wien)* 1996 ; 138 : 185-91.
3. Kapsalaki EZ, Machinis TG, Robinson JS 3rd, Newman B, Grigorian AA, Fountas KN. Spontaneous resolution of acute cranial subdural hematomas. *Clin Neurol Neurosurg* 2007 ; 109 : 287-91.